



# Biokemistri

An International Journal of the Nigerian Society for Experimental Biology

## Short Communication

# Histomorphometric study of thyroid gland of female Wistar rats exposed to alcohol during pregnancy and/or lactation

Josephat E. Onu<sup>\*1</sup>, Bankole O. Oke<sup>2</sup>, Peter C. Ozegbe<sup>2</sup> and Johnson O. Oyewale<sup>3</sup>

<sup>\*1</sup>Department of Veterinary Anatomy, Usmanu Danfodiyo University, Sokoto, <sup>2</sup>Department of Veterinary Anatomy and <sup>3</sup>Physiology, Pharmacology and Biochemistry, University of Ibadan, Nigeria

\*Corresponding Author: Josephat Onu. E-mail: josephatedoga@yahoo.co.uk; Tel.: +2348035073118

Received: 10 May 2013; Revised: 10 August 2013; Accepted: 03 September 2013

**ABSTRACT:** The effect of alcohol on the histomorphology of thyroid gland of female rat offspring exposed to alcohol during pregnancy and/or lactation was studied. Previously published protocols for similar studies were followed. Data from both absolute and relative weights, coupled with histologic data from the thyroid glands of the alcohol-exposed rats suggest that alcohol consumption during pregnancy and/or lactation could be injurious to the thyroid glands of the female offspring.

**KEYWORDS:** Alcohol, pregnancy, lactation, thyroid glands, Wistar rats

BKM.2013.010 © 2013 Nigerian Society for Experimental Biology; All rights reserved. Printed in Nigeria  
This article is downloadable online in PDF format at <http://www.bioline.org.br/bk>

## INTRODUCTION

Inappropriate consumption of alcohol by women while pregnant leads to a condition called Foetal Alcohol Syndrome (FAS) in the offspring (Scraag, 1995). Since the recognition of FAS, numerous animal studies have demonstrated the deleterious effects of alcohol administration during pregnancy and gestation on the offspring (Onu *et al.* 2010, 2011a & b). The effects of alcohol consumed during pregnancy on some parts of the body of neonates in both humans and experimental animals have been reported (Assadi, 2008, Onu *et al.* 2011a & b). However, there is paucity of data in the literature on the effects of alcohol consumed during pregnancy and/or lactation on the histomorphometry of thyroid gland in the female offspring, hence this study.

## METHODOLOGY

The protocols for animal handling, experimental design, sample collection and data analyses previously published by Onu *et al.* 2010, 2011a & b, and 2012 were followed for this study, the only difference being that this study was conducted in the female offspring.

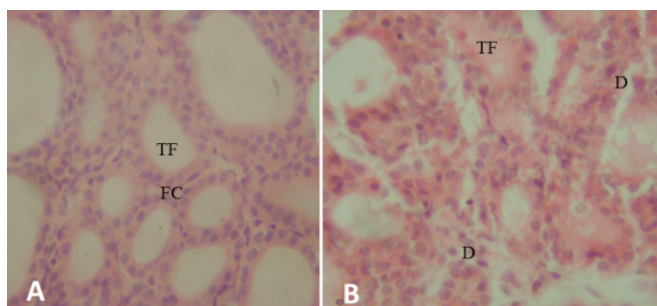
## RESULTS AND DISCUSSION

Table 1 shows that alcohol significantly decreased ( $p < 0.05$ ) the weights of thyroid gland in rats exposed to alcohol during pregnancy and lactation (APL group) at D35 and 49 and in those exposed to alcohol only during lactation (AL group) at D35 relative to the control. It also shows a significant reduction ( $p < 0.05$ ) in the diameter of thyroid follicles in APL at D35 and 49 and a significant decrease ( $p < 0.05$ ) in AL at D35 relative to the control. There was an observed disruption of thyroid follicular cells of APL and AL as shown in Figure 1.

**Table 1: Comparison of the weights and diameters of thyroid glands of female rat offspring whose dams were exposed to alcohol during pregnancy and/or lactation**

Weights [Absolute weight (mg) (Relative weight $\times$ 1000)]			
Age (days)	Control (n = 5)	APL (n = 5)	AL (n = 5)
35	3.00 $\pm$ 0.22 <sup>a</sup> (6.00 $\pm$ 0.20 <sup>a</sup> )	1.20 $\pm$ 0.12 <sup>c</sup> (3.00 $\pm$ 0.20 <sup>c</sup> )	2.28 $\pm$ 0.09 <sup>b</sup> (5.00 $\pm$ 0.30 <sup>b</sup> )
49	4.80 $\pm$ 0.25 <sup>a</sup> (6.00 $\pm$ 0.20 <sup>a</sup> )	1.42 $\pm$ 0.22 <sup>b</sup> (2.00 $\pm$ 0.20 <sup>b</sup> )	4.40 $\pm$ 0.43 <sup>a</sup> (5.00 $\pm$ 0.10 <sup>a</sup> )
Follicular diameter ( $\mu$ m)			
35	52.48 $\pm$ 0.20 <sup>a</sup>	30.36 $\pm$ 0.30 <sup>c</sup>	34.32 $\pm$ 0.20 <sup>b</sup>
49	55.08 $\pm$ 0.30 <sup>a</sup>	31.10 $\pm$ 0.20 <sup>b</sup>	54.16 $\pm$ 0.10 <sup>a</sup>

Values in the same row with different superscripts are significantly different at  $p < 0.05$ ; APL = Alcohol-exposed rats from pregnancy to lactation, AL = Alcohol-exposed rats during lactation only; n = number of animals



**Figure 1: Photomicrograph of thyroid gland of female rat offspring at D49.** Panel A is the Control showing normal thyroid follicle (TF) and follicular cells (FC) lining the basement membrane while Panel B shows the Thyroid gland of APL and AL showing disruption of follicular cells (D). Mg x400, Stain: H&E

The decreased absolute and relative weights and follicular diameter of the thyroid gland of the female Wistar rat offspring whose dams were exposed to alcohol from pregnancy and/or lactation obtained in this investigation is similar to the observation of Onu *et al.* (2011a) in neonatal male rats. The reduced thyroid weight shown by the female offspring whose dams were exposed to alcohol from pregnancy to lactation is similar to the observation of Nwaogu and Ihemelandu (1999) in rats. The mechanism underlying this observation is not known for certain. The probability of interference of alcohol in the synthesis and/or secretion of thyroid hormone by the thyroid follicular cells is supported by the histomorphometric effect as observed by Onu *et al.* (2012) in dams. The same histomorphometric effect was also observed in this investigation supporting the toxic effect of alcohol. Alcohol is a neurotoxin capable of disrupting the release of thyrotropin-releasing hormone (TRH) and the subsequent thyroid stimulating hormone (TSH). TSH promotes cell growth in the thyroid gland and it has been reported to be absent in new-borns exposed to alcohol *in utero* (Hernandez *et al.* 1992). The decreased weights of the thyroid gland may therefore be due to inadequate stimulation of the thyroid gland as a result of maternal exposure to alcohol.

## ACKNOWLEDGEMENTS

The authors are thankful to the Committee of Deans of Usmanu Danfodiyo University for sponsoring this research work.

## REFERENCES

Assadi F (2008) Effects of Prenatal Alcohol Exposure on the Developing Kidneys. *Iranian Journal of Pediatrics* 18: 5–10.

Hernandez JT, Hoffman L, Weavil S, Cvejic S and Prange AJ Jr. (1992) The effect of drug exposure on thyroid hormone of newborns. *Biochemical Medicine and Metabolic Biology* 48: 255–262.

Nwaogu IC and Ihemelandu EC (1999) Effects of maternal alcohol consumption on the allometric growth of muscles in foetal and neonatal rats. *Cells Tissues Organs* 164: 167–173.

Onu JE, Ezeasor DN and Ihemelandu EC (2010) Effect of maternal alcohol consumption on epididymal growth in neonatal mice. *Nigerian Veterinary Journal* 31: 279–282.

Onu JE, Oke, BO, Ozegbe PC and Oyewale JO (2011a) Effects of alcohol consumption during pregnancy and/or lactation on the morphology of thyroid gland in male Wistar rat offspring. *Pakistan Veterinary Journal* 31: 357–359.

Onu JE, Oke, BO, Ozegbe PC, Oyewale JO and Azeez OI (2011b) Effects of alcohol consumption during pregnancy and/or lactation on blood parameters in young male Wistar rat offspring. *Nigerian Journal of Experimental and Applied Biology*. 31: 357–359.

Onu JE, Oke, BO, Ozegbe PC and Oyewale JO (2012) Morphometric studies of thyroid gland of Wistar rats exposed to alcohol during pregnancy and/or lactation. *International Journal of Biological and Chemical Sciences* 6: 2293–2298.

Sraag R (1995) A quantification of alcohol-related mortality in New Zealand. *Australian and New Zealand Journal of Medicine* 25: 5–11.