

Comparison of uroprotective efficacy of mesna and amifostine in Cyclophosphamide- induced hemorrhagic cystitis in rats

Kanat O, Kurt E, Yalcinkaya U, Evrensel T, Manavoglu O

Uludag University, Faculty of Medicine, Department of Medical Oncology, Gorukle 16059, Bursa, Turkey

Correspondence to: Ozkan Kanat, E-mail: ozkanat@uludag.edu.tr

Abstract

BACKGROUND: Hemorrhagic cystitis (HC) is a dose limiting side effect of cyclophosphamide (CYP). **AIM:** In this study, we aimed to investigate the role of amifostine in the protection of CYP-induced HC and compare its efficacy with mesna. **SETTING AND DESIGN:** This animal study was conducted in the Experimental Animals Breeding and Research Center of the Medical Faculty of Uludag University. **MATERIALS AND METHODS:** Male Wistar rats (150-200 g; 10 rats per group) were randomly assigned to four groups. Group I (control group) received no drugs, group II received CYP (200 mg/kg, i.p.) alone, group III received amifostine (200 mg/kg, i.p.) and CYP, and group IV received CYP and mesna (40 mg/kg, i.p.) immediately and 4 and 8 h after administration of CYP. Bladders of animals were assessed macroscopically and histologically 24 h later. Gross assessment for presence of edema and hemorrhage and histological evaluation of damage to the bladder were scored according to Gray's criteria. **STATISTICAL ANALYSIS USED:** For macroscopic and microscopic data, we used statistical evaluation by Kruskal-Wallis nonparametric analysis of variance followed by the Mann-Whitney U-test. **RESULTS:** All the animals in group II had evidence of HC. Significant histological damage and macroscopic changes were present in this group compared to control group ($P<0.001$). The median scores for bladder damage in group III and IV were significantly lower compared to group II ($P<0.001$). When the median scores for bladder damage of group I, III, and IV were compared, there was no significant difference among these groups. **CONCLUSION:** This study demonstrated the efficacy of amifostine in prevention of cyclophosphamide-induced hemorrhagic cystitis.

Key Words: Amifostine, cyclophosphamide, hemorrhagic cystitis, mesna

Cyclophosphamide (CYP) is an alkylating chemotherapeutic agent that is used in a variety of malignant conditions including lymphomas, ovarian and breast cancer. Hemorrhagic cystitis (HC) is a well known and a potentially life-threatening adverse effect of this drug. The incidence of HC is related to the dosage and may be as high as 75% in patients receiving a high intravenous dose.^[1]

CYP is a pro-drug that is transformed into the active metabolites phosphoramidate mustard and acrolein by the P-450 enzymes in the liver. Acrolein has been proven to

be a potent urothelial irritant and is currently accepted as the major cause of CYP-induced HC. It has been proposed that urothelial damage occurs by direct contact with acrolein, which causes edema, ulceration, neovascularization, hemorrhage, and necrosis.^[2]

Adequate hydration and the concurrent administration of sodium-2-mercaptoethane (mesna) are the most widely employed methods for prevention of CYP-induced HC in clinical practice. However, HC still occurs in 10-40% of mesna-treated patients.^[3] Therefore, there is a need for new effective agents for prevention

of this side effect.

Amifostine is a broad-spectrum cytoprotective agent with wide potential for use in cancer therapy.^[4-6] It is a prodrug that is dephosphorylated by the plasma membrane-bound enzyme alkaline phosphatase to its active metabolite, the free thiol WR-1065. WR-1065 is rapidly taken up into cells and is the major cytoprotective metabolite. WR-1065 exerts its protective action by scavenging free radicals, by donating hydrogen ions and depleting oxygen, and by neutralizing DNA-reactive moieties of antineoplastic drugs.^[4,5] In preclinical and clinical studies, amifostine showed selective protection of normal tissues against chemotherapy-induced toxicities without influencing the antitumor activity of cytotoxic therapy.

The cytoprotective potential of amifostine has been established for various tissues including hematopoietic progenitor cells, renal cells, myocardium, intestinal epithelium and neuronal cells.^[4] Amifostine can offer a chance of protecting urothelium from toxicity of CYP. Srivastava *et al*^[7] evaluated the role of amifostine in the prevention of CYP-induced HC in the rat model and demonstrated that amifostine protects the urothelium against CYP. However, they did not compare its efficacy with mesna in their study. Thus, in this study, we aimed to investigate efficacy of amifostine in the prevention of CYP-induced HC and compare its efficacy with mesna.

Materials and Methods

A total of 40 male Wistar rats, weighing 150-200 g, were allowed free access to food and water and were randomly assigned to one of the four groups of 10 rats each: Group I: controls; group II: received 200 mg/kg of CYP (Endoxan, IE. Ulagay, Istanbul, Turkey) alone by intraperitoneal (i.p.) injection; group III: received 200 mg/kg of amifostine (Ethyol, Er-Kim, Istanbul, Turkey) i.p., 15 min prior to CYP as above; group IV: received 40 mg/kg mesna (Uromitexan, IE. Ulagay, Istanbul, Turkey) i.p., at the same time and 4 and 8 h after CYP administration. Control animals received sterile saline 0.9% i.p. CYP, mesna and amifostine were dissolved in 0.9% sterile saline.

The experimental protocol was in accordance with the guidelines approved by the Declaration of Helsinki for use of animal experiments. All procedures involving animals were approved by our institution's animal-care committee.

Induction of HC

CYP (200 mg/kg) was injected i.p. to consistently induce HC, as previously described.^[8]

Administration of amifostine

Amifostine (200 mg/kg) was administered i.p., 15 min prior to the administration of CYP. This dose was selected on the basis of previous studies on cytoprotection in rats.^[7]

Administration of mesna

Mesna was administered according to classical protocol (% 20 of CYP whole dose at the time of chemotherapy initiation, followed by repeat equivalent doses of mesna every 4 h thereafter, for a total of three doses).

The animals were sacrificed by cervical dislocation 24 h after the administration of CYP. Their bladders were removed by careful dissection and fixed 10% formalin. Data from the literature using CYP-induced HC has shown that the best time to access HC in rats is between 24 and 48 h.^[9] Therefore, we chose to access CYP-induced HC at 24 h in this study.

Macroscopic evaluation

Bladders were examined grossly for edema and hemorrhage according to Gray's criteria.^[10] Edema was considered severe (3+) when fluid was seen externally and internally in the bladder walls; moderate (2+) when confined to the internal mucosa; mild (1+) between normal to moderate; and absent (0). Hemorrhage was scored as follows: (3+) intravesical clots; (2+) mucosal hematomas; (1+) telangiectasia or dilatation of the bladder vessels; and (0) normal.

Histopathological evaluation

Bladders were fixed in formalin, embedded in paraffin, and processed for hematoxylin and eosin staining. Histopathological changes were scored as follows: (0), normal epithelium and absence of inflammatory cell infiltration and ulceration; (1+), mild changes involving reduction of epithelial cells, flattening with submucosal edema, mild hemorrhage, and few ulcerations; (2+), severe changes including mucosal erosion, inflammatory cell infiltration, fibrin deposition, hemorrhage, and multiple ulcerations.

The results are expressed as the median (min-max), and $P < 0.05$ was assessed as statistically significant. All of the numeric data were analyzed first using nonparametric Kruskal-Wallis test to find whether there is difference between groups, and then Mann-Whitney U-test was performed to analyze two groups consecutively.

Results

Control animals had grossly and histopathologically normal bladders with assigned scores of '0' for the three

parameters of edema, hemorrhage and histopathological changes. All the animals receiving CYP (group II) had evidence of HC [Figure 1]. It was characterized macroscopically by the presence of moderate to severe edema, receiving a score of 2.5 (2-3); and marked hemorrhage with mucosal hematomas and intravesical clots, receiving a score of 2 (2-3); that was significantly ($P<0.001$) different from the control group which received a score of 0 (0-0) for edema and hemorrhage. Significant histological changes, including extensive mucosal erosion with multiple ulcerations, inflammatory cell infiltration, and fibrin deposition, receiving a score of 2 (1-2) were also present in this group compared with control group, which received a score of 0 (0-0) ($P<0.001$). These alterations were almost abolished ($P<0.001$) by the amifostine (group III) or mesna (group IV) in CYP-treated animals. In group III, only two bladders showed minimal edema [Figure 2].

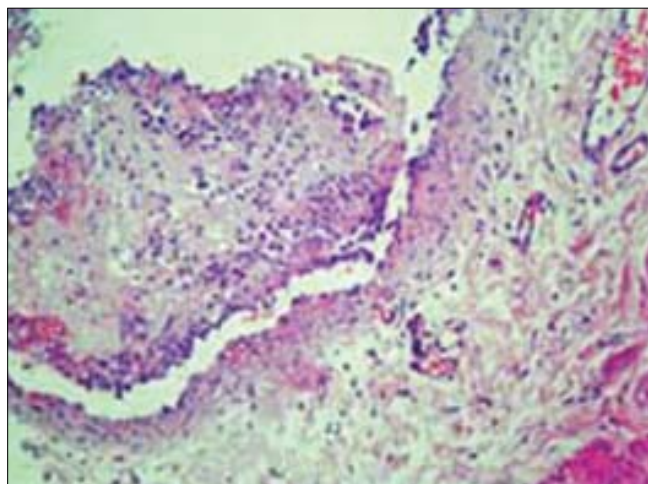


Figure 1: Cystitis in a rat treated 24 h previously with cyclophosphamide (200 mg/kg, i.p.) showing severe ulcerations, edema, leukocyte infiltration, hemorrhage and fibrin deposition; score of 2 (Gray's criteria). (H/E, 200x)

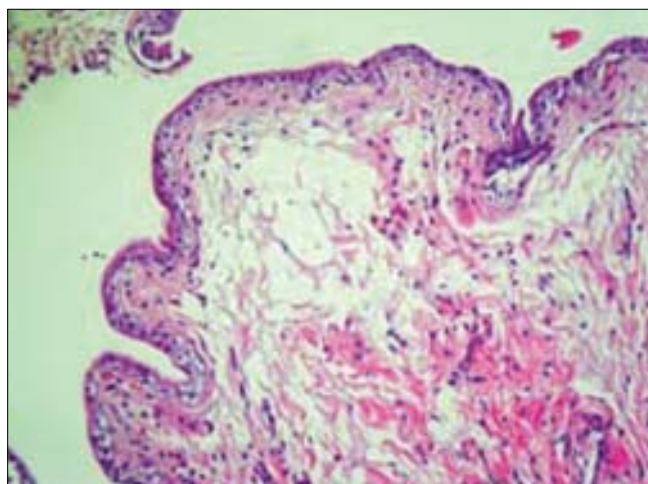


Figure 2: Bladder of a rat treated with cyclophosphamide and amifostine (200 mg/kg). Urothelium preservation and edema; score of 1. (H/E, 200x)

Dilatation of the bladder vessels was noted in four bladders. Only one animal had mild histopathological changes suggestive of HC. In group IV, mild mucosal edema was noted in four, and dilatation of bladder vessels was found in two bladders [Figure 3]. When the scores (median and range) for bladder damage of group I, III and IV were compared; there was no significant difference among these groups ($P>0.05$). The scores of gross assessment for presence of edema and hemorrhage and histopathological evaluation of damage to the bladder are shown in [Table 1].

Discussion

In this study, we investigated the role of amifostine in the prevention of CYP-induced HC and compared its efficacy with mesna. We have confirmed that amifostine could be a useful agent in the preventive management of CYP-induced HC. We have also demonstrated that amifostine was as effective as mesna in this setting. The major disadvantage of our study is the small sample size. However, we assume that this observation provides recent evidence that could modify the prophylactic approaches to CYP-induced bladder damage.

Apart from preventing HC, there could be other advantages of using amifostine in this situation. The use of CYP is associated with mutagenesis and bladder cancers, particularly in those patients who developed cystitis.^[11,12] It is therefore possible that when used in conjunction with CYP, amifostine may not only provide immediate protection from HC, but also prevent mutagenesis and development of secondary malignancies. Furthermore, some studies demonstrated that amifostine could reduce the severity of CYP-induced myelotoxicity and improve patient tolerability

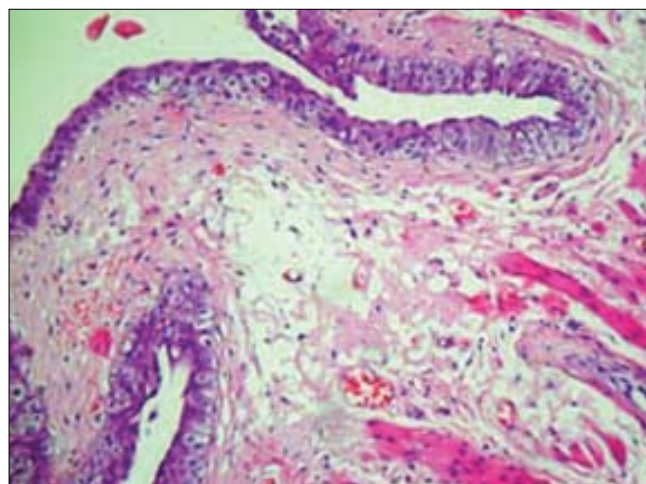


Figure 3: Bladder of a rat treated with three doses of mesna (20% of cyclophosphamide dose, 40 mg/kg, i.p.) and cyclophosphamide. Edema and dilatation of bladder vessels; score of 1. (H/E, 200x)

Table 1: Compared scores for gross evaluation and histologic grading of bladder changes

Group	Treatment	Edema	Hemorrhage	Microscopic analysis
I	Control	0 (0-0)*	0 (0-0)*	0 (0-0)*
II	CYP	2.5 (2-3) [†]	2 (2-3) [†]	2 (1-2) [†]
III	CYP and amifostine	0 (0-1)*	0 (0-1)*	0 (0-1)*
IV	CYP and mesna	0 (0-1)*	0 (0-1)*	0 (0-0)*

CYP, cyclophosphamide. The results are reported as medians and range (n=10 per group). * $P<0.001$ when compared with CYP group; [†] $P<0.001$ when compared with control group

to the therapy.^[13]

Amifostine was used at a dose of 200 mg/kg in our study. This dose is equivalent to about 1300 mg/m² in rats. If clinical trials are to be initiated, administration dose of amifostine needs to be considered. The ideal dose of amifostine for different clinical situations remains to be defined, but doses of 740 mg/m² or 910 mg/m² have been shown to provide cytoprotection in most studies.

The mechanism of protection by amifostine to HC is a matter of dispute. WR-1065 might provide bladder protection by several mechanisms. WR-1065 can bind directly to acrolein and detoxify it. Therefore, nontoxic thioester does not induce any damage to the urothelium. However, CYP-induced HC is probably not only due to direct contact of acrolein with bladder mucosa. Active oxygen species (AOS) and oxygen free radicals produced by CYP are most likely contribute to occurrence of bladder damage via several mechanisms including peroxidation of membrane lipids, protein denaturation and DNA damage. WR-1065 is a potent scavenger of active oxygen species. This feature of WR-1065 probably mediates the protective effect of amifostine against CYP-induced bladder damage. These hypotheses should be established by further studies focusing on the anti-apoptotic effects of amifostine on urethelium, as previously demonstrated on hematopoietic cells by Mazur *et al*.^[14]

In conclusion, results of this study demonstrate the efficacy of amifostine in the prevention of cyclophosphamide-induced hemorrhagic cystitis. This result is encouraging. However, how this will translate to clinical protection of patients from CYP-induced HC remains to be established.

References

- Korkmaz A, Oter S, Deveci S, Goksoy C, Bilgic H. Prevention of further cyclophosphamide induced hemorrhagic cystitis by hyperbaric oxygen and mesna in guinea pigs. *J Urol* 2001;166:1119-23.
- Cox PJ. Cyclophosphamide cystitis-identification of acrolein as the causative agent. *Biochem Pharmacol* 1979;28:2045-9.
- Brock N, Pohl J. The development of mesna for regional detoxification. *Cancer Treat Rev* 1983;10:33-43.
- Capizzi RL. The preclinical basis for broad-spectrum selective cytoprotection of normal tissues from cytotoxic therapies by amifostine. *Semin Oncol* 1999;26:3-21.
- Griggs JJ. Reducing the toxicity of anticancer therapy: New strategies. *Leuk Res* 1998;22:27-33.
- Kanat O, Evrensel T, Baran I, Coskun H, Zarifoglu M, Turan OF, *et al*. Protective effect of amifostine against toxicity of paclitaxel and carboplatin in non-small cell lung cancer: A single center randomized study. *Med Oncol* 2003;20:237-45.
- Srivastava A, Nair SC, Srivastava VM, Balamurugan AN, Jeyaseelan L, Chandy M, *et al*. Evaluation of uroprotective efficacy of amifostine against cyclophosphamide induced hemorrhagic cystitis. *Bone Marrow Transplant* 1999;23:463-7.
- Morais MM, Belarmino-Filho JN, Brito GA, Ribeiro RA. Pharmacological and histopathological study of cyclophosphamide-induced hemorrhagic cystitis - comparison of the effects of dexamethasone and Mesna. *Braz J Med Biol Res* 1999;32:1211-5.
- Vieira MM, Brito GA, Belarmino-Filho JN, Macedo FY, Nery EA, Cunha FQ, *et al*. Use of dexamethasone with mesna for the prevention of ifosfamide-induced hemorrhagic cystitis. *Int J Urol* 2003;10:595-602.
- Gray KJ, Engelmann UH, Johnson EH, Fishman IJ. Evaluation of misoprostol cytoprotection of the bladder with cyclophosphamide (Cytoxan) therapy. *J Urol* 1986;136:497-500.
- Johansson SL, Cohen SM. Epidemiology and etiology of bladder cancer. *Semin Surg Oncol* 1998;13:291-8.
- Talar-Williams C, Hijazi YM, Walther MM, Linehan WM, Hallahan CW, Lubensky I, *et al*. Cyclophosphamide-induced cystitis and bladder cancer in patients with Wegener granulomatosis. *Ann Intern Med* 1996;124:437-84.
- Alberts DS. Protection by amifostine of cyclophosphamide-induced myelosuppression. *Semin Oncol* 1999;26:37-40.
- Mazur L, Augustynek A, Deptala A, Halicka HD, Bedner E. Effects of WR-2721 and cyclophosphamide on the cell cycle phase specificity of apoptosis in mouse bone marrow. *Anticancer Drugs* 2002;13:751-8.