

Eczematous lesion on the breast

A 65-year-old woman presented with a pruritic lesion on the left breast of 10 years duration associated with occasional oozing and burning sensation. The patient had only used over the counter medications for recurrent ulcerations over the nipple. She related no history of any other dermatologic or systemic complaints. Cutaneous examination revealed a 10 X 7 cm well-demarcated erythematous mildly scaly plaque

with inconspicuous nipple on the left breast [Fig. 1]. The overlying surface appeared shiny and atrophic. No underlying breast masses were palpable clinically and there was no lymphadenopathy. Biopsy features from the eczematous lesion are shown in [Figs 2-4].

WHAT IS YOUR DIAGNOSIS?

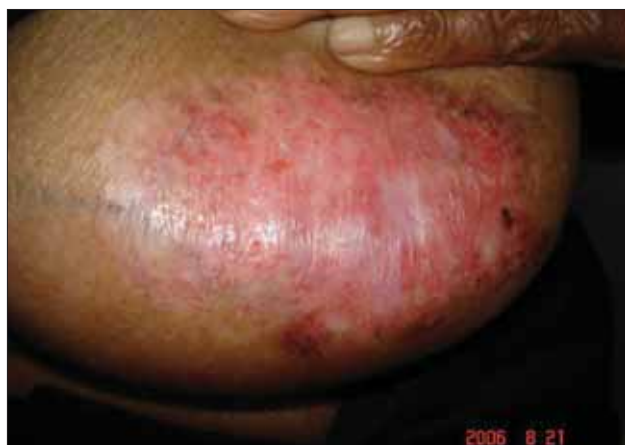

Figure 1: Erythematous scaly plaque with loss of nipple

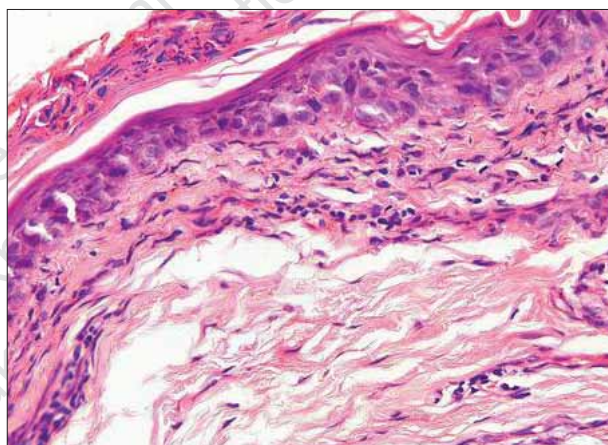


Figure 3: Skin biopsy (H and E, x200)

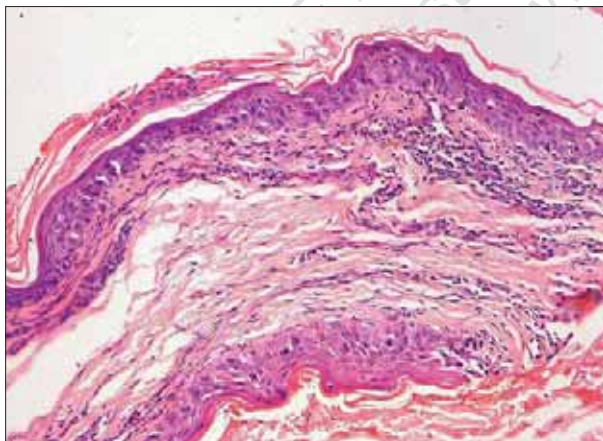


Figure 2: Skin biopsy (H and E, x100)

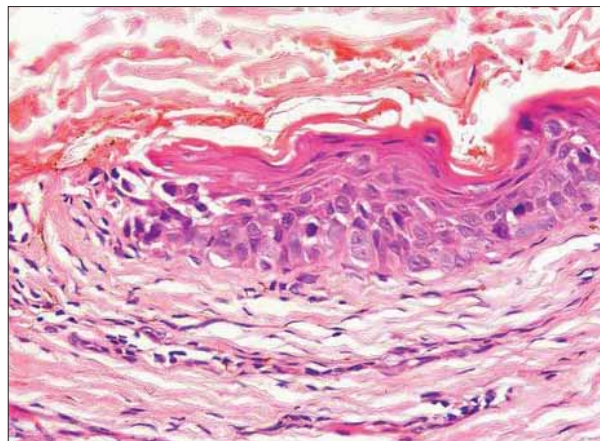


Figure 4: Skin biopsy (H and E, x400)

How to cite this article: Mehta V, Balachandran C, Bansal P, Geeta K. Eczematous lesion on the breast. Indian J Dermatol Venereol Leprol 2007;73:210.

Received: August, 2006. **Accepted:** April, 2007. **Source of Support:** Nil. **Conflict of interest:** None declared.

Diagnosis: Paget's disease of the breast

Histopathology showed hyperkeratotic epidermis with parakeratosis. Large clear cells with abundant pale staining cytoplasm, large vesicular nucleus and prominent nucleoli were seen arranged along the basement membrane with occasional mitotic figures. Dermis showed perivascular infiltrate composed of lymphocytes and plasma cells.

DISCUSSION

Paget's disease (PD) of the breast is a progressive well-margined scaling and crusting of the nipple areola complex that is often associated with an underlying *in situ* or invasive breast carcinoma. It was described first in 1874 by Sir James Paget. However, it was not until 1889 that Darier described the malignant cell of PD. Mammary PD occurs almost exclusively in women in the fifth to sixth decade of life, however, some instances of PD of male breast have been cited in the literature.^[1] Patients with mammary PD present with a relatively long history of an eczematous skin lesion or persistent dermatitis of the nipple and the adjacent area often associated with burning sensation, ulceration, bleeding and oozing with serosanguineous discharge. Objectively, a scaly erythematous crusted plaque on the nipple and areolar skin can be seen. Retraction of the nipple or presence of palpable nodules indicates an underlying breast carcinoma. Unilateral involvement is the rule, however, bilateral mammary PD has been reported.^[2] Occasional cases of PD have been reported in ectopic breast^[3] and in supernumerary nipples.^[4]

The histogenesis of mammary PD continues to be hotly debated.^[5] The epidermotropic theory holds that Paget's cells are ductal carcinoma cells that have migrated from the underlying breast parenchyma to the nipple epidermis. The malignant cells infiltrate and proliferate in the epidermis causing thickening of the nipple and areolar skin. The migration and infiltration is induced by a motility factor produced by the normal epidermal keratinocytes.^[6] According to the *in situ* transformation theory Paget's cells arise as malignant cells in the nipple epidermis independent of any other pathologic process within the breast parenchyma. This theory has been proposed to explain those cases in which there is no underlying breast carcinoma or when there is a carcinoma remote from the nipple areolar complex. Fifty per cent of the patients with mammary PD presenting with a palpable breast mass have associated axillary lymph node metastasis. In our patient there were no breast masses or

palpable axillary lymph nodes clinically and the mammogram and ultrasound of the breast did not reveal presence of any tumor, however, the presence of an *in situ* carcinoma cannot be completely ruled out. The prognosis of PD is a reflection of the underlying malignancy and when this is present the prognosis is the poorest. The 10-year survival rates in PD without a palpable mass prior to surgery range from 82-91%.^[7] Contact dermatitis, Bowen's disease and malignant melanoma clinically may resemble PD but each of them have distinctive features on histology with the absence of Paget's cells. Erosive adenomatosis of the nipple may mimic PD clinically but the histological features are those of a benign neoplasm of the major nipple ducts. Immunohistochemistry allows definitive diagnosis of mammary PD but it could not be done in our patient due to financial constraints. Eczematoid changes of the nipple areolar complex and persisting soreness without obvious reason is a suspicious symptom for PD and calls for thorough evaluation including mammography. Regardless of the presence or absence of a palpable breast mass modified radical mastectomy should be advised in all patients of biopsy-proven mammary PD.

**Vandana Mehta, C. Balachandran,
Pankaj Bansal,* Geeta K***

Departments of Skin and STD and *Pathology, Kasturba Medical College, Manipal, India

Address for correspondence: Dr Vandana Mehta, Department of Dermatology, Kasturba Medical College, Manipal 576104, Karnataka, India. E-mail: vandanamht@yahoo.com

REFERENCES

1. Lancer HA, Moschella SL. Paget's disease of the male breast. J Am Acad Dermatol 1982;7:389-6.
2. Anderson WR. Bilateral Paget's disease of the nipple. Am J Obstet Gynecol 1979;15: 877-8.
3. Kao GF, Graham JH, Helwig EB. Paget's disease of the ectopic breast with an underlying intraductal carcinoma: Report of a case. J Cutan Pathol 1986;13:59-66.
4. Martin VG, Pelletiere EV, Gress D, Miller AW. Paget's disease in an adolescent arising in a supernumerary nipple. J Cutan Pathol 1994;21:283-6.
5. Sakarofas GH, Blanchard K, Sarr MG, Farley DR. Paget's disease of the breast. Cancer Treat Rev 2001;27:9-18.
6. Schelfhout VR, Coene ED, Delaey B. Pathogenesis of Paget's disease: Epidermal heregulin alpha, motility factor and the HER receptor family. J Natl Cancer Inst 2000;92:622-8.
7. Aktan AO, Gokoz A, Goksel H. Paget's disease without a palpable mass in the breast. Br J Surg 1990;77:226-7.