

# Endovascular treatment of ruptured distal posterior inferior cerebellar artery aneurysms: report of 11 cases

Zhuang Chen, Lin Li, Fanghe Gong, Weimin Wang

Department of Neurosurgery, Guang Zhou General Hospital of PLA, Guang Zhou, 510515, P.R.China.

## Abstract

**Objective:** To investigate the clinical characteristics and endovascular treatment of ruptured distal posterior inferior cerebellar artery (PICA) aneurysms.

**Methods:** 11 consecutive patients (7 women, 4 men, mean age of 49.2 years) with ruptured distal PICA aneurysms were studied retrospectively. All had onset of acute intraventricular or cerebellar haemorrhage, and subarachnoid hemorrhage (SAH). Hunt-Hess (HH) grades were H-H I in 1 patient, H-H II in 5 patients, H-H III in 4 patients and H-H IV in 1 patient on admission.

**Results:** All patients were treated by endovascular treatment, seven cases got endosaccular coiling and four cases got parent artery occlusion at the same time. All the patients were followed up one to four years. Recurrences occurred in 1 patient two years post-treatment, and were successfully retreated by endosaccular coiling and parent artery occlusion. The occluded PICA was recanalized one year post-treatment but without any growth of the aneurysm in one case. One year post-treatment, 2 patients had a modified Rankin Scale (mRS) score of 0, 8 patients had a mRS score of 1 and 1 patient had a mRS score of 2.

**Conclusions:** Coiling of ruptured distal PICA aneurysm, with or without parent vessel occlusion, was feasible, relatively safe and effective in preventing early/medium-term rebleeding. A strict angiographic follow-up, however, was necessary to detect recurrence.

**Key words:** Aneurysm, Posterior inferior cerebellar artery, Endovascular treatment

*African Health Sciences* 2014;14(1): 89-93 <http://dx.doi.org/10.4314/ahs.v14i1.14>

## Introduction

Aneurysms of the posterior inferior cerebellar artery (PICA) are rare, which comprise approximately 0.5%-3% of all intracranial aneurysms [1, 2]. So the missed diagnosis and misdiagnosis occur frequently as a result of the lack of acquaintance of its characteristics of the doctors. In this study, we have retrospectively analyzed the clinical features and results in 11 consecutive patients with ruptured distal PICA aneurysms, who were treated by endovascular treatment between January 2008 and September 2010.

## Materials and Methods

### *Patients and disease characteristics*

Between January 2008 and September 2010, 11 patients (4 males and 7 females, range 26-62 years, median age 49.2) were treated at our center.

Major clinical symptoms include sudden severe headache, nausea and vomiting with or without conscious disturbance. Head CT showed: 5 cases with the fourth ventricular hemorrhage to the third, even intracerebroventricle; 3 cases only with the fourth ventricular hemorrhage; 2 cases mainly with the fourth ventricular hemorrhage accompanying subarachnoid hemorrhage; 1 case with the fourth ventricular hemorrhage and a few hemorrhage of cauda cerebelli. Hunt-Hess (HH) grades were H-H I in 1 patient, H-H II in 5 patients, H-H III in 4 patients and H-H IV in 1 patient on the preoperation.

### *Digital subtraction angiography*

All patients were detected by digital subtraction angiography (DSA) in order to further ascertain the diagnosis within 24 h of admission to hospital and 6 artery aneurysms were in left and 5 were in right. The location of PICA aneurysms was classified according to the criteria of Lister's method: 2 cases were lateral medullary, 7 cases were tonsillomedullary and 2 cases were velum medullary, which include saccular aneurysm in 8 cases and dissecting aneurysm in 3 cases. There were 7 cases of small aneurysms (<5mm), 3 cases of middle size aneurysms (5-10mm) and 1 case of large aneurysms (13mm).

### Corresponding author:

Weimin Wang

Phone: +86 23 68754153

Fax Number: +86 23 68754153

Email: [feng.tmmu@gmail.com](mailto:feng.tmmu@gmail.com)

### Treatment

All patients had undergone treatment of endovascular coiling, in which on admission, 1 patient underwent external ventricular drainage due to acute obstructive hydrocephalus. All patients were operated under tracheal intubation, general anesthesia and heparinization. Select the optimal point of view and the proper coiling under the guidance of path graph. The CT scan was rechecked within 24 h after operation and no abnormality was found. Measures were taken to control the intracranial hypertension and prevent cerebral vasospasm in post-operation. Two patients underwent external ventricular drainage due to acute obstructive hydrocephalus and others had lumbar punctures regularly.

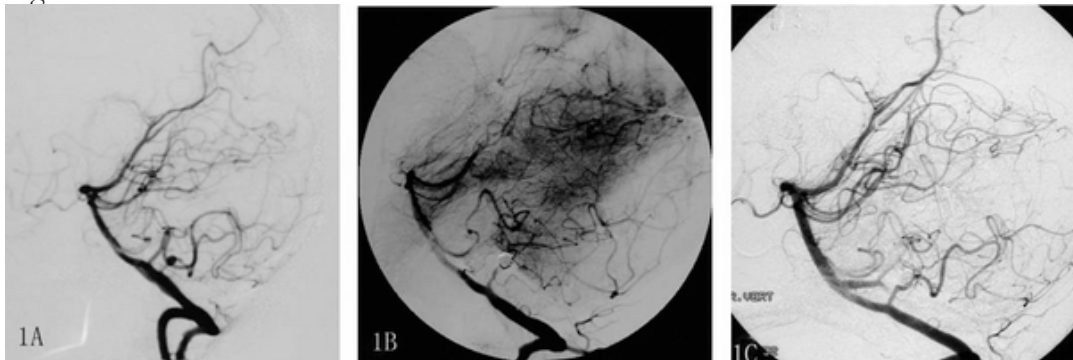
### Results

All patients were embolized by pure coils. The results showed that 7 cases were simple aneurysm occluded which include complete occluded aneurysm in 6 patients and partial in 1, and 4 cases were aneurysm occluded accompanied with parent arteries occluded. There were no operation-related complications occurred, including the hemorrhage which caused by aneurysm rupture and

thromboembolism. MRI and MRA were performed 1 to 3 months after embolization, and then DSA every year. All the cases were followed-up for an average of 2.3 years (range 1 to 4 years). The MRI examination showed that 3 cases existed different degrees of infarction in homolateral cerebellar hemisphere, but none with nerve dysfunction and infarction in brain stem. The examination of DSA showed that 1 case recurred within 2 years after operation and was completely occluded aneurysm and parent artery by coil again. In 1 case the parent arteries were patent but nonvisualization of aneurysms (Fig. 1)

Fig .1. A 47-year-old woman presented with the 4<sup>th</sup> and 3<sup>rd</sup> intraventricular hemarrhage and Hunt-Hess grade □. A lateral projection of the right vertebral angiogram showed aneurysm at the tonsilomedullary segment of right PICA (1A). The aneurysm was treated by endovascular occlusion of aneurysm and parent artery. The postocclusion angiogram showed complete obliteration of the PICA trunk and the aneurysm (1B). One-year follow-up DSA showed the occluded PICA was recanalized, but the aneurysm was still occluded completely(1C).

Fig 1

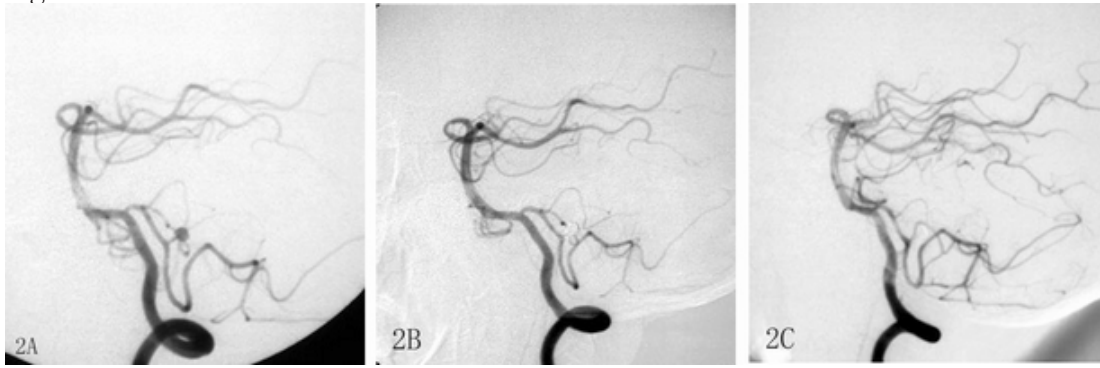


and others had no recurrence of aneurysms (Fig. 2). No hemorrhage occurred during follow-up. The scores of all the cases were measured by mRS: 0 in 2 cases, 1 in 8 cases, and 2 in 1 case.

Fig .2. A 53-year-old man presented with the 4<sup>th</sup> intraventricular hemarrhage and Hunt-Hess grade □. A

lateral projection of the left vertebral angiogram showed aneurysm at the lateral medullary segment of left PICA(1A).The aneurysm was treated by endosaccular coiling of aneurysm without parent vessel occlusion. The posttreatment angiogram(2B) and three-year follow-up DSA(2C) showed the aneurysm was complete occluded with patent PICA trunk.

Fig 2



## Discussion

Aneurysms of the posterior inferior cerebellar artery (PICA), accounting for 0.5%-3.0% of intracranial aneurysms and 20% of posterior circulation aneurysms, which are most commonly found on the vertebral artery or posterior inferior cerebellar artery, but only 15-30% on distal posterior inferior cerebellar artery [1, 2]. Some reports indicated that 60%-80% of aneurysms of the posterior inferior cerebellar artery are dissection aneurysms [3, 4]. The examination of DSA showed that aneurysms in 4 cases (36%) were in spindle shape, without clear aneurysm neck and exist different degrees of slight stricture of PICA, which meet the characteristic of dissection aneurysms. All the four patients had no obvious head trauma, infection and a history of other artery aneurysms, being considered as the autogenesis of dissection aneurysms. The examination of the other seven cases showed that the aneurysms were in the second to forth part of PICA with relative wide-neck and considered as sidewall aneurysm since the shapes were not totally consistent with the typical "saccular aneurysm", lying on the vascular bifurcations.

Clinical diagnosis of aneurysms depends on injury history and CT examination [5]. To acute onset, the patients whose CT usually show the fourth ventricle hemorrhage, and/or complicated with subarachnoid hemorrhage, and cerebellar hemorrhage, should be suspected posterior circulation aneurysm and immediately undertaken the examination of DSA [6]. Though there is limited knowledge regarding the natural history of posterior circulation aneurysm, the rebleeding rate in its' acute stage can reach to 24% after the first hemorrhage [7]. In our study, one case had relapsing hemorrhage after conservative treatment for 1 month. This case was Hunt-Hess grade IV on admission, though with positive treatment, the mRS

score of this case was 2, suggesting the patient cannot return to normal work. Eight of the cases (73%) got clear diagnoses and had intervention therapy in 72 h, and obtained a good result. These results showed that the rebleeding rate in acute stage was lower than that reported by the literature, suggesting the importance of early diagnosis and treatment.

As with other intracranial aneurysm, there were conversely opinions in the treatment measures of distal PICA aneurysms. The treatments include clip shut, clip and wrapping, extra-intracranial bypass after resection. The far lateral approach is always applied for the deep location of distal PICA aneurysms, but which causes big traumas [8]. Furthermore, aneurysm is common in the second to forth part of PICA, adjacent medulla and posterior group cranial nerves, which has great influence on the function of posterior group cranial nerves. Horowitz et al [9]. showed that 66% patients have different degree of posterior group cranial nerve palsy and 48.1% patients have lower cranial nerves dysfunction in a group of digging skull operation in Al-khayat's study [10]. It is no necessary to draw off the cranial nerve, cerebellum and brainstem and caused little injury using the interventional therapy. Recently, there are lots of reports regarding the interventional therapy of the artery aneurysms (including proximal and distal), all of which are considered to be safe and effective. All the incidences of interventional-related complications are below 10% and there is no report of injury of lower cranial nerves [11, 12]. In our study, all the patients picked up quickly except one with Hunt-Hess grade IV and no operating-related complications occurred, which is corresponded with other reports.

The main measure of endovascular treatment is endosaccular coiling, or with the local parent artery

occlusion [13, 14]. Endosaccular coiling can cure aneurysms and protect the parent artery without the hazard of ischemia of cerebellum and brainstem, which should be the optimal therapeutic measure. Nevertheless, some are dissecting aneurysms and it is easy to recanalize if the dissection point is not occlusive. Besides, the parent artery is narrow while the aneurysms are relative wide-neck. As a result, some normal assistant measures for saccular aneurysms, including balloon angioplasty and stent, cannot be applied to the endovascular treatment of the kinds of aneurysms. It's hard to make sure of the patency of parent artery after the aneurysms are completely occlusive.

Just for anatomy, the anterior three segments of PICA (anterior medullary, lateral medullary and tonsillomedullary) have the branches dominating medulla oblongata. There will be hazard of medullary infarct if these three segments are occlusive [15]. However, some studies showed that blocking these segments didn't induce normal injury of perforating vessels for the reasons that the medulla oblongata surface are rich in vessels and there are only a few normal perforating vessels when the aneurysms generated in the distal of PICA.

The balloon occlusion test was applied to evaluate the collateral circulation among the anterior inferior cerebellum, supracerebellum and PICA. In fact, it is hard to carry out the balloon occlusion test for its difficult operation and the narrow diameter of PICA. According to Nussbam's report [16], blocking the medullary velum and the distal of PICA can induce neither the ischemia of brainstem nor the cerebellum infarct. In Lim's study [12], all the five cases were treated using the aneurysm and parent artery aneurysm occlusion, and no ischemia of brainstem occurred. In our study, 4 cases (3 tonsillomedullary cases and 1 medullary velum case) were treated with the same method and no ischemia of medulla oblongata occurred in both the immediately postoperative interview and follow up. Furthermore, blocking one side of distal of PICA, even if with the genesis of local cerebellum infarct, cannot lead to obvious neurological deficits as a result of the abundant anastomosis of superior cerebellar artery, anterior inferior cerebellar artery and inferior posterior cerebellar artery in cerebellar surface.

The reexamination of MRI showed that there were small areas of ischemia lesions on the cerebellar suboccipital

surface but without the ataxia manifestations like unstable gait. Because of the tortuosity and stenosis of PICA, especial the micro-aneurysm, there is risk of penetrating the parent artery, even the aneurysms, by micro-wire. According to our experience, we should evacuate the micro-wire when the micro-catheter are near the aneurysms and release one to two loops of the coiling into the parent artery, then forward the loop as well as the micro-catheter to the cavity of the aneurysms, as the coiling inducing micro-catheter, to low the risk of penetrating the vessels by micro-wire. In our study, 4 cases of micro aneurysms whose maximum diameter were below 3mm, were treated with this method with satisfying effects.

One case reoccurred two years postoperatively and the short to middle-term reoccurrence rate was 9%. Although the aneurysms were not developed, the parent artery became patency in another case one year postoperatively, speaking volumes for the importance of endovascular treatment and DSA follow-up. Furthermore, since there were only a few cases in our study and relatively short follow-up time, especially in what conditions can we block the PICA main safely, we still need lots of cases to sum up the experiences. In a word, confirming the diagnosis using DSA and endovascular treatment as early as possible is effective and safe in preventing short and middle-term rebleeding for ruptured distal posterior inferior cerebellar artery aneurysms.

## References

1. Nabika S, Oki S, Migita K, Isobe N, Okazaki T, Watanabe Y. A ruptured distal posterior inferior cerebellar aneurysm. Our case and review of the literature, *Hiroshima J Med Sci.*2002; 51 93-96.
2. Orakcioglu B, Schuknecht B, Otani N, Khan N, Imhof HG, Yonekawa Y. Distal posterior inferior cerebellar artery aneurysms: clinical characteristics and surgical management, *Acta Neurochir (Wien).* 2005; 147,1131-1139, 1139.
3. Horiuchi T, Tanaka Y, Hongo K, Nitta J, Kusano Y, Kobayashi S, Characteristics of distal posteroinferior cerebellar artery aneurysms, *Neurosurgery.* 2003;53, 589-595, 595-596.
4. Mitsos AP, Corkill RA, Lalloo S, Kuker W, Byrne JV. Idiopathic aneurysms of distal cerebellar arteries: endovascular treatment after rupture, *Neuroradiology.* 2008; 50, 161-170.

5. Park JS, Lee TH, Seo EK, Cho YJ, Aneurysms of distal posterior inferior cerebellar artery, *J Korean Neurosurg Soc.* 2008; 44, 205-210.
6. Tokimura H, Yamahata H, Kamezawa T, Tajitsu K, Nagayama T, Sugata S, Takiguchi K, Taniguchi A, Niino M, Hirahara K, Takasaki K, Oyoshi T, Arita K, Clinical presentation and treatment of distal posterior inferior cerebellar artery aneurysms, *Neurosurg Rev.* 2011;34, 57-67
7. Tawk RG, Bendok BR, Qureshi AI, Getch CC, Srinivasan J, Alberts M, Russell EJ, Batjer HH. Isolated dissections and dissecting aneurysms of the posterior inferior cerebellar artery: topic and literature review, *Neurosurg Rev.* 2003; 26, 180-187.
8. Lin RS, Wang W, Guo A. Management of distal posterior inferior cerebellar artery aneurysms, *J Craniofac Surg.* 2012;23, 1388-1390.
9. Horowitz M, Kopitnik T, Landreneau F, Krummerman J, Batjer HH, Thomas G, Samson D. Posteroinferior cerebellar artery aneurysms: surgical results for 38 patients, *Neurosurgery.* 1998; 43, 1026-1032.
10. Al-khayat H, Al-Khayat H, Beshay J, Manner D, White J, Vertebral artery-posteroinferior cerebellar artery aneurysms: clinical and lower cranial nerve outcomes in 52 patients, *Neurosurgery.* 2005;56, 2-10, 11.
11. Isokangas JM, Siniluoto T, Tikkakoski T, Kumpu-lainen T, Endovascular treatment of peripheral aneurysms of the posterior inferior cerebellar artery, *AJNR Am J Neuroradiol.* 2008; 29, 1783-1788
12. Lim SM, Choi IS, Hum BA, David CA. Dissecting aneurysms of the distal segment of the posterior inferior cerebellar arteries: clinical presentation and management, *AJNR Am J Neuroradiol.* 2010; 31, 1118-1122.
13. Gruber A, Killer M, Bavinzski G, Richling B. Clinical and angiographic results of endosaccular coiling treatment of giant and very large intracranial aneurysms: a 7-year, single-center experience, *Neurosurgery.* 1999; 45, 793-803, 803-804.
14. Piepgras DG, Brown RJ. Management of unruptured intracranial aneurysms: perspectives on endosaccular coiling and persistent uncertainties, *Stroke.* 2008;39, 743-744.
15. Maimon S, Saraf-Lavi E, Rappaport ZH, Bachar G. Endovascular treatment of isolated dissecting aneurysm of the posterior inferior cerebellar artery, *AJNR Am J Neuroradiol.* 2006; 27, 527-532.
16. Nussbaum ES, Madison MT, Myers ME, Goddard J, Janjua T. Dissecting aneurysms of the posterior inferior cerebellar artery: retrospective evaluation of management and extended follow-up review in 6 patients, *J Neurosurg.* 2008; 109, 23-27.