

Stapedotomy and its effect on hearing – our experience with 54 cases.

Taiwo Olugbemiga Adedeji¹, Shabbir Indorewala²,
Abuzar Indorewala², Gaurav Nemade²

1. Department of Otorhinolaryngology Head and Neck Surgery, LAUTECH Teaching Hospital, Osogbo, Osun state, Nigeria, and clinical attaché Indorewala ENT Hospital, DNB Institution and Research, behind Mahamarg Bus Stand Old Mumbai Naka, Nashik, India

2. Indorewala ENT Hospital, DNB Institution and Research, behind Mahamarg Bus Stand Old Mumbai Naka, Nashik, India.

Abstract.

Introduction: This study reviews the cases of stapedotomy and evaluates its effectiveness at improving hearing loss in patients with otosclerosis.

Materials and methods: Retrospective review of patients' records who had clinical and audiometric diagnosis of otosclerosis from January to December 2012

Results: A total of 54 stapedotomy surgeries (52 unilateral and 1 bilateral surgeries) were received. Average post-operative ABG for 0.5, 1, 2 and 4 KHz showed that 61.1% had complete closure of ABG (ABG < 10 dB) compared with 1.6% preoperatively and 85.2% had closure of ABG to within 20dB compared with 4.7% preoperatively ($t = 13.89$, $p = 0.000$). More than 94% had hearing improvement and 81.5% had ABG closure greater than 10 dB postoperatively (mean gain 23.38 ± 12.37 , $t = 13.89$, $p = 0.000$). A total of 13% complications were recorded with TM perforation (5.6%) being the commonest complication.

Conclusion: Stapedotomy is an effective surgical procedure for the treatment of otosclerosis which leads to improvement in patients' quality of life. A favorable hearing outcome can be obtained by the combination of experienced hands with minimal surgical trauma and appropriate surgical technique.

Keywords: Otosclerosis, Stapedotomy, conductive hearing loss, air-bone gap

DOI: <http://dx.doi.org/10.4314/ahs.v16i1.36>

Cite as: Adedeji TO, Indorewala S, Indorewala A, Nemade G. Stapedotomy and its effect on hearing – our experience with 54 cases. *Afri Health Sci.* 2016;16(1): 276- 281. <http://dx.doi.org/10.4314/ahs.v16i1.36>

Introduction

Otosclerosis is a disease that causes progressive hearing loss due to fixation of stapes by abnormal bony deposit¹. This leads to impairment of the normal conducting mechanism of the sound conducting system in the middle ear¹. Complete understanding of what causes otosclerosis is not known yet but published studies however showed

that it is a genetically transmitted disease which is usually inherited in an autosomal dominant pattern with variable penetrance^{2,3}. Other factors linked to otosclerosis include autoimmune and viral infections^{4,6}. A recent systematic review however concluded that more evidence is necessary to link otosclerosis and autoimmunity^{7,8}.

Otosclerosis occurs in about 10% of the Caucasian population^{1,3}; it is less common in the Japanese and South American descent and rare in the Afro-American population^{1,8}. In about 60% of the affected patients, family members also have otosclerosis^{4,6}. The disease occurs twice as much in women than men¹⁻⁴ and pregnancy has been reported to contribute to worsening of the symptoms in the affected patient⁸.

The most common symptom is a slow progressive hearing loss that presents from age 20 to 45 years⁹.

Corresponding author:

Taiwo Olugbemiga Adedeji,
Department of Otorhinolaryngology
LAUTECH Teaching Hospital,
Osogbo, Osun State, Nigeria
+2348068830318, +2348088348795
P.O Box 2620, Osogbo, Nigeria
e-mail Address: adedejitaiwo2003@yahoo.com

Otosclerosis can occur in both ears in about 80% of patients. The severity of the hearing loss is variable, but total deafness is rare. If the disease involves the otic capsule, a sensorineural hearing loss can occur^{9,10}. Other symptoms of otosclerosis include tinnitus and dizziness and these symptoms can improve with surgical intervention in a number of cases⁹⁻¹².

Diagnosis is usually made by a combination of history of progressive hearing loss and audiometric evaluation^{13,14}. Pure tone audiometric test shows the typical conductive hearing loss pattern. Impedance audiometry often shows stiffening of the ossicular chain and acoustic reflexes may be absent. Computerised tomographic scan of the temporal bone is specific but insensitive¹².

Various treatment modalities for otosclerosis have been described^{1,10,12,13}. This includes watchful waiting, medical, hormonal (avoidance of estrogens or use of estrogen blockers), hearing aids and surgical^{1,10,12,13}. Surgery in the form of partial (stapedotomy) or complete (stapedectomy) removal of the fixed stapes and replacement with a prosthetic device (implant) has produced excellent hearing results that remain good for many years and proved to be effective in improving associated tinnitus in the affected patients¹⁴⁻¹⁸. This surgery that was initially described by Shea¹⁹ had made remarkable advances in both the technique and implant materials which have contributed to improvement in surgical outcome^{17,18,20}.

The aims of this study were to review all the cases of otosclerosis that were managed by stapedotomy over a year period and evaluate the hearing outcome in the affected patients. It also compares the hearing outcome with the findings from other published studies.

Materials and method

Medical records of all the cases of stapedotomy done from January 2012 to December 2012 at Indorewala ENT Hospital, DNB Institution and Research, Nashik, India were retrospectively reviewed. Data was obtained from the records of the patients that had minimum follow up after surgery of at least 6 months. Information retrieved by the investigator from the record included; socio-demographics, side of the ear affected, type of prosthesis used and pre and postoperative pure tone audiogram for hearing outcome and associated surgical complication(s). Diagnosis of otosclerosis was based on the history, medical status with otomicroscopy, Rinne and webber test, impedance audiometry with tympanogram and stapedius

reflex test. All the patients reviewed had pure-tone audiograms pre-operatively and post-operatively. The PTA was performed using the Elkon 3N3 multi, by Elkon India, calibrated yearly to ISO standard in a sound-proof room. We compiled data on the pre- and post-operative air – bone gap (ABG) at 0.5, 1, 2 and 4 KHz. The mean thresholds of the above-mentioned data were determined at 0.5, 1, 2, and 4 kHz. The ABG was calculated using air conduction (AC) and bone conduction (BC) thresholds recorded on the same audiogram. Postoperative hearing gain was then calculated from the ABG before the operation minus the ABG of the last follow-up examination (minimum of 3 months after surgery when all the healing processes had been adjudged completed and the patient was clinically stable). Patients whose audiometric data was insufficient or who were lost to follow-up were excluded from the study.

All surgical procedures were performed via endomeatal approach under local anaesthesia; local blockage of the ear with 1% lidocaine in 1:30 000 adrenaline. A posterior tympanomeatal flap (posterior tympanotomy) was incised and raised. The posterior tympanic bone (bony overhang) was then drilled to permit full visualization of the oval window while corda is usually preserved. The stapes was then inspected and palpated to confirm the diagnosis of otosclerosis. The lateral ossicular chain was also palpated to verify its mobility. Posterior and anterior crura were weakened by drill. Mid footplate area demucosified and mid footplate 0.7 mm fenestration drilled. The distance between the oval window and the long process of the incus was then measured, and appropriate size prosthesis inserted. Following prosthesis insertion, stapes superstructure was removed by separating the incudostapedial joint and cutting the stapedia tendon, the mobility of chain confirmed, tympanotomy flap closed and hearing was tested by whispered voice. We usually used 5 mm X 0.6 mm teflon piston (Gyrus fluoroelastic piston).

Results

A total of 54 stapedotomies had complete data for analysis. There were 53 patients (52 unilateral and 1 bilateral surgeries) with 30 males and 23 females; male: female ratio was 1.3: 1. The age of the patients ranged from 18 to 70 years with a mean age of 42.02 ± 12.87 years and age group 31 – 40 year were the most affected group (31.2%). The age sex and laterality of the ear operated are shown in table 1.

Table 1: Age, sex and side of the ear operated

Variables	Frequencies	Percentage
Age range (yrs)		
15 – 30	11	20.4
31 – 45	24	44.4
45 – 60	13	24.1
61 and above	6	11.1
Total	54	100
Mean age	42.01	± 12.8
Gender of the patients		
Male	30	56.6
Female	23	43.4
Laterality of the ears		
Right	27	50
Left	27	50

Table 2 compares the pre and postoperative air-bone gap and figure 1 shows the mean ABG obtained for those for frequencies 0.5, 1, 2 and 4 KHz among the patients various frequencies tested.

Table 2: Preoperative and postoperative ABG at 0.5, 1, 2 and 4 KHz compared

ABG(dB)	Frequencies (N=54)							
	.5		1		2		4 (KHz)	
	PreOP	postOP	preOP	postOP	preOP	postOP	preOP	postOP
<10	1	32	1	39	3	42	1	37
11 – 20	2	13	2	7	11	7	9	13
21 – 30	1	4	6	2	26	1	20	6
31 – 40	18	3	24	3	12	2	18	2
41 – 50	20	1	15	2	2	2	4	2
≥ 51	12	1	6	1	-	-	-	-
Total	54	54	54	54	54	54	54	54

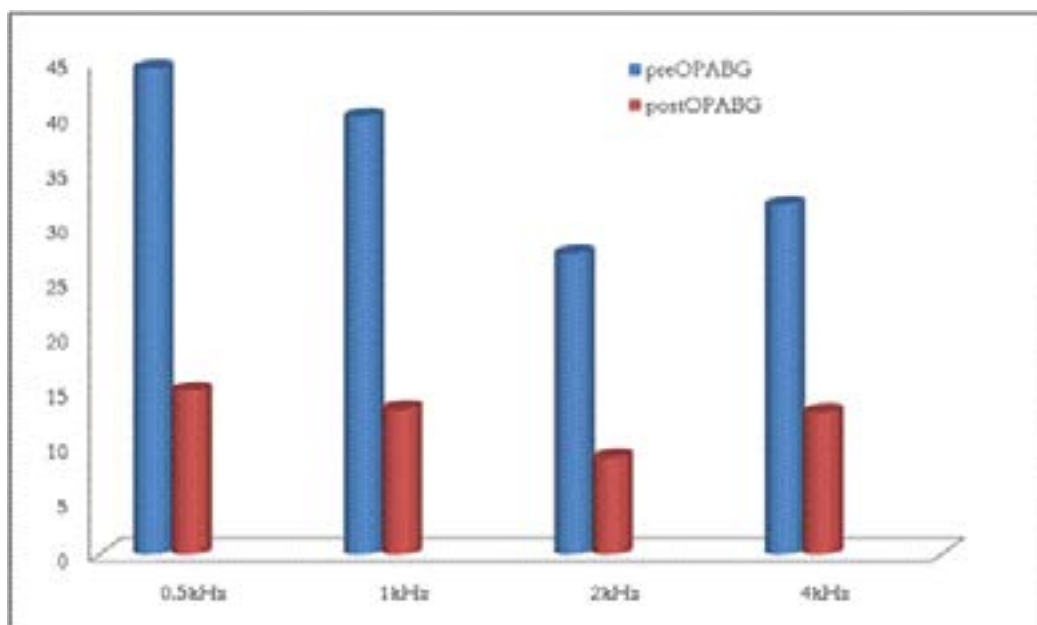


Figure 1: Mean of Preoperative and postoperative air-bone gap at .5, 1, 2 and 4 kHz

The average of post-operative ABG for 0.5, 1, 2 and 4 KHz showed that 33 (61.1%) had ABG < 10 dB, 13 (24.1%) had ABG 11 – 20 dB, 4 (7.4%) had ABG 21 – 30 dB and 4 (7.4%) had ABG > 30 dB (mean 12.48 ± 11.65), compared with preoperative values; 1 (1.9%) ABG < 10dB, 2 (3.7%) ABG 11 – 20 dB, 7 (13.0%) ABG 21 – 30 dB and 44 (81.5%) ABG > 30 dB (mean $35.86 \pm$

9.33) ($t = 13.89$, $p = 0.000$). Hearing gain postoperatively is the mean of preoperative ABG – mean of post operative ABG (figure 2). Overall, 94.4% had improvement in their hearing and 81.5% had ABG closure greater than 10 dB postoperatively (mean gain 23.38 ± 12.37 , $t = 13.89$, $p = 0.000$) figure 2. Seven (13%) complications were recorded; TM perforation 3 (5.6%), vertigo 2 (3.7%), facial nerve paresis 2 (3.7%).

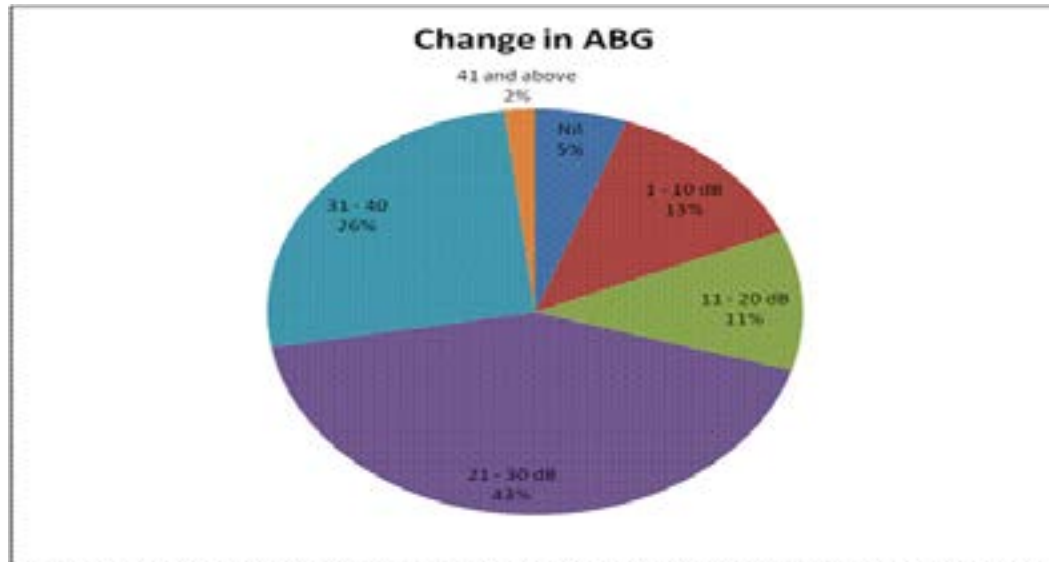


Figure 2: Postoperative hearing gain among the patients

Discussion

The present study, in agreement with the previous published studies^{10,14-18} showed the relevance of stapes surgery especially as regards improvement in the hearing status of patients with otosclerosis. The reason for marginal male preponderance in this study is not known as the disease is known to be predominant in female^{1-4,17-21}.

Various fenestration techniques for stapes prosthesis implantation had been described^{14,17,21-23}. Sergi et al²² reported the use of Laser fenestration technique and concluded that laser stapedotomy is an effective and safe procedure for the treatment of otosclerosis. Yavuz et al²¹ in their study “Reliability of microdrill stapedotomy: comparison with pick stapedotomy:” concluded that the microdrill and pick stapedotomy techniques produced similar hearing results and complication rates and recommended that the microdrill can be a useful technique in performing a stapedotomy. In our center, micro-drill fenestration technique with Teflon prosthesis (fluoroplastic piston, of appropriate size) is generally used for all our patients.

The pre and post operative hearing evaluation (table 2)

revealed marked improvement in the patients’ hearing status as greater number had closure of their air-bone gap across all the frequencies tested (0.5, 1, 2 and 4 kHz). Average air-bone gap of 61.1% complete closure and 85.2% of closure to within 20 dB seen in this study is comparable with report from many published studies. Sergi et al²² in Italy reported progressive closure of air-bone gap that began in the early postoperative period and continued to improve through the late post-operative period. Our outcome is similar to the findings of Vincent et al²⁴ in France who reported ABG closure of < 10dB in 63.4% and < 20 dB in 74.6% of their patients. Kuo et al²⁰ in Taiwan compared Nitinol prosthesis with the conventional prosthesis and reported ABG closure to within 10 dB in 75% of the patients with Nitinol piston and 33.3% in the patients with the conventional piston. Bast et al¹⁴ reported ABG closure (< 10 dB) in 78% of their cases and Babighian et al²⁵ reported ABG < 10dB in 54% of their series.

Although 94.4% of the patients achieved some level of closure of ABG and 81.5% achieved ABG closure of \geq

10dB from the present study, success in stapes surgery had been a subject of controversy and there had not been a consistent conclusion²⁰. Emphasis has however been placed on post operative ABG closure of within 10dB as a measure of surgical success^{26,27}. Going by this, 61.1% success as obtained from this study is comparable to findings from many previous published studies^{14,20, 22,24,25}.

Factors that influenced surgical outcome in stapes surgery had been extensively discussed^{14,20,22,28-31}. Babighian et al²⁵ reported that outcome of revision surgery in stapedotomy is less favourable than the primary one. Kursten et al²⁸ in their report “Long term result after stapedectomy versus stapedotomy”, they concluded that stapedotomy gave better results and that stapedotomy should be the preferred surgical technique in the treatment of otosclerosis. In our present study stapedotomy is generally performed with Teflon piston as implant.

Complication can occur during stapedotomy even in the experienced hand, and to minimize the complication rate, the most experienced senior surgeon performed all the surgeries. All the observed (minor) complications in this study resolved within six weeks after surgery. Major complications in stapes surgery can militate against better outcome and may necessitate revision surgery^{25,31,32}. Revision surgery is known for poorer outcome, every effort should be geared against this, and hence the need for experience, appropriate surgical technique and attention to details in stapes surgery cannot be over emphasized. Other factors that may contribute to failure of hearing improvement postoperatively include; prosthesis displacement²⁴, pre-operative tympanosclerosis and advanced otosclerosis with associated sensorineural hearing loss³¹ and oval window fibrosis^{25,32}. These factors were already taken into consideration as all our patients had preoperative otomicroscopy to exclude tympanosclerosis and proper surgical technique of stapedotomy that is associated with less postoperative complications.

Conclusion

Stapedotomy is an effective surgical procedure for the treatment of otosclerosis which leads to improvement in patients' quality of life. A good and favorable hearing outcome can be obtained by the combination of experienced hands with minimal surgical trauma and an appropriate surgical technique. This will ultimately lead to less

post-operative complications and the need for revision surgery with its attendant poorer outcome.

Conflict of interest

The authors declare that they have no conflict of interest.

Financial disclosure statement

The authors declare that they have no direct or indirect financial support from any individual, group or organization.

References

1. Hammerschlag PE, Scheer AA, Fishman A: Revision Stapedectomy: A Review of 308 Cases. *Laryngoscope*. 1998; 108: 1794-1800 PubMed
2. Moumoulidis I, Axon P, Baguley D, Reid E. A review on the genetics of otosclerosis. *Clinical otolaryngology*. 2007 32: 239-47
3. Schrauwen I, Khalfallah A, Ealy M, Fransen E, Claes C, et al. COL1A1 association and otosclerosis: a meta-analysis. *American journal of medical genetics*. Part A 2012; 158A: 1066-70
4. Niedermeyer HP, Arnold W. Etiopathogenesis of otosclerosis. *ORL*. 2002; 64: 114-9 PubMed
5. Niedermeyer HP, Gantumur T, Neubert WJ, Arnold W. Measles virus and otosclerosis. *Advances in oto-rhino-laryngology*. 2007; 65: 86-92
6. Arnold W, Busch R, Arnold A, Ritscher B, Neiss A, Niedermeyer HP. The influence of measles vaccination on the incidence of otosclerosis in Germany. *Eur Arch Otorhinolaryngol*. 2007; 264: 741-8 PubMed
7. Karosi T, Szekanecz Z, Sziklai I. Otosclerosis: an autoimmune disease? *Autoimmunity reviews*. 2009; 9: 95-101
8. Komune N, Ohashi M, Matsumoto N, Kimitsuki T, Komune S, Yanagi Y. No evidence for an association between persistent measles virus infection and otosclerosis among patients with otosclerosis in Japan. *Journal of clinical microbiology*. 2012; 50: 626-32
9. Gristwood RE, Venables WN. 2003. Otosclerosis and chronic tinnitus. *The Annals of otology, rhinology, and laryngology* 112: 398-403
10. Sobrinho PG, Oliveira CA, Venosa AR. 2004. Long-term follow-up of tinnitus in patients with otosclerosis after stapes surgery. *The international tinnitus journal* 10: 197-201
11. Deggouj N, Castelein S, Gerard JM, Decat M, Gersdorff M. 2009. *Tinnitus and otosclerosis*. *B-Ent* 5: 241-4

12. Naumann IC, Porcellini B, Fisch U. 2005. Otosclerosis: incidence of positive findings on high-resolution computed tomography and their correlation to audiological test data. *The Annals of otology, rhinology, and laryngology* 114: 709-16
13. Shambaugh GE, Jr. 1990. Fluoride therapy for otosclerosis. *Archives of otolaryngology-head & neck surgery* 116: 1217
14. Bast F, Weikert S, Schrom T. Treatment of Otosclerosis with a Superelastic Nitinol Piston: First Results. *Indian J Otolaryngol Head Neck Surg.* 2011; 63(2): 126–131. doi: 10.1007/s12070-011-0139-4
15. Marchese MR, Paludetti G, De Corso E, Cianfrone F. 2007. Role of stapes surgery in improving hearing loss caused by otosclerosis. *The Journal of laryngology and otology* 121: 438-43
16. Sparano A, Leonetti JP, Marzo S, Kim H. 2004. Effects of stapedectomy on tinnitus in patients with otosclerosis. *The international tinnitus journal* 10: 73-7
17. Brown KD, Gantz BJ. Hearing Results after Stapedotomy with a Nitinol Piston Prosthesis. *Arch Otolaryngol Head Neck Surg.* 2007; 133(8):758-762. doi:10.1001/archotol.133.8.758
18. Hornung JA, Brase C, Zenk J, Iro H. Results obtained with new superelastic nitinol stapes prosthesis in stapes surgery. *Otol Neurotol.* 2011 Dec; 32(9):1415-21. doi: 10.1097/MAO.0b013e3182355886.
19. Shea JJ. Symposium; the operation for the mobilization of the stapes in otosclerotic deafness. *Laryngoscope* 1956; 66:729–84
20. Kuo C, Wang M, Shiao A. Superiority of Nitinol Piston over Conventional prostheses in Stapes Surgery: First Comparative result in the Chinese Population in Taiwan. *J Chin Med Ass.* 2010; 73(5): 241 PubMed – 247
21. Yavuz H, Caylakli F, Ozer F, Ozluoglu LN. Reliability of microdrill stapedotomy: comparison with pick stapedotomy. *Otol Neurotol.* 2007 Dec; 28(8):998-1001.
22. Sergi B, Scorpecci A, Parrilla C, Paludetti G. Early hearing assessment after "one shot" CO2 laser stapedotomy: is it helpful to predict inner ear damage and the functional outcome? *Otol Neurotol.* 2010 Dec; 31(9):1376-80. doi: 10.1097/MAO.0b013e3181cdd8e3.
23. Silverstein H, Jackson LE, Conlon WS, Rosenberg SI, Thompson Jr JH. Laser stapedotomy minus prosthesis (laser STAMP): absence of refixation. *Otol Neurotol.* 2002 Mar; 23(2):152-7.
24. Vincent R, Rovers M, Zingade N, Oates J, Sperling N, Devèze A, Grolman W. Revision stapedotomy: operative findings and hearing results. A prospective study of 652 cases from the Otolaryngology-Neurotology Database. *Otol Neurotol.* 2010 Aug; 31(6):875-82. doi: 10.1097/MAO.0b013e3181e8f1da.
25. Babighian GG, Albu S. Failures in stapedotomy for otosclerosis. *Otolaryngol Head Neck Surg.* 2009 Sep; 141(3):395-400. doi: 10.1016/j.otohns.2009.03.028.
26. Harris JP, Gong S. Comparison of hearing results of nitinol SMART stapes piston prosthesis with conventional piston prostheses: postoperative results of nitinol stapes prosthesis. *Otol Neurotol* 2007; 28:692–5.
27. Huber AM, Veraguth D, Schmid S, Roth T, Eiber A. Tight stapes prosthesis fixation leads to better functional results in otosclerosis surgery. *Otol Neurotol* 2008; 29:893–9.
28. Kürsten R, Schneider B, Zrunek M. Long-term results after stapedectomy versus stapedotomy. *Am J Otol.* 1994 Nov; 15(6):804-6.
29. Quaranta N, Besozzi G, Fallacara RA, Quaranta A. Air and bone conduction change after stapedotomy and partial stapedectomy for otosclerosis. *Otolaryngol Head Neck Surg.* 2005 Jul; 133(1):116-20.
30. House HP, Hansen MR, Al Dakhail AA,
31. Vincent R, Oates J, Sperling NM. Stapedotomy for tympanosclerotic stapes fixation: is it safe and efficient? A review of 68 cases. *Otol Neurotol.* 2002 Nov; 23(6):866-72.
32. Lesinski SG. Causes of conductive hearing loss after stapedectomy or stapedotomy: a prospective study of 279 consecutive surgical revisions. *Otol Neurotol.* 2002 May; 23(3):281-8.