

Aetiology and Treatment Outcome of Non-traumatic Small Bowel Perforations at Mbarara Hospital in South-Western Uganda

D. Mutiibwa¹, A. Lopez¹, G. Tumusiime¹, D. Riding¹, A. Diaz²

¹Department of surgery, Mbarara University of Science and Technology (MUST); ²Department of pathology, Mbarara University of Science and Technology – South-Western Uganda

Correspondence to: Dr. David Mutiibwa, Email: mutiibwadavid@yahoo.com

Background: *Non-traumatic small bowel perforation (SBP) is the most common form of gastrointestinal perforation in sub-Saharan Africa. Although SBP is a surgical emergency associated with complications, information regarding its aetiology is scanty in Uganda. This study was aimed at determining the aetiology and document treatment outcomes of non-traumatic small bowel perforations in South-western Uganda.*

Methods: *This was a descriptive case series of 87 consenting patients with non-traumatic SBP confirmed at laparotomy, on the emergency ward of Mbarara University Teaching Hospital. They were enrolled from September 2011 to May 2012. Specimens for blood culture, stool microscopy, HIV testing and tissue biopsies at the site of perforation were collected and analyzed. Patient follow-up was done till discharge.*

Results: *Of the 78 biopsies performed, 66(84.6%) had histological features suggestive of typhoid perforations while 12(15.4%) had features of non-specific inflammation. Salmonella typhi was isolated in 13(15.0%) out of the 87 patients. Isolates were susceptible to Ceftriaxone and Ciprofloxacin. All patients tested HIV negative. Ascaris lumbricoides were seen in two patients. Re-laparotomy was done in four patients with new perforations, two with anastomotic breakdown and two with intra-abdominal abscesses. Wound sepsis was observed in 25(28.7%). Average length of hospital stay was 13 days. Some 10(11.5%) patients died.*

Conclusions: *Most cases of non-traumatic SBP in south western Uganda are associated with Salmonella infection. There is need to enhance laboratory capacity to detect typhoid and preventive measures should be instituted in the general population.*

Introduction

Non-traumatic small bowel perforation (SBP) is the most common form of gastrointestinal perforation in developing nations.^{1, 3, 5, 6} Perforation of the intestines results in the potential for bacterial and chemical contamination of the abdominal cavity which leads to acute diffuse peritonitis.⁷ Although SBP is a surgical emergency¹⁶ associated with high morbidity and mortality in both children and adults,⁵ information regarding its aetiology is scanty in Uganda. Early diagnosis, good resuscitation, timely surgical intervention and appropriate antibiotic coverage can improve the outcome of patients with SBP.

Patients and Methods

Non-traumatic small bowel perforation was defined as any perforation between the ligament of Treitz and the ileo-caecal junction (ICJ) in the absence of trauma or mechanical bowel obstruction.

This was a descriptive case series in which consecutive enrolment of patients with non-traumatic SBP, confirmed at laparotomy, was done on emergency ward in Mbarara University Teaching Hospital from September 1, 2011 to May 31, 2012. The study was approved by the Faculty Research and Ethics Committee and the Institutional Review Board of Mbarara University of Science and Technology.

Data collection

Pre-operatively, patients with diffuse peritonitis following an acute febrile illness were assessed and their clinical symptoms and signs were noted. They were resuscitated and any electrolyte derangements were corrected. 8-10ml of blood was cultured in BACTEC culture medium (aerobic and anaerobic). Culture bottles were incubated at 35-37°C. Those with evidence of bacterial growth were sub-cultured in MacConkey agar, Blood agar and Chocolate agar. Isolated organisms were tested for antimicrobial susceptibility by Kirby-

Bauer disc diffusion method using Ceftriaxone, Ciprofloxacin, Chloramphenicol, Nalidixic acid, Gentamycin, Tetracycline, Septrin, Amoxicillin, Ampicillin and Penicillin-G discs. HIV testing and stool microscopy to look for helminths were also performed.

At laparotomy, the number of perforations, proximity of the distal perforation from the ICJ and the type of surgical procedure performed were documented. Tissue biopsies at the site of the perforation were taken for histology. Patients were followed up to the time of discharge. Details of post-operative complications, further surgical procedures, length of hospital stay and clinical outcome were documented. Data was entered in Ms Excel and analyzed using STATA 11. Univariate analysis was done to generate the proportions (percentages), mean or median of different variables. These were summarized in tables and bar graphs as illustrated below.

Results

A total of 87 patients with SBP were enrolled into the study. The majority (85%) of them were referred from nearby health units. All patients had a similar presentation, that is, fever followed by acute onset of abdominal pain and rapid deterioration of the patient's general condition. Most patients were from greater Mbarara (56.3%). The mean duration of symptoms was 13 days and the mean length of the perforations from the ileo-caecal junction (ICJ) was 15cm.

The demographics characteristics, clinical presentation, laboratory results and outcomes are summarized in Tables 1, 2, 3 and Figure 1. The male to female sex ratio was 2.6 : 1. Half (50.6%) were students while 36.7% were subsistence farmers. All patients were HIV – negative. At operation, the number of perforations ranged from one in 57.5% to six in 3 (3.4%) of the patients. Simple repair of the perforations was done in a quarter of the case. The majority had resection and either ileoileal anastomosis (46%) or ileo-transverse anastomosis (24%). One patient had colostomy and ileostomy after breakdown of his ileotransverse anastomosis at relaparotomy (Table 3). The specimens removed were subjected to histological examinations.

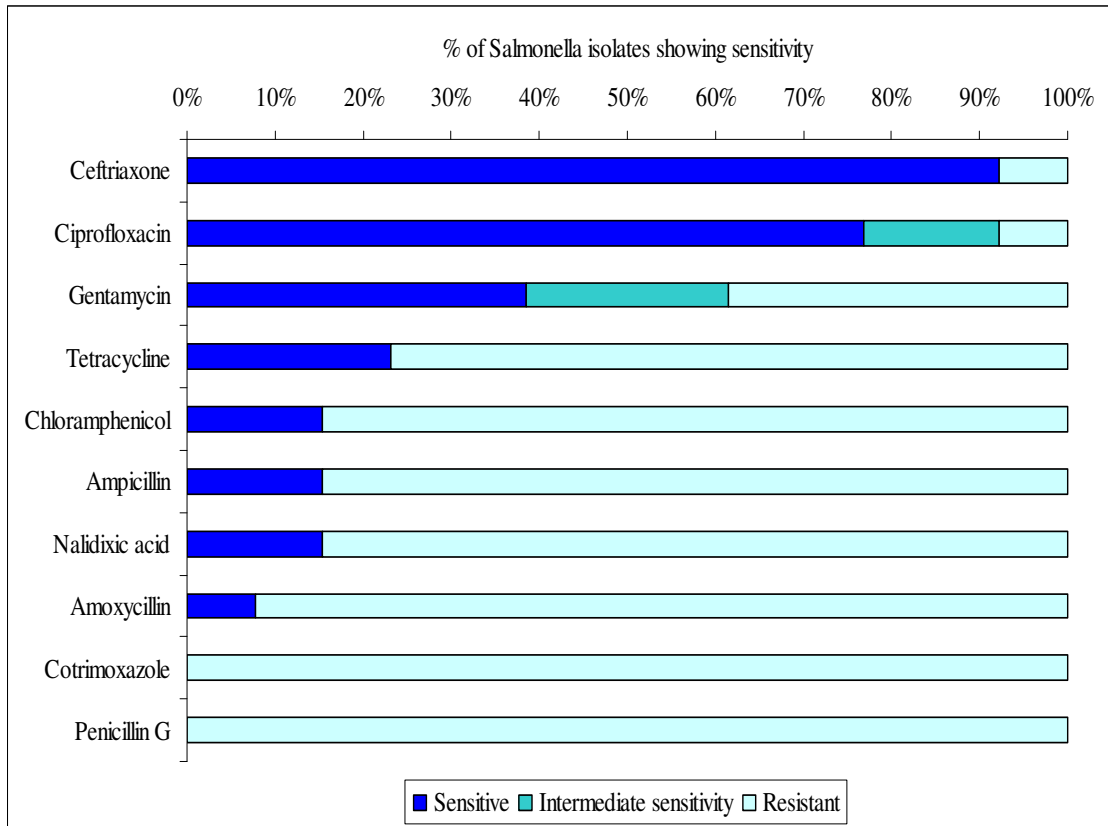
Table 1 – Baseline Patient Characteristics

Variable		No.	%	Median	IQR
Sex	Male	63	72.4		
	Female	24	27.6		
Age	All			14	10-25
	Male			18	12-28
	Female			11	6.75-14.25
HIV status	Positive	0	0		
	Negative	87	100		
Distance travelled from home district to Mbarara Hospital				55 Km	
Occupation	Pre-school	7	8.1		
	Student (primary/secondary)	44	50.6		
	Refugee/prisoner	4	4.6		
	Subsistence farmer	32	36.7		

Key: HIV = Human immunodeficiency virus; IQR = interquartile range.

Table 2. Associated microbiology and pathology of small bowel perforations

Variable		No.	%
<i>Blood culture</i>	Negative	69	79.3
	Salmonella	13	15.0
	Escherichia coli	4	4.6
	Klebsiella	1	1.1
<i>Stool microscopy</i>	Negative	84	96.6
	Ascaris	2	2.3
	Yeasts	1	1.1
<i>Pathology report</i>	Non-specific inflammation	12	13.8 (*15.4%)
	Consistent with typhoid perforations	66	75.9 (*84.6%)
	Unavailable	09	10.3


Figure 1. Sensitivity of Salmonella isolates obtained from positive blood cultures

Of the 78 histopathological reports available, 66 (84.6%) had features reported to be consistent with typhoid perforations. The rest (15.4%) had Non-specific inflammation. Sixteen of the tissue biopsy slides were re-analyzed from Mulago National Referral Hospital for quality control and the histological features were consistent with typhoid fever perforations. The features observed included: hyperplasia of Peyer's patches, increased number of macrophages, presence of typhoid cells, congestion of blood vessels, oedema of the wall and perforation of the wall with peritonitis.

Table 3. Characteristics, procedures and outcomes of small bowel perforations

Variable		No.	%	Median	IQR
Duration of symptoms (days)	0-7	14	16.1		
	8-14	49	56.3		
	15-21	16	18.4		
	>21	8	9.2		
	Overall			13	10-15
Proximity to ICJ (cm)	0-10	30	34.5		
	11-20	40	46.0		
	21-30	16	18.4		
	>30	1	1.1		
Number of perforations	1	50	57.5		
	2	25	28.7		
	3	6	6.9		
	4	2	2.3		
	5	1	1.1		
	6	3	3.4		
First procedure	Simple repair	22	25.3		
	Ileoileal anastomosis	40	46.0		
	Ileotransverse anastomosis	21	24.1		
	Right hemicolectomy	4	4.6		
Second procedure	None	79	90.8		
	Intra-abdominal abscess drainage	2	2.3		
	Further perforation and repair	4	4.6		
	Anastomotic leak repair	2	2.3		
Third procedure	None	86	98.9		
	Colostomy & Ileostomy	1	1.1		
Length of hospital stay (days)	0-7	26	29.9		
	8-14	47	54.1		
	15-21	7	8.0		
	>21	7	8.0		
	Overall			14	7-14
Outcome	Wound sepsis	25	28.7		
	Discharged	77	88.5		
	Self-discharged	0	0		
	Died	10	11.5		

KEY: ICJ = ileocaecal junction; IQR = interquartile range

Discussion

In this study, Small bowel perforations (SBP) predominantly affected the low socio-economic class especially teenagers and primary school going males from rural peasant families. Compared to the urban residents, this population has a low frequency of HIV other pre-existing comorbidities or exposures to long-term medications such as steroids. All our patients were HIV negative. The presentation of SBP was predominantly

acute in nature with an average duration of symptoms of two weeks and with most of the perforations located in the terminal ileum which is synonymous with typhoid fever perforations. Therefore, the possible poor hygiene and environmental sanitation in homes and schools coupled with poor health seeking behaviour may be the possible risk factors for the high incidence of SBP in our patient population.

In the management of patients with non-traumatic SBP, adequate resuscitation is crucial in the preoperative phase, with major emphasis on the patient's hemodynamic state as well as correction of electrolyte derangements. The general condition of the patient, the number of perforations and their location from the ileo-caecal junction, the condition of the intestine, and surgeon's experience define the operative procedure and prognosis/outcome. Majority of our patients had resection and primary end-to-end anastomosis in 2 layers using vicryl 2/0 (46%). Refreshening the edges and simple closure of the perforation was done in 25.3% of the cases while end-to-side ileo-transverse anastomosis was done for perforations less than 10cm from the ileo-caecal junction (24.1%). Right hemicolectomy with end-to-end ileo-transverse anastomosis was done in 4.6% of the cases. Nadkharni et al¹⁸ advocated for exteriorization of the affected gut (ileostomy), which had a lower mortality rate. This is being done in some of the hospitals in south western Uganda but the practice has not yet been embraced in Mbarara Regional Referral Hospital hence the need for more research to compare treatment outcomes among patients with ileostomy versus those with primary gut repair procedures.

Non-traumatic small bowel perforation may be due to different pathologies. In developing countries, like Uganda where this study was conducted, infections are predominant. These include: typhoid fever, tuberculosis, and parasitic infections like ascariasis and taenia^{1, 5, 6}. However, in the developed world, non-traumatic perforations of the small intestine are rare and they are due to non-infectious causes such as Crohn's disease, intestinal malignancies, bowel ischaemia, and necrotizing vasculitis.^{9, 12} Ingestion of foreign bodies like fish bones and tooth picks may also lead to perforation of the small intestine.¹⁹ Catena et al¹⁰ reported cases of SBP among patients who had kidney transplant – here; the perforation is related to the use of high doses of immunosuppressive medication. Similarly, Cheung et al⁸ reported some cases of SBP among patients receiving radiotherapy for cervical carcinoma and other intra-abdominal malignancies. Opportunistic fungal and viral infections have also been implicated among HIV/AIDS patients⁴ but we were unable to investigate them – fortunately all patients enrolled in this study tested HIV negative. In this study, histopathological examination of small bowel perforations was suggestive of typhoid fever in 76% Of the patients while 14% had features of non-specific inflammation. We were unable to obtain biopsy results for nine patients. These findings are in keeping with similar studies done by Neil et al;¹⁹ Nuhu Ali and Bata Mtaku Gali³ and Wani et al.⁶

Salmonella typhi was isolated in blood in only 15.0% of the patients. The majority (85%) of our patients came in as referrals from the neighbouring health units, possibly after having received antibiotics for several days and this may in part explain why 79% of the patients had negative blood cultures. Previous studies have reported that non traumatic SBP due to enteric fever is common^{3, 6, 19}. However, blood cultures that were positive for *E. coli* and *Klebsiella spp* were thought to be contamination resulting from haematogenous spread of bacteria from peritoneal fluid in patients with overwhelming peritonitis.

Widal test was not performed because a single Widal test is of little clinical relevance due to the number of cross reacting infections, including malaria²⁴. *Salmonella* isolates showed good antibiotic sensitivity to Ceftriaxone and Ciprofloxacin, followed by Gentamycin but resistance was observed with Chloramphenicol, Nalidixic acid, Ampicillin, Amoxycillin, Cotrimoxazole, Penicillin G, and Tetracycline.

Adult worms (*Ascaris lumbricoides*) were observed in the stool and peritoneal fluid of two patients. These patients had negative blood cultures and their histopathological picture was of a non-specific inflammatory process. It was difficult to know whether this was a coincidence or a cause of the perforation. Wani et al⁶ reported cases of ascariasis in the peritoneal cavity of 14 out of the 79 patients with non-traumatic small

bowel perforation – however, they thought that this was a sequel of the perforation and not the cause. Hani et al²² also reported one case of SBP due to hook worms.

Re-laparotomy was done in 4 patients with new perforations, 2 had anastomotic breakdown, and 2 for intra-abdominal abscesses. One patient had colostomy and ileostomy done after breakdown of his ileotransverse anastomosis at re-laparotomy. No cases of burst abdomen were reported because abdominal closure was done using tension sutures for all patients. Wound sepsis was observed in 25(28.7%) of the patients probably due to gross peritoneal contamination. The average length of hospital stay was 13 days and 10(11.5%) patients died mainly from overwhelming sepsis and severe electrolyte derangement.

The above findings can be extrapolated to explain the aetiology and clinical course of non-traumatic SBP in Uganda and possibly in other developing nations because patients enrolled in this study came from 15 districts in south western Uganda which was thought to be representative enough. Furthermore, doctors from other hospitals in the country have also expressed concern over the rising cases of small bowel perforation and the clinical course of their patients is similar to that exhibited by our patients.

Conclusions and Recommendations

Most cases of non-traumatic SBP in south western Uganda are associated with *Salmonella* infection and antibiotic therapy should be based on the sensitivity spectrum of local *S. typhi* strains.

Since typhoid is a preventable illness, a nationwide campaign should be conducted to eradicate the disease through mass education, provision of safe water, proper food handling and typhoid vaccination using the Vi and Ty21a vaccines.

Acknowledgement

Thanks to MUST and Deutscher Akademischer Austausch Dienst (DAAD) for the financial support. I am also grateful to all the staff members in the Department of Surgery at MUST.

References

1. Abatanga, B. Nimako, M. Amoah. Perforation of the gut in children as a result of enteric fever, a 5 years single institute review: *Annals of pediatric surgery* 2009; 5(1):1-10.
2. Lwatt. Free small bowel perforation in an indigenous population. *Int Surg.* 1988; 73(1): 50-3.
3. Nuhu, B. Mtaku. Causes and treatment outcome of perforation peritonitis in north-eastern Nigeria. *Surgical practice* 2010; 14(3): 92-96.
4. Rafiq, Y. Sagufta, T. Prindiville, et al. Intestinal perforation and peritonitis in AIDS: case series and review of the literature. *JK-Practitioner* 2004; 11(4): 248-256.
5. Uba, B. Chirdan, M. Ituen, et al. Typhoid intestinal perforation in children: a continuing scourge in a developing country. *Pediatric Surgery International* 2007; 23(1): 33-39.
6. Wani, Q. Fazl, A. Nadeem, et al. Non-traumatic terminal ileal perforation. *World Journal of emergency surgery* 2006; 1:7
7. Daley. Peritonitis and abdominal sepsis. (Accessed Mar 29 2011).
<http://emedicine.medscape.com/article/180234-overview#showall>.
8. Cheung, H. Chiu, C. Chung. Small bowel perforation after radiotherapy for cervical carcinoma. *Hong Kong Med J* 2003; 9(6):461-3.
9. Henry. Small Bowel Perforation: Causes, symptoms and treatment of small intestinal perforation. <http://www.suite101.com/content/small-bowel-perforation-a133456> (Accessed: 20th July 2009).
10. Catena, L. Ansaloni, F. Gazotti, et al. Gastrointestinal perforations following kidney transplantation. *Transplant Proc* 2008; 40(6):1895-6.
11. Gastrointestinal perforation - Wikipedia the free encyclopaedia.
http://www.en.wikipedia.org/wiki/Gastrointestinal_perforation (Accessed Mar 29 2011).
12. H. Akyildiz, A. Akcan, E. Sozuer, et al. Unusual causes of intestinal perforation and their surgical treatment. *Ulus Travma Acil Cerrahi Derg.* 2009; 15(6):579-83.

13. H. Wardhan, A. Gangopadhyay, G. Singhal. Intestinal perforation in children. Journal of paediatrics and child health 1989; 25(2): 99-100.
14. Intestinal Perforation: eMedicine General Surgery. <http://www.emedicine.medscape.com> › ... › General Surgery › Abdomen (Accessed Feb 24 2009).
15. Intestinal Perforation: [emedicine.medscape.com/article/195537-overview](http://www.emedicine.medscape.com/article/195537-overview). Available at <http://www.emedicine.medscape.com/article/195537-overview> (Accessed May 11 2011).
16. J. Kristie. Signs of a bowel perforation. Available at http://www.ehow.co.uk/about_5393322_signs-bowel-perforation.html. (Accessed: 11th May 2011).
17. K. Deniz, H. Ozseker, S. Balas, et al. Intestinal involvement in Wegener's granulomatosis. J Gastrointestin Liver Dis 2007; 16(3):329-31.
18. K. Nadkarni, S. Shetty, R. Kagzi, et al. Small bowel perforation. Arch surgery 1981; 116:53-7
19. K. Neil, S. Sodha, L. Lukwago, et al. A large outbreak of typhoid fever associated with a high rate of intestinal perforations in Kasere, Uganda, 2008-2009. Clinical Infectious Diseases 2012; 54:1091-9.
20. M. Birungi, K. Thembo. No Solution in Sight for Gut Perforation in Kasere/ Uganda Radio Network: <http://ugandaradionetwork.com/a/story.php?s=32795&PHPSESSID=a8acab647ee9d68f1acaad728330613d> (Accessed on April 11 2011).
21. M. King. Primary Surgery: Volume One: Non trauma. New York: Oxford University Press, Pg 535-538.
22. O. Hani, F. Ashraf, J. Sandhya, et al. Non-traumatic perforations of the small bowel. African Health Sciences 2008; 8(1): 36-39.
23. The daily monitor (17th /02/2011). Gut Perforation Disease Hits Kasere <http://allafrica.com/stories/201102210032.html>
24. World Health Organization. Background document: the diagnosis, treatment and prevention of typhoid fever. Communicable Disease Surveillance and Response 2003. Available at http://whqlibdoc.who.int/hq/2003/WHO_V&B_03.07.pdf.