

Spontaneous Neonatal Gastric Rupture: A Case Report**H. Getachew, P. Kidane**

Pediatrics Surgery Unit, Department of Surgery, College of health Sciences, Addis Ababa University

Correspondence to: Dr. Philipos Kidane, E-mail: philiposkidane@gmail.com

A case of Spontaneous Gastric rupture in a term neonate presented as an acute abdomen is presented below and the challenges faced in the diagnosis and subsequent management of this rare condition highlighted and available literature reviewed below.

Introduction

Gastric rupture in neonates is rare and when it occurs is serious and life-threatening^{1,2}. Since the report by Siebold³ in 1825 of a case of spontaneous rupture of the stomach in a newborn, attention has been given to this condition which was thought to be of rare occurrence. There has been a growing interest in the subject over the years with abundance of literature which has increased the number of reported cases to more than 400⁴. Most cases occur in premature neonates especially those who are put on mechanical ventilators and delay in diagnosis and early intervention cause significant morbidity and mortality.

We report a case of spontaneous gastric rupture in a term, appropriate for gestational age neonate who was treated successfully at our center so that clinicians working with this subset of neonates have a high index of suspicion so that prompt diagnosis and early operation can be performed which significantly improves the odds of survival.

Case report

This is a 4 days old female neonate born to a 36 years old Para VI lady at a gestational age of 40⁺⁶ weeks and was born in Saint Paul's Hospital, one of the referral hospitals in Addis Ababa. Onset of labor was spontaneous and later augmented and lasted for 21 hours and membrane was artificially ruptured after 6 hours of onset of labor and delivery was vaginal with the outcome of 3000gm weighing neonate with undocumented APGAR scores. Following birth she was diagnosed with Meconium Aspiration Syndrome after meconium was sucked out of her oropharynx after delivery and had respiratory distress. She was put on IV Ampicillin and Gentamycin and was later referred to Black Lion Hospital neonatal intensive care unit when she started to pass out coffee ground like vomitus and passed blood per rectum and also had associated abdominal distention but no bleeding from other sites.

Physical findings on arrival to our hospital include, respiratory distress with RR= 72/min, SpO₂=91% and her abdomen was grossly distended and was erythematous with hypoactive bowel sounds and initial Lab results revealed WBC=14,000/ul, HCT=50.3%, Hgb=18.3gm/dl, PLT=52,000/ul serum Na⁺=136, K⁺=4.1, Ionized Ca⁺⁺=1.26, RBS=71mg/dl, Blood group and RH= O^{neg}, Plain abdominal x-ray revealed distended bowel loops and she was admitted with the assessment of necrotizing enterocolitis and put on conservative management, with IV Ceftazidime and Vancomycin, maintenance iv fluids and NG tube decompression. Subsequently she was followed with the same management for one week in the NICU but her condition worsened with progressive abdominal distention and plain abdominal x-ray revealed pneumoperitoneum (Figure. 1) so it was decided to explore her with the impression of viscus perforation secondary to NEC. Upper transverse laparotomy was performed under the supportive therapy of fluid replacement and a whole blood for transfusion. Upon entering the peritoneal cavity gush of air came out and peritoneal cavity collapsed and the peritoneal cavity was filled with GI content mixed with blood. The greater omentum was eaten up and on the anterior wall of the stomach there was a 10 cm perforation along the long axis of the stomach from the cardia to the antrum with ragged margin which was necrotic and darkened (Fig 2 and 3); the rest of the hollow and solid viscera were thoroughly examined and there was no anomaly and the edges

of the perforation was trimmed and the perforation repaired with Vicryl 4-0 continuous inverting sutures in two layers and the peritoneal cavity thoroughly lavaged with warm normal saline and fascia closed with 00 vicryl continuous sutures and skin closed with interrupted vicryl 4-0 sutures.

She was kept in the NICU with nasogastric tube in place and on nil by mouth for 3 days post operatively and started with sips through the NG tube on her 4th postoperative day. And subsequently volume of feeds gradually increased and NG tube removed on her 5th post-operative day. On her 9th post-operative day she developed surgical site wound infection which was managed with wound care and antibiotics and discharged improved on her 17th post-operative day.

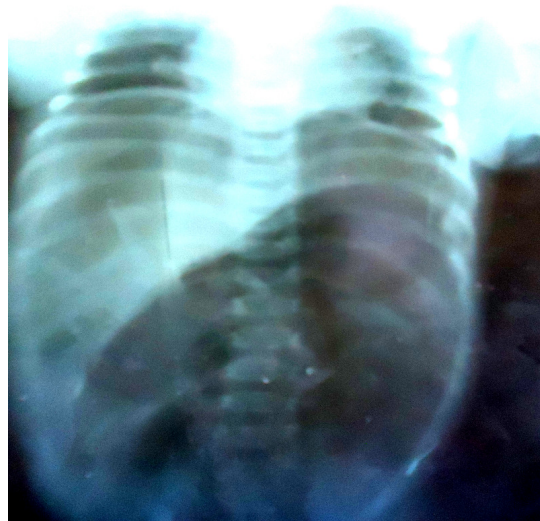


Figure 1. Plain Abdominal X-ray of the Neonate with Pneumoperitoneum

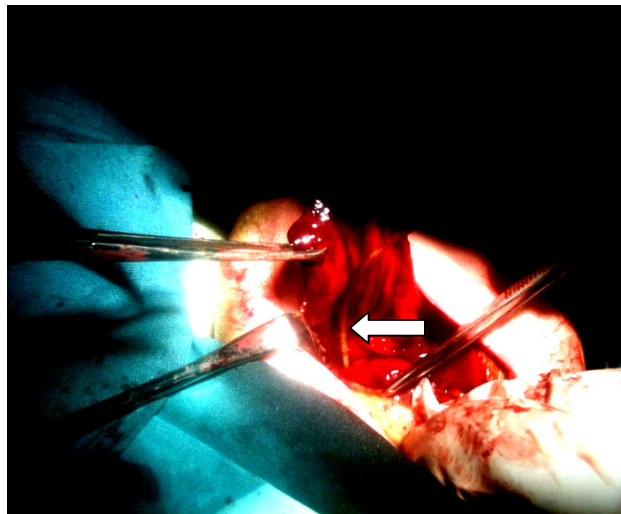


Figure 2. Ruptured Stomach with exposed NG tube seen (solid arrow).

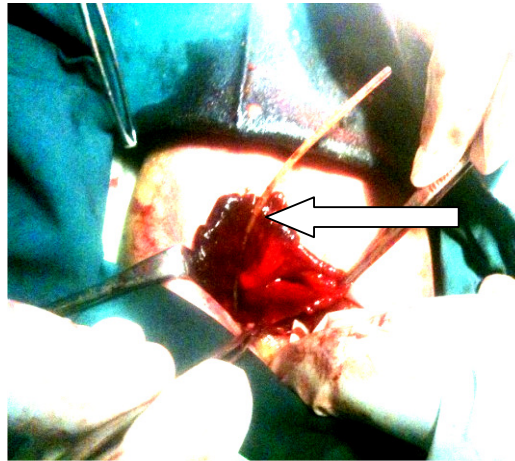


Figure 3. ruptured stomach with necrotic edge. Mucosa and NG tube seen (solid arrow).

Discussion

Three mechanisms have been proposed for stomach perforation in the neonatal age group, trauma, ischemic and spontaneous. The specific etiology of gastric perforation may be difficult to determine because neonates are too sick, most gastric perforations are due to iatrogenic trauma^{5,6}. The most common injury is caused by vigorous nasogastric or orogastric placement^{5,6}. Traumatic gastric perforation may develop as a result of severe gastric distension during bag mask resuscitation or mechanical ventilation for respiratory failure^{9,10}. Ischemic perforations are associated with extreme prematurity, sepsis and neonatal asphyxia.

Spontaneous gastric perforations have been reported in otherwise healthy infants, usually within the first week of life particularly between the first 2 and 7 days of life^{11, 12}. The term "spontaneous" suggests a cause separate from necrotizing enterocolitis, ischemia, and trauma from gastric intubation, distal intestinal obstruction or accidental insufflations of stomach during assisted ventilation. Although perinatal stress and prematurity are common associations, no predisposing factors can be identified in at least 20% of patients and the hypothesis is that spontaneous perforations are due to congenital defects in muscular wall of the stomach^{7, 8}. Signs and symptoms of gastric perforation are those of an acute abdominal catastrophe associated with sepsis and respiratory failure. Radiologic confirmation of massive pneumo-peritoneum is suggestive and represents surgical emergency and surgical repair consist of trimming of the edges, possibly and two layer closure of perforations. Postoperative vigorous supportive therapy with intravenous antibiotics, fluid therapy and NG tube decompression is needed.

Most important factors affecting survival appears to be interval between onset of symptoms and start of definitive therapy, extent of peritoneal contamination, degree of prematurity and severity of other consequence of asphyxia, mortality rates of gastric perforation could range between 45-48%^{13, 14, 15}.

References

1. Bayatpour M, Bernard L, McCune F, Bariel W. Spontaneous gastric rupture in the newborn. *Am J Surg* 1979; 137: 267-269.
2. Leon R.J., Krasna I.H. 'Spontaneous' gastric perforation: is it really spontaneous? *J Pediatric Surg* 2000; 35: 1066-1069
3. Siebold, A.E. Cited by Thelander H.E. Perforation of the Gastro-intestinal tract of the Newborn Infant. *Amer. J. Dis. Childhood*, 1939; 58:371
4. Charles H. Clark, Anthony Jean-Jacques, Abner St. Jean: Spontaneous Perforation of the Stomach in the Newborn. *Journal of the National Medical Association* 1973: 65: 1

5. Goosfeld J.L., Molinari F.M., Chaet M., et al : Gastrointestinal perforation and peritonitis in infants and children: Experience with 179 cases over ten years. *Surgery* 1996; 120: 650-656.
6. Kieswetter W.B. Spontaneous rupture of the stomach in the newborn. *Am J Dis Child* 1956; 91:162-167.
7. Herbert P.A. Congenital defection musculature of stomach with rupture in a newborn. *Acta Pathol*, 1943; 36:91.
8. Haddock G, Wesson D.E. Congenital anomalies. In: *Pediatric gastrointestinal Disease*. Ed by WA Walker, PR Durie, JR Hamilton, JA Walker-Smith, JB Watkins, 3rd ed, Canada, 2000 pp 379-386.
9. Holcomb G.W.III Survival after gastrointestinal perforation from esophageal atresia and tracheoesophageal fistula. *J Pediatr Surg* 1993; 28:1532-1535.
10. Houch WS, Griffin J.A. Spontaneous Lineas tears of the stomach in the newborn infant. *Ann Surg*, 1981; 193:763-768.
11. Ryckman F.C. Selected anomalies and intestinal obstruction. In: *Neonatal perinatal medicine diseases of the fetus and infant*. Ed by A Avery, AA Fanarof, J Richard, RJ Martin, 7th ed, USA, Mosby, 2002; p 1283, .
12. Tan C.E.L., Kielly E.M., Agrawal M., et al. Neonatal gastrointestinal perforation. *J Pediatr Surg* 1989; 24: 888-892.
13. Dillon P.W., Cilley R.E. Lesions of the stomach. In: *Pediatric surgery*. Ed by KW Ashcraft, JP Murphy, RJ Sharp. 3rd Ed, USA, WB Saunders Company, 2002 pp 396-397.
14. Goosfeld J.L., Molinari F.M., Chaet M., et al : Gastrointestinal perforation and peritonitis in infants and children: Experience with 179 cases over ten years. *Surgery* 1996; 120: 650-656.
15. Rosser S.B., Clark C.H., Elechi E.N. Spontaneous neonatal gastric perforation. *J Pediatr Surg* 1982; 17:390-394.