

## **Ureteroscopy in a Resource Limited Setting: The Tikur Anbessa General Specialized Hospital Experience in Addis Ababa, Ethiopia.**

**D. Andualem, L. Be-edde, T. Mulat, L. Samodi**

Addis Ababa University-School of Medicine, Department of Surgery

**Correspondence to:** Dr. D. Andualem, Email: andualemdb94@yahoo.com

**Background:** Ureteroscopy (URS) is defined as retrograde instrumentation performed with an endoscope passed through the lower urinary tract directly into the ureter and calyceal system. However, ureteroscopy has gradually become a major diagnostic and therapeutic technique for lesions of both the ureter and intrarenal collecting system. Complications of URS range from minor complications such as colic, fever and haematuria to major complications like ureteric perforation and avulsion

**Methods:** This was a cross sectional study of patients who underwent URS at TAGSH from 11<sup>th</sup> September 2010 to 10<sup>th</sup> September 2011. Medical records of patients were reviewed and data retrieved by a preset questionnaire. The clinical notes and imaging studies were examined. After the data was collected, it was analyzed using the statistical software SPSS version 16.

**Results:** The main indications for ureteroscopy in our study were ureteric stones (64.3%), ureteric stricture (7.1%), ureteric obstruction of unknown cause (11.9%) and others such as pelviureteric junction (PUJ) obstruction and non-excreting kidney (16.7%). At ureteroscopy, 38 (45.3%) patients had stone disease confirmed during ureteroscopy, 20 (23.9%) were diagnosed normal and 16 (19.1%) had ureteric stricture. Most patients 56 (66.7%) had no post-operative complications. The overall complication rate of the procedure was 33.3% (n=28). Fourteen (16.7%) patients had abdominal colic, 7 (8.3%) reported haematuria, 3 (3.6%) had post-operative fever while 4 (4.8%) patients had both colic and haematuria. Only a single (1.2%) patient had ureteric perforation.

**Conclusion:** Ureteroscopy is an indispensable diagnostic and interventional procedure. Our study shows we have a long ways to go to improve our therapeutic ureteroscopic ureteric stone lithotripsy. We can also conclude that ureteroscopy is a very safe procedure.

### **Introduction**

Ureteroscopy (URS) is defined as retrograde instrumentation performed with an endoscope passed through the lower urinary tract directly into the ureter and calyceal system<sup>1</sup>. Although it was first described in 1912, it was not routinely performed until the late 1970s<sup>2</sup>. However, ureteroscopy has gradually become a major technique for the diagnosis and treatment of lesions of both the ureter and intrarenal collecting system<sup>3</sup>.

The major therapeutic indications of ureteroscopy include urolithiasis, Ureteric strictures, pelviureteric junction (PUJ) obstruction, and ablation of transitional cell carcinoma and retrieval of migrated stones<sup>4</sup>. According to Segura ureteroscopic stone fragmentation and removal is the treatment of choice for managing ureteral stones, especially mid and distal ones<sup>5</sup>.

There are several types of lithotripter energy sources. These include electrohydraulic, mechanical, electromechanical, ultrasonic and laser energy sources. The miniaturization of ureteroscopes and introduction of the holmium (Ho: YAG) laser has improved stone free rates<sup>6</sup>. Several authors showed ureteral strictures can be treated by dilatation or endoscopic incision through a retrograde, antegrade or combined approach using rigid and/or flexible ureteroscopes. Overall rates of about 60% are reported, but these rates are influenced by the length of the stricture<sup>2</sup>. URS can also be used as a diagnostic procedure. It can be used in the evaluation of ureteric transitional cell carcinoma, filling defects and undiagnosed haematuria. Beginning the 1980s endourological approaches have been used to treat localized transitional cell carcinoma of the upper urinary tract in patients with contraindication to nephroureterectomy<sup>7</sup>. Ureteronoscopy performed to evaluate an upper urinary tract (UUT) filling defect greatly enhance diagnostic

accuracy. In addition to visualizing UUT, it offers opportunity to biopsy any lesion encountered, allowing histopathological confirmation<sup>8</sup>.

With widespread practice of URS, however, have come various incidents or complications and new solutions for prevention<sup>3</sup>. Complications of URS can range from minor complications such as colic, fever, haematuria to major complications like ureteric perforation and avulsion<sup>2, 9</sup>. In a review of the early Mayo Clinic experience, complications were reported in 20% of patients and included fever, failure to remove stone and ureteral injury<sup>9</sup>. Patients with same session bilateral URS have a significantly higher postoperative complication rate than those with unilateral<sup>10</sup>.

According to several reports with growing experience and better equipment, however, the safety of the procedure has increased<sup>3</sup>. Supporters of URS as the primary treatment for distal calculi claim that it is highly successful and minimally invasive in trained hands and has minimal morbidity<sup>11</sup>. Advances in instrument design, flexibility and reduced size have also reduced the rate of complications. The aim of this study was to identify the major indications, findings and encountered complications of URS in Tikur Anbessa General Specialized Hospital (TAGSH). TAGSH is the largest referral and teaching hospital in Ethiopia. Though URS is practiced in some private facilities, to the best of our knowledge it is the only public hospital where URS services are given. It is only a little over 10 years since URS is started to be practiced.

#### **Patients and materials**

This was a cross sectional study of patients who underwent URS at TAGSH from September 11, 2010 to September 10, 2011. Medical records of patients was reviewed and retrieved by a preset questionnaire. The clinical notes and imaging studies were examined. The clinical data retrieved includes demographic data, clinical presentation, operative findings and postoperative course. Other data reviewed are imaging studies such as plain abdominal X-ray (KUB), ultrasonography, intravenous urography (IVU), retrograde pyelography and renal function tests (blood urea nitrogen (BUN) and creatinine (Cr.)). We also went through operative findings and recommendations. All URS were done using semi rigid ureteroscopes of 8 and 9.5 Fr size. All patients with proximal, middle and distal ureteric stones were included. All URS were done under general anesthesia. After the data was collected, it was analyzed using the statistical software SPSS version 16. The study was approved by the institutional review board of the department of surgery, Addis Ababa University, school of medicine.

#### **Results**

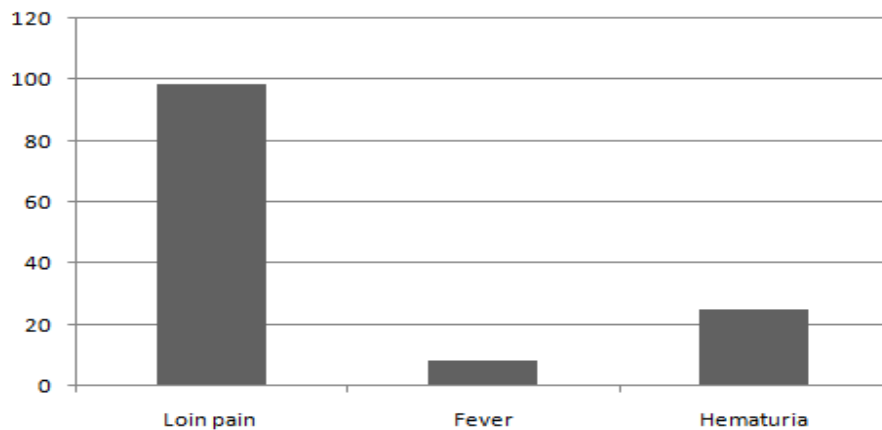
A total of 84 patients who underwent ureteroscopy were included in this study. Among these patients 47 (56%) were males while 37 (44%) were females. There were two peak age incidences in the 21 to 30 and the 41 to 50 age groups (Table 1). Loin pain was the most common presenting symptom in 83 (98.8%) of the patients, 21 (25%) presented with haematuria 21(25%) and 7 (8.3%) complained of fever (Figure 1). The most common clinical diagnosis was stone disease 54 (64.3%). Figure 2 shows the clinical and Ureteroscopic Diagnosis of Patients underwent ureteroscopy (n=84) Most 38 (45.3%) patients had stone disease during ureteroscopy while 20 (23.9%) were diagnosed normal and 16 (19.1%) ureteric stricture. Most patients 56 (66.7%) had no post-operative complications. Fourteen (16.7%) patients had abdominal colic while 7 (8.3%) patients reported haematuria.

Three patients had post-operative fever while 4 (4.8%) patients were found to have both colic and haematuria. Only a single patient had ureteric perforation (Figure 3). Out of the 38 patients with ureteric stones, complete stone extraction was done for 19 (50%) of patients (Table 2). Nine (23.7%) patients had only double J stenting while no other therapeutic ureteroscopy procedure was done for 6 (15.8%) patients. For 2 (5.3%) patients the stone was crushed and in 2 (5.3%) others stone was dislodged. Of the 38 stone

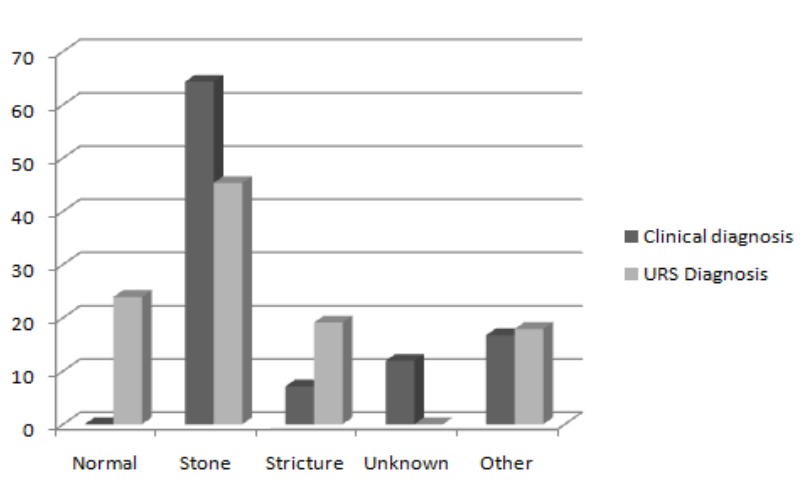
patients 24 (63.2%) were discharged after the ureteroscopy while 12 (31.5%) patients had to undergo other procedures and 2 (5.3%) patients for a repeat ureteroscopy.

**Table 1.** Age and Sex distribution of patients who underwent URS (n=84)

Description		Frequency	Percent	Cumulative frequency	Percent
Age	11-20	10	11.9	10	11.9
	21-30	25	29.8	35	41.7
	31-40	14	16.6	49	58.3
	41-50	25	29.8	74	88.2
	51-60	8	9.5	82	97.6
	>60	2	2.4	84	100
	Total	84	100		
Sex	Male	47	56	47	56
	Female	37	44	84	100
	Total	84	100		



**Figure 1.** Clinical Symptoms of Patients who Underwent Ureteroscopy (n=84)



**Figure 2.** Clinical and Ureteroscopic Diagnosis of Patients who Underwent Ureteroscopy (n=84)

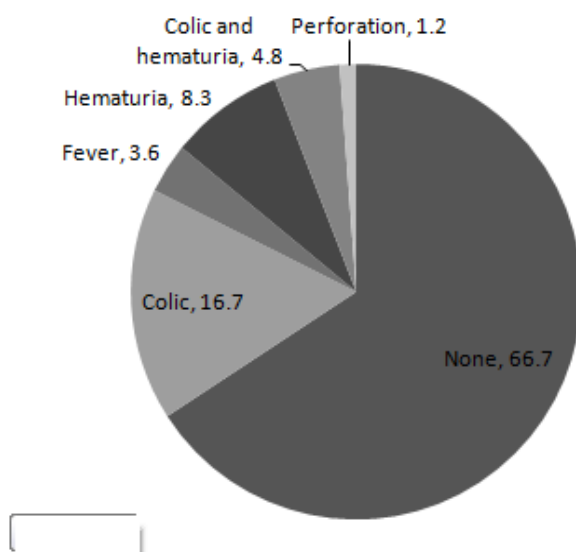


Figure 3. Complications of Patients who Underwent URS in Percentage (n=84)

Table 2. Therapeutic Procedures and Postoperative Recommendations of Patients who Underwent URS for ureteric stone

Procedure	Frequency	Percent	Post-operative recommendation	Frequency	Percent
None	6	15.8	Discharge	24	63.2
Only J stenting	9	23.7	Repeat URS	2	5.3
Stone extraction	19	50	ESWL	4	10.5
Stone crushing	2	5.3	Open stone removal	4	10.5
Proximal dislodging	2	5.3	Other	4	10.5
Total	38	100	Total	38	100

## Discussion

In this study the most common clinical presenting feature of patients is loin pain (98.8%). This is not surprising as the major pathologies in the ureter are obstructive conditions leading to intermittent ureteric contractions, hence, colic. However, a quarter of the patients have presented with haematuria. The main indications for ureteroscopy in our study were Ureteric stone 54 (64.3%), ureteric stricture 6 (7.1%), ureteric obstruction of unknown cause 10 (11.9%) and others 14 (16.7%) like Pelviureteric junction (PUJ) obstruction and non-excreting kidney.

The study showed a great discrepancy between clinical and ureteroscopic diagnosis. Twenty (23.9%) patients who had clinical indications for ureteroscopy had normal findings. Fifty four (64.3%) patients were clinically diagnosed to have ureteric stones but only 38 (45.3%) patients had stones on ureteroscopy. This also indicates that ureteroscopy is an important diagnostic procedure, in institutions which lack ideal set up of imaging techniques. Moreover, it was possible to diagnose ureteric stricture only in 6 (7.1%) patients clinically as judged by the treating surgeon. However, ureteroscopy revealed 16 (19.1%) patients had ureteric stricture which didn't allow the passage of 9 Fr. Ureteroscopes.

The overall complication rate of the procedure is 33.3 (n=28). Most of the complications are minor complications 27 (32.1%); colic 14 (16.7%) being the most common followed by haematuria 7 (8.3%). Major complication (ureteric perforation) occurred only in 1 (1.2%) patient. The rates of minor complications vary in different studies. Our finding is higher than most studies but it is similar with one European Study<sup>2, 3, 6, 12</sup>. The same studies show a similar major complications rate with our finding. The immediate stone extraction (stone free Rate) is 50% (n=19) which is much less than in other studies<sup>2, 6, 12</sup>. This could be due to lack of equipment, skill, supply and so on which necessitates further studies. However, obstruction was circumvented by double J stenting in 9 (23.7%), stone crushing in 2 (5.3%) and proximal stone dislodging in 2 (5.3%) patients, respectively. Twelve (31.5%) patients required other procedures to remove the stones.

### Conclusion

Ureteroscopy is an indispensable diagnostic and interventional procedure. Our study shows we have a long ways to go to improve our therapeutic ureteroscopic ureteric stone lithotripsy. We can also conclude that ureteroscopy is a safe procedure.

### References

1. Rajamahanthi s., Grasso M., Flexible ureteroscopy update: Indications, instrumentation and technical advances, Indian Journal of Urology, 2008; 24:532-537
2. Smith A., Smith's text book of Endourology, second edition, 2006
3. Gaevlete P., Complications of 2735 retrograde semirigid ureteroscopy procedures: A single center experience, Journal of Endourology, 2006, 20:179-185
4. Wein J., Campbell-Walsch urology, ninth edition,
5. Djaladat T., Uretral catheterization in uncomplicated ureterolithotripsy: A randomized, controlled trial, European urology, 2007, 52:836-841
6. Knoll T., Progress in management of Ureteric stones, EAU update series, 2005,3:44-50
7. Mugiya S., Retrograde endoscopic laser therapy for transitional cell carcinoma of the upper urinary tract, International journal of urology, 2003, 10:371-376
8. Matsumoto A., The usefulness of ureterorenoscopic examination in evaluation of upper tract disease, International journal of urology, 2006, 13:509-514.
9. Singal R., Secondary ureteroscopy: Results and management strategy at referral center, The journal of urology, 1998, 159:52-55
10. Watson J., Same session bilateral ureteroscopy is safe and efficacious, The journal of urology, 2011, 185:170-174
11. Turk T., A complication of ureteroscopy to in situ extracorporeal shockwave lithotripsy for treatment of ureteral calculi, The journal of urology, 1999, 161:45-47
12. Kuepeli B., What is the optimal treatment for lower ureteral stones larger than 1 cm?, International al journal of urology, 2000, 7:167-171