

Radiological Features and Postoperative Histopathologic Diagnosis of Intracranial Masses at Tikur Anbessa Specialized Hospital and MCM Hospital.

M. Tesfay¹, Y. Hawaz¹, G. Assefa¹, M. Abebe²

¹Department Of Radiology Addis Ababa University

² Department Of Surgery Addis Ababa University, Addis Ababa, Ethiopia

Correspondences to: Yohannes Hawaz Email: hawazyohannes@yahoo.com

Background: Intracranial mass lesions are common causes of neurological morbidity and are detectable by cranial imaging. Given the wide range of pathological processes that can present as intracranial mass lesions, the radiologist can limit the differential diagnosis to inform clinical decision-making. The main objective of this review was to analyze radiologic features and postoperative histopathology diagnosis of intracranial mass lesions.

Methods: A cross sectional study was conducted on 96 patients who underwent surgery for intracranial mass lesions at Tikur Anbessa Specialized Hospital (TASH) and Myungsung Christian Medical Center (MCM) in a period of 3 years (Feb 2009-Dec 2011). Patients were limited to those who had histopathologic result and either CT (n=67), MRI (n=14) scan report or both (n=15).

Results: Histopathologically confirmed intracranial masses constituted meningioma = 32 (39%), glioma =15 (18.3%), pituitary adenoma = 14 (17%), and tuberculoma = 6 (7.3%). The CT scan sensitivity, specificity, and accuracy in differentiating meningiomas from other intracranial masses, taking the first differential as most likely diagnosis, was 80%, 95% and 88.6% whereas for gliomas it was 71%, 85.7% and 83% respectively. The higher rate of meningiomas found in this study may result from surgeons bias toward preference of resection of extra axial tumors or longer survival of meningioma patients.

Conclusion: Meningiomas were the commonest histologically diagnosed intracranial mass lesions followed by glioma, but their prevalence may have been overestimated in this study because surgeons are more likely to resect them and confirm their diagnosis. Tuberculoma was the commonest non-tumor lesion. CT scan was more accurate, sensitive and specific in diagnosing benign than malignant masses.

Introduction

Intracranial mass lesions are important cause of neurological morbidity and a common indication for cranial imaging. Given the wide range of pathological processes that can present as intracranial mass lesions, the radiologist has an important role in limiting the differential diagnosis in an individual case in order to inform the clinical decision-making process¹.

Many diseases may produce mass effect and therefore qualify as a “mass” on CT scan and MRI followed by biopsy of these mass lesions may be required so that the pathologist can readily differentiate between neoplasia and nonneoplastic imitators²⁻⁴.

In USA overall incidence rate for primary brain tumors was 18.1 per 100 000 person-years with 2-, 5-, 10-, and 20-year observed survival rates of 62%, 54%, 45%, and 30%, respectively. On the basis of the sum of nonmalignant and averaged malignant estimates, the overall prevalence rate of individuals with a brain tumor was estimated to be 209.0 per 100 000 in 2004 and 221.8 per 100 000 in 2010⁵.

In Africa Primary intracranial tumours account for the majority, 70-80% of all intracranial tumours, with metastatic tumours accounting for the remaining 20-30%. The frequency of intracranial tumour increases with age, and metastatic tumours are most common in older age groups⁶.

The term “Intra-cranial mass lesion” is defined as any neoplasm, benign or malignant, primary or secondary, as well as any inflammatory or parasitic mass lying within the cranial cavity. The list also includes hematomas, different types of cysts, and vascular malformations. There is difference in different intracranial mass incidence in different countries⁷⁻¹⁰. Imaging appearances are important feature which help to classify intra-axial (in brain parenchyma) and extra-axial lesions and to list likely differential diagnosis⁽¹¹⁻¹⁴⁾.

In Ethiopia, the availability of advanced imaging modalities like CT and MRI are scarce compared to what is expected for the general population. It is also not surprising to see patients waiting for a long time before getting admitted for surgical care, hence most patients are admitted after the disease has advanced, and some are forced to seek referrals abroad¹⁵.

Methods and Materials

A retrospective study was done for patients with intracranial masses who had preoperative CT/MRI imaging report and postoperative histopathology result.

The study was conducted in TASH and MCM in Addis Ababa, Ethiopia, from Feb. 1, 2009-Dec 29, 2011. All neurosurgical Patients operated during the study period. Neurosurgical patients diagnosed to have intracranial mass lesion by either CT or MRI or both and who had a post operative specimen histopathology result in TASH and MCM during the study period.

A convenience sampling method was used. The log book of neurosurgical patients who underwent surgical procedures from Feb. 1, 2009 to Dec 29, 2011 was revised. Then card numbers of 388 patients with intracranial mass lesions was traced. Finally the charts of these patients were retrieved and the CT/MRI reports and histopathology result were checked out. Charts of 96 patients were found to fulfill the criteria i.e. patients had CT/MRI reports and histopathology results in their charts. Among the 96 patients 82 patients had biopsy proven diagnoses and the remaining 14 patients were reported as cysts both histopathologically and intra operatively. The CT/ MRI reports were reported by senior radiologists who were working in the government and private diagnostic centers. The study included patients in all age categories that came from all regions of the country. Patients with intracranial hematoma were excluded from the study. Patient cards with CT/MRI reports and histopathology results were picked out. Radiological first deferential was taken as most likely diagnosis when there are more than one differential diagnosis. Data collection was accomplished by using a structured questionnaire by the principal investigator. The questionnaires were filled by reviewing charts of selected patients for the study. The data was collected by the principal investigator based on the information listed on the questionnaire.

Informed consent was obtained from radiology department. Data collection was started after the formal letter was forwarded and permission obtained from the medical directors of the hospitals. The questions listed in the questionnaire were proved not to affect the morale and personality of the study subjects.

The confidentiality was ensured including by using code numbers instead of names of patients in the data collection format. A pretest was done to determine if any revisions or changes in the questionnaire needed. The collected data was checked out each day of the activity to ensure that all the information was properly recorded on the format. Collected data was edited and entered in to the computer and it was analyzed by the principal investigator using SPSS version 16 software. Finally it was presented using tables and graphs.

Results

The study population included 56 male and 40 female patients aged 1 to 86 with a mean age of 36 years (Table 1). The main clinical presentations on admission were headache in 66(68.7%), visual disturbance 26(28%), body weakness 20(20.8%), abnormal body movement 13(13.45%), vomiting 10(10.4%) and gait abnormality 6(6%) of patients. Other complaints and findings were facial or head swelling 5(5.2%), body weight gain 3 (3%), proptosis 2 (2%), aphasia 2 (2%), change in mentation.

Table 1. Distribution of intracranial Masses by Sex and Age at TAS and MCM Hospital, Addis Ababa, Ethiopia, from February 2009-Dec ember 2011.

| Histopathologic Diagnosis | | Sex | | | Age(years) | |
|------------------------------|------------------------------------|-----|----|----------|------------|---------|
| | | M | F | Subtotal | Mean (±SD) | Min-Max |
| Meningioma | Meningioma (grade unspecified) | 2 | 5 | 7 | 37(8) | 20-45 |
| | Meningioma(WHO G-I) | 14 | 7 | 21 | 46(14) | 24-80 |
| | Meningioma(WHO G-II) | 1 | 3 | 4 | 39(18) | 13-51 |
| | Subtotal | 17 | 15 | 32 | 43(14) | 13-80 |
| Glioma | Astrocytoma WHO G-III (anaplastic) | 1 | 1 | 2 | 43(10) | 36-50 |
| | Astrocytoma WHO G-IV (GBM) | 2 | 1 | 3 | 36(20) | 14-50 |
| | Astrocytoma(WHO G-I) | 2 | 1 | 3 | 19(2) | 18-21 |
| | Astrocytoma(WHO G-II) | 1 | 2 | 3 | 37(21) | 13-50 |
| | Ependymoma | 1 | 1 | 2 | 19 | 19 |
| | Oligodendriocytoma | 1 | | 1 | 21 | 21 |
| | Oligodendrioglioma | | 1 | 1 | 45 | 45 |
| | Subtotal | 8 | 7 | 15 | 31(15) | 13-50 |
| Pituitary adenoma | | 11 | 3 | 14 | 39(11) | 19-53 |
| Infections | Pyogenic abscess | 2 | | 2 | 16(13) | 6-25 |
| | Tuberculoma | 4 | 2 | 6 | 25(20) | 12-65 |
| | Subtotal | 6 | 2 | 8 | 23(18) | 6-65 |
| Haemangioblastoma | | 2 | 1 | 3 | 35(5) | 30-40 |
| Metastases | | 1 | 2 | 3 | 48(10) | 40-60 |
| Glomus tumor | Glomoangioma | 1 | | 1 | 28 | 28 |
| | Glomus tumor | | 1 | | 18 | 18 |
| Cavernous haemangioma | | 1 | | | 18 | 18 |
| Schwannoma | | 1 | | | 28 | 28 |
| Haemangio pericytoma | | | 1 | | 38 | 38 |
| Osteosarcoma | | | 1 | | 18 | 18 |
| Plasmacytoma | | 1 | | | 20 | 20 |
| Cystic masses | | 7 | 7 | | 33(24) | 1-86 |

NB: Cystic masses were reported either as cystic or intraoperatively described as cysts.

The imaging modalities used to evaluate the intracranial masses were CT 67(67.8%), MRI 14(14.6%), and both CT and MRI 15(15.6%). Regarding the location of the intracranial masses, the majority 53(57.6%) were commented as extra-axial masses (the two false positives were

gliomas), 34 (37%) were intra-axial masses (the two false positives were meningiomas) and in 5(5.4%) cases had difficulty to localize lesions (3 meningiomas, 1 glioma and 1 metastasis). Among the intra-axial masses 23 (67.6%), and 11(32.4%) were located in the supratentorial and infratentorial compartments, respectively (Figure 1).

Number of lesions were mentioned in 92 patients and all the masses were solitary among this one intra-axial mass (GBM) and another mass with undetermined location (CT diagnosis was lymphoma and pathology result turned out to be meningioma) crossed the mid line. The size of the masses was mentioned in 86 patients and mass size ranged from 1cm to 12cm (mean size 5.4cm). CT demonstrated 29 hypodense, 25 hyperdense, 10 isodense and 15 heterogeneous density intracranial masses (Tables 2 and 3). MRI reports of 21 patients were revised and all reports documented the intensities of the masses on T1W and T2W MRI images and FLAIR sequence intensities of 4 masses but no diffusion weighted MRI intensity report was mentioned (Table 2).

Overall post-contrast enhancement was seen in 77(83.6%) cases of intracranial masses. Of which 36 homogenous enhancement, 19 heterogeneous enhancement, 6 enhancement of solid component, and 15 ring enhancement patterns were documented (Table 4). Perilesional oedema mass effect on the ventricles and herniation were described in 45(49%), 52(56.5%), and 40(44%) cases respectively. Types of herniations were: 32 subfalcine, 6 uncal and 1 tonsillar.

Among the 96 patients who underwent surgical procedures (for biopsy or for resection of masses) the histopathology diagnosis of intracranial masses were confirmed in 82(85.3%), and in the remaining cases specimens were reported as no malignant cells or cystic and all these masses were mentioned cystic on the operative note. The histopathology confirmed intracranial masses constituted meningioma 32(39%), glioma 15(18.3%), pituitary adenoma 14(17%), tuberculoma 6(7.3%), haemangioblastomas 3(3.3%), metastases 3(3.3%), pyogenic abscesses 2(2.4%), glomus tumor 2(2.4%), schwannoma, 1(1.2%), cavernous haemangioma 1(1.2%), haemangiopericytoma 1(1.2%), osteosarcoma 1(1.2%), and plasmacytoma 1(1.2%)

Meningiomas: In this study meningiomas were 32(39%) and were the most common tumours among the intracranial masses. According to the histopathologic reports, 21(65.6%) patients had grade I meningiomas, 4(12.5%) had grade II and in case of the remaining 7(21.9%), histopathology grade was not documented. Males were 17(53.1%) and 15(46.7%) were females. The age distribution ranged between 13 to 80 years with a mean age of 43 years. The size of masses varied between 2cm and 10.5cm (mean 5.8cm). All the imaged patients had solitary masses. Regarding the imaging modalities of meningioma patients, 24 patients with CT, 5 patients with MRI and 3 patients with both CT and MRI were included in the study. Specific locations of the masses were mentioned in 28 cases, namely cerebral convexity 7, sphenoid wing 6, falx and parasagittal 7, sellar/suprasellar/parasellar 3, posterior fossa 1 and in four cases there were ambiguity which were later intraoperatively determined to be extra axial (2 cerebral convexity, 1 parasagittal and 1 olfactory groove) (Figure 2). Among the 23 cases that had CT density described, 17 (74%) was hyperdense, 3 (13%) was heterogeneous, was hypodense in 2 (8.7%) and isodense in 1(4.3%). Cystic or necrotic changes were reported in 3(13%) cases. Calcification and bone involvement were seen in 6(26%) and 7(30%) of cases respectively.

Seven patients had documented MRI report and the signal intensities of the masses were; On T1W MRI images, 5(71.4%) were isointense, 2 (28.6%) were hypointense and on T2W MRI images, 1(12.5%) was hyperintense, 3(42.9%) were isointense, 3(42.9%) were heterogeneous and FLAIR sequence were performed for four cases and 2(50%) showed suppression on FLAIR. Post contrast enhancement was seen in all masses both on MRI and CT reports. The degree of

enhancement were intense in the majority of cases 24(85.7%), moderate in 3 (10.3%), mild in 1(3%) and the pattern of enhancement were reported as intense in 85.7%, heterogeneous in 3(10.3%) and thick ring enhancement in 1(3%) cases. Perilesional edema was reported in 17(60.7%) and the registered degree of perilesional edema in 15 cases showed 5 mild, 6 moderate and 4 sever perilesional edema. Mass effect on the ventricles was seen in 15 (53.6%) cases and mid line shift was noted in 15(53.6%) cases. The sensitivity, specificity, and accuracy of CT in diagnosing meningioma in this study was 80%, 95% and 88.6% respectively whereas for MRI, 80%, 96% and 93% respectively.

Brain gliomas were the second common intracranial mass seen in this study was brain glioma which accounted for 15 (15.6%) of all intracranial masses. Regarding the histopathology subtypes 3(20%) patients had WHO grade I astrocytoma , 3(20%) patients had grade II astrocytoma , 2(13.3%) patients had WHO grade III(anaplastic Astrocytoma) , 3(20%) patients had WHO grade IV astrocytoma, 2(13.3%) patients had ependymoma, and 2(13.3%) patients had oligodendrioglioma/oligodendriocytoma. The sex distribution was 8(53.3%) males and 7(46.7%) females

The age of occurrence ranged between13 to 50 years (mean age of 31 years). The mean age of patient was younger in WHO grade I and grade II gliomas (28 years) than WHO grade III and IV gliomas (39 year). Size of masses ranged from 3.8cm to 8cm (mean 5.96cm). All the imaged patients had solitary masses and only one mass found to cross the mid line.

Regarding the imaging modalities, 10 patients with CT, 2 patients with MRI and 3 patients with both CT and MRI were included in the study.12(80%) masses were intra axial and 2(13.3%) were extra axial (intra ventricular) and 1(6.7)% was undetermined location .Regarding to compartmental location, 13(86.6%) were supratentorial and 2(13.3) were infratentorial. CT density was commented for 13 cases, 6(46.2%) heterogeneous, 4(30.7%) hypodense, 2 (15.3%) hyperdense, 1(7.7%) isodense masses. Calcification was seen in 4 cases; purely cystic mass, cystic with solid component /nodule, and cystic or necrotic change were reported one case each.

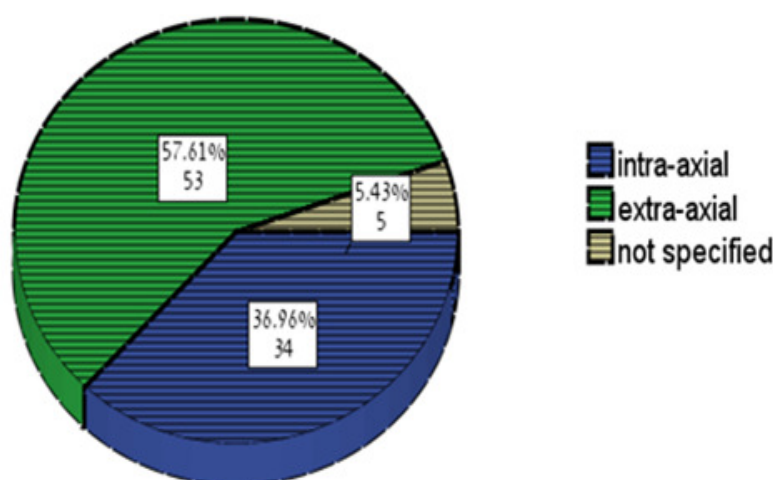


Figure 1. Distribution of intracranial masses by location at TASH and MCM Hospital , Addis Ababa, Ethiopia, from Feb 1, 2009-Dec 29, 2011.

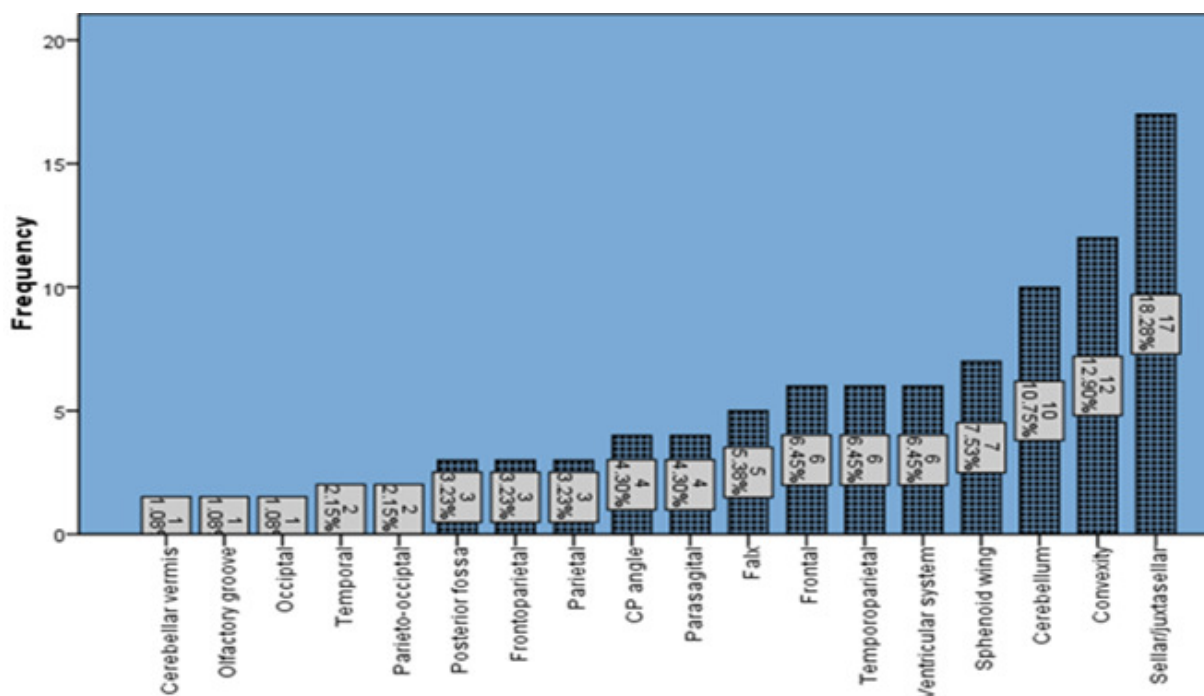


Figure 2. Distribution of intracranial masses by specific location at TASH and MCM Hospital, Addis Ababa, Ethiopia, from Feb 1, 2009-Dec 29, 2011.

MRI report of 4 patients showed 2 hypointense and 2 heterogeneous signal intensity masses on T1W MRI images and 2 hyperintense and 2 heterogeneous intensity masses on T2 W MRI images. FLAIR sequence was included for one case and no suppression was seen. Perilesional edema was reported in 13(92.3%) of masses, (5 mild, 2 moderate and 6 severe perilesional edema). Mass effect on the ventricles was seen in all cases and mid line shift was seen in 12 cases. The sensitivity, specificity, and accuracy of CT in diagnosing glioma in this study was 71%, 85.7% and 83% respectively and for MRI, 100%, 92.6% and 93.5% respectively.

Pituitary adenomas

Pituitary adenomas formed the third most frequent histopathology type and it constituted 14(14.6%) of all studied intracranial masses. among these 11 were males and 3 were females, the mean age of occurrence was 39 year (19-53 years). The mean size of the lesions was 4.1cm (2.9-5cm).

The imaging modalities performed were, 6 CT, 5 MRI and both 3 CT and MRI. The CT findings were 3 isodense, 3 hyperdense, and 3 heterogeneous density pituitary adenomas. The lesions were described as Sellar /suprasellar masses 10 and 4 parasellar masses. 4 cases show solid with cystic changes and one case was reported to have hemorrhagic changes postoperatively. MRI reports of 4 patients showed 3 isointense and 1 heterogeneous intensity masses on T1W MRI images and 2 isointense, 1 hyperintense and 1 heterogeneous intensity masses on T2 W MRI images. Post contrast enhancement of 12 patients was documented as moderate enhancement 9, intense enhancement 2, and 1 faint. Majority (8) had homogenous enhancement and 3 had heterogeneous enhancements. Perilesional edema was seen in one pituitary adenoma. The sensitivity, specificity, and accuracy of CT and MRI in this study in

differentiating pituitary adenoma from other intracranial masses were 100%, 95.4% and 95.8% respectively.

Brain Infections were seen in 6 male patients and 2 female patients. Two cases had pyogenic abscess and 6 cases had tuberculoma. All the masses were solitary and they were situated 5 supratentorially and 3 infratentorially.

Pyogenic abscesses were seen in a 6 year and 25 year old patients which were measured 3cm and 6.5cm in size. Pattern of enhancement was thin smooth ring enhancement. In both cases the masses were hypodense with mild and moderate perilesional edemas. One case caused mid line shift and mass effect on the ventricles.

Tuberculomas were reported in 4 male and 2 female patients. The mean age of patients was 25year (12-65 year) and the average size of the masses was 5.43 cm(3-8cm).The lesions were 3hypodense, 1isodense, and 1 heterogeneous in density and one case showed calcification. Four of these cases showed ring enhancement and 1 case showed heterogeneous enhancement. Five cases showed mass effect on the ventricles and three cases mid line shift. The sensitivity, specificity, and accuracy of CT in this study in diagnosing infections were 50%, 93.7% and 88.8% respectively.

Haemangioblastomas were diagnosed in two males and one female. The average age of

Table 2.CT Scan and MRI findings of intracranial masses at TASH and MCM Hospital, Addis Ababa, Ethiopia, from Feb 1, 2009-Dec 29, 2011.

| Imaging modalities and imaging findings | Histopathologic diagnosis and intra operative remarks | Meningioma | Glioma | Cavernous haemangioma | Glomus tumor | Haemangioblastoma | Haemangiopericytoma | Infections | Metastases | Osteosarcoma | Schwannoma | Pituitary adenoma | Plasmacytoma | Cystic |
|---|---|------------|--------|-----------------------|--------------|-------------------|---------------------|------------|------------|--------------|------------|-------------------|--------------|--------|
| CT density | hypodense | 2 | 4 | | 1 | 3 | | 5 | 2 | | | | | 12 |
| | isodense | 1 | 1 | | 1 | | | 1 | 1 | | 1 | 3 | | |
| | hyperdense | 17 | 2 | | | | | 1 | | | | 3 | | 2 |
| | heterogeneous | 3 | 6 | | | | 1 | 1 | | 1 | | 3 | | |
| T1 MRI signal | Hyperintense | | | | | | | | | | | | | 1 |
| | Hypointense | 2 | 2 | 1 | | 1 | | | | | | | | 2 |
| | Isointense | 5 | | | | 1 | | | | | | 3 | | |
| | Heterogenous | | 2 | | | | | | | | | 1 | | |
| T2 MRI signal | hyperintense | 1 | 2 | | | 2 | | | | | | 1 | | 2 |
| | hypointense | | | | | | | | | | | | | |
| | isointense | 3 | | | | | | | | | | 2 | | 1 |
| | heterogenous | 3 | 2 | 1 | | | | | | | | 1 | | |
| FLAIR | Yes | 2 | | | | | | | | | | | | |
| | No | | 1 | | | | | | | | | | | 1 |

occurrence was 35 years (30-40years) and the average size of the masses was 4.91cm (3.6-6.4cm) and all were located infratentorially. Three of haemangioblastomas patients' lesion were hypodense on CT scan and they were cystic with solid components. Two of the cases showed mild perilesional edema. Both showed intense enhancement of the solid component and one additionally showed thin ring enhancement. Herniation and mass effect were seen in two cases. Three cases of metastases were noticed in one male and two female patients with mean age of 49year (40-60). All these masses were misdiagnosed on CT scan report (false negatives). The average size of the masses was 4.5cm (40-60years). CT density of three lesions showed one isodense and two hypodense masses. Two of these show ring enhancement. Two supratentorial lesions were located one in the parietal and the other in the parasagittal regions.

Three of the masses had perilesional edema (two moderate and one severe) and two of these had mass effect on the ventricles.

Table 3. Components of intracranial lesions on CT scan at TASH and MCM Hospital, Addis Ababa, Ethiopia, from Feb 1, 2009-Dec 29, 2011.

| Intracranial Mass | Component of lesions as to CT | | | |
|--------------------------|-------------------------------|-----------------------------|---------------|---------------------------|
| | purely cystic | cystic with solid component | calcification | solid with cystic changes |
| | Count | Count | Count | Count |
| Glioma | 1 | 1 | 4 | 1 |
| Glomus tumor | | | | |
| Haemangioblastoma | | 3 | | |
| Tuberculoma | | | 1 | |
| Meningioma | | | 6 | 3 |
| Metastases | | | | 1 |
| Osteosarcoma | | | | |
| Pituitary adenoma | | | | 4 |
| Plasmacytoma | | | | |
| Total | 1 | 4 | 11 | 9 |

Others

The remaining pathology confirmed cases were: 2 (2.4%) glomus tumor, 1(1.2%) each of schwannoma, cavernous haemangioma, haemangiopericytoma, osteosarcoma and plasmacytoma. These lesions were described on the operative note as cystic. These cystic lesions were seen in 7 female and 7 male patients. The mean age was to be 33 year (1-86 years). Mean size of lesions was 5.24cm (1cm-10cm). Most of the lesions were extra-axial (57%) compared to the intra-axial lesions (43%). The CT density of most masses was hypodense except 2 cases which had hyperdense density. Of this 7 were described purely cystic and 3 were cystic with solid components. MRI of 3 patients showed: 1 hyperintense, 2 hypo intense masses on T1 MRI images and 2 hyperintense and 1 isointense on T2W MRI. Postcontrast enhancement was seen

in 5 patients i.e. ring enhancement in 2 cases and enhancement of the solid components in 3 cases. Perilesional edema was seen only in one case (see table 4). Mass effect on the ventricles was noticed in 9 cases and herniations in 5 cases. Bone sclerosis was seen in one case. The list of the cystic lesions included: Arachnoid cyst, dandywalker malformation, colloid cyst, and hydatid cyst.

Table 4. pattern of enhancement of intracranial masses at TASH and MCM Hospital, Addis Ababa, Ethiopia, from Feb 1, 2009-Dec 29, 2011.

| Histopathologic diagnosis | Pattern enhancement | | | | |
|---------------------------|---------------------|--------------|--------------------------------|---------------------|-----------|
| | Homogenous | Heterogenous | enhancement of solid component | Ring of enhancement | Total |
| | Count | Count | Count | Count | count |
| Meningioma | 24 | 3 | | 1 | 28 |
| Glioma | | 8 | 1 | 4 | 13 |
| Pituitary adenoma | 8 | 3 | | | 11 |
| Infections | | 1 | | 6 | 7 |
| Metastases | | 1 | | 2 | 3 |
| Cavernous haemangioma | | 1 | | | 1 |
| Schwannoma | 1 | | | | 1 |
| Glomus tumor | 2 | | | | 2 |
| Haemangioblastoma | | | 2 | | 2 |
| Haemangiopericytoma | | 1 | | | 1 |
| Osteosarcoma | | 1 | | | 1 |
| Plasmacytoma | 1 | | | | 1 |
| Cystic masses | | | 3 | 2 | 5 |
| TOTAL | 36 | 19 | 6 | 15 | 76 |

Discussion

In our study meningioma was the intracranial mass of highest frequency 32(39%), followed by glioma 15 (18.3%), pituitary adenoma 14(17%) and tuberculoma 6(7.3%). In other studies gliomatous tumours are the most common^(9,10). From this it is possible to deduce that patients with better prognosis (benign meningioma etc) either stay longer or come with still resectable mass than patients with worst prognosis. It was stated also that modern neurosurgery service and practice was not well developed in Ethiopia⁽¹⁵⁾. Thus it is obvious that neurosurgeons

prefer to operate superficial masses (like meningioma) to deep sited lesions. But still further study may be needed to explain it.

A study done in South Africa, meningioma was found to occur in 71% females and 29% males with a mean age of 47 years. In the contrary similar study in Ethiopia showed male predilection (male to female ratio were 1.2:1) and the age of occurrence were from 21-57 yrs (mean age of 49.3 +/- 10 yrs.). In this series in contradiction to other studies done outside Ethiopia, meningioma showed a slight preference to males¹⁷ (53.1%) than females. Again this could be an evidence that males are surviving meningioma better than females or males had better access to health services in Ethiopia.

The typical meningioma is a homogeneous, hemispheric, markedly homogeneously enhancing extra axial mass located over the cerebral convexity, in the parasagittal region, or arising from the sphenoid wing. Meningiomas may originate in unexpected locations. Unusual imaging features such as large meningeal cysts and ring enhancement may be seen. Meningiomas are characteristically hypointense to isointense with T1-weighted pulse sequences and isointense to hyperintense with T2-weighted pulse sequences. Mild to moderate intraaxial vasogenic edema is also seen around meningioma in up to 75% of cases¹³ but edema was seen in 13% of patients in our study.

The commonest locations of meningiomas in our study were cerebral convexity and falx/ parasagittal accounting for 7(25%). The lesions were solitary (all), most were hyper dense (74%) and some showed calcification and bony involvement in 6(26%) and 7(30%) of cases respectively. The degree of enhancement was intense and homogenous in the majority of cases 24(85.7%). majority of the cases were isointense on T1W MRI and variable on T2W MRI. Perilesional edema was reported in 17(60.7%) of meningiomas. Ring enhancing olfactory groove meningioma was also noted. These findings were similar to other research findings^{11,13}.

Study underwent by department of Neurology, Aga Khan University, Pakistan. One hundred patients (43 men) were identified. The age range was 1 to 75 years (mean = 30 years). The diameter of these enhancing lesions ranged from 1 mm to 5 cm. Lesions > 1 cm showed varied enhancement, including irregular shapes, ringlike shapes, open rings, and lobular patterns. Target like lesions were seen in only 2 patients. Other features included cortical and subcortical infarcts (12 patients), calcification (10% of lesions), edema (33 patients), mass effect, and/or midline shift (18 patients) ⁽¹⁶⁾. There is similarity of size and enhancement pattern of tuberculoma with our study.

Haemangioblastoma and tuberculoma were the commonest infratentorial intra axial lesions. The average age of occurrence of haemangioblastomas was 35 years (30-40years) and the average size of the masses was 4.91cm (3.6-6.4cm) and all were located infratentorially. Three of the cases were hypodense on CT scan and they were cystic with solid components. MRI of 3 patients showed: 1 hyperintense, 2 hypointense on T1 MRI and 2 hyperintense and 1 isointense on T2W MRI. These characteristics were also seen in other studies.

Three cases of metastases which were all false negative on preoperative imaging were noticed in one male and two female patients with mean age of 49year (40-60). The average size of the masses was 4.5cm (40-60years). CT density showed two hypodense and one isodense. Two of these show ring enhancement. Two were supratentorial and the other was infratentorial. Three of the masses had perilesional edema (two moderate and one sever) and two of these had mass effect on the ventricles.

Conclusion and Recommendation

Meningiomas were the commonest histologically diagnosed intracranial mass lesions followed by glioma, but their prevalence may have been overestimated in this study because surgeons are more likely to resect them and confirm their diagnosis. Tuberculoma was the commonest non-tumor lesion. CT scan was more accurate, sensitive and specific in diagnosing benign than malignant masses.

Perilesional edema of varying degree is seen in meningioma (extra axial mass) which is also a feature of gliomas (more frequent in high grade gliomas), metastases and infections.

Different studies show that advanced CT scan and MRI machines help to better characterize and diagnose intracranial masses which matters the treatment plan and outcome. As seen in this study, most MRI reports include only T1 with or without contrast and T2 images; other MRI sequences were rarely included. So preparing best protocol and use of different sequences is important for better characterization of masses. In addition, promoting continuous medical education for the radiologists and radiology coworkers would be critical to build up better radiology service in Ethiopia. Finally, further series of similar studies in a more intensified way are recommended to manipulate them for the general population.

References

1. Carter, R. and Pretorius, P. The use of CT and MRI in the characterization of intracranial mass lesions, *The British Institute of Radiology* 2007; 19:173-184.
2. Brant, William E., *Fundamentals of Diagnostic Radiology, introduction to brain imaging*, 3rd Edition, 2007; 52-54.
3. Cunliffe, Clare H. Fische I. Monoky D. et al: Intracranial Lesions Mimicking Neoplasms, *Arch Pathol Lab Med* 2009;133:101-123.
4. Smithies, R. and Montanera, W. *Neuroradiology, Brain Tumor: systematic approach, the radiology assistant*, 2008 . Retrieved from <http://www.radiologyassistant.nl>
5. Porter KR, McCarthy BJ, Freels S, Kim Y, Davis FG. Prevalence estimates for primary brain tumors in the United States by age, gender, behavior, and histology. *Neuro Oncol.* Jun 2010; 12(6):520-7.
6. William ,H. *Neurology in Africa, intracranial tumors*, Kilimanjaro Christian Medical Centre, Moshi, Kilimanjaro,Tanzania, 2012, 367-379.
7. Alabedeen, Z. Jamjoom, B. Pattern of intracranial space-occupying lesions: The experience of the king Khalid university hospital, *Annals of Saudi Medicine*, 1989, 9(1): 3-10.
8. Butt E. Khan, S. Chaudrhy N. and Qureshi R. intra-cranial space occupying lesions a morphological analysis, *biomedical*, jan. – jun, 2005, 21:31-35.
9. Senai, M. Aghaei M, Jalali A, Shakiba M, Evaluation of CT Scan and MRI Findings of Pathologically Proved Gliomas in an Iranian Population, *IJCP*, Autumn 2008, 4: 179-182.
10. Garg RK, Sinha MK, Multiple ring-enhancing lesions of the brain, *journal of post graduate study, India*, 2010, 56:307-316.
11. Buetow, P. et al, Typical, Atypical, and Misleading Features in Meningioma, *RadioGraphics* 1991; 11:1087-1 106.
12. Getachew Assefa, Senait Ashenafi, Tadios Munie , Meningiomas: clinical correlates, skull x-ray, CT and pathological evaluations, *Ethiop Med J.* Jul 2006; 44 (3):263-7 .
13. Fynn, E. Khan, N. Ojo, A.: Meningioma: a review of 52 cases, *SA Journal of Radiology*, 2004, 3-5.
14. Johnson B. *MR of CNS Tumors & Tumor Mimics*, advanced MRI –from head to toe, 2002, 1-9.

15. Abebe, M. Munie, T. Lende ,G, Bekele, A. Pattern of Neurosurgical Procedures in Ethiopia: Experience from Two Major Neurosurgical Centres in Addis Ababa, East and Central African Journal of Surgery, March/April, 2011, 16: 104-110.
16. Mohammad W. Bhojo, A. Mahesh, K.: Brain CT and MRI Findings in 100 Consecutive Patients with Intracranial Tuberculoma, July 2003, 13:240-247.