

Midline or Retroperitoneal Approach in Operating on a Retroperitoneal Tumour: A Surgical Dilemma.

A.H. Azhar, M.N.G. Rahman

Urology Unit, Department of Surgery, School of Medical Sciences,
Universiti Sains Malaysia, Kubang Kerian, Kelantan.

Hospital Universiti Sains Malaysia, Kubang Kerian, Kelantan

Corresponding to: Dr Azhar bin Amir Hamzah, Email: drazhar786@hotmail.com.

Retroperitoneal tumors are rare form of tumors arising from the retroperitoneal space and account for 10-15% of soft tissue sarcoma.^{1,2} Liposarcoma represent 0.1% of all cancers³ and arise mostly from the mesenchyme usually located in muscles, fat and connective tissue.⁴ It is a high grade tumor with high propensity for recurrence.¹ 80% of patients present with asymptomatic abdominal distension in their 5th - 6th decade of life.⁴ Liposarcoma tend to present as a huge mass posing a diagnostic and therapeutic dilemma especially with regards to its position and surgical approach.¹

Case Report

We present a 64 years old man with one year history of progressive abdominal distension and rapid increase in size of 3 months prior to presentation. He lost 20kg in 4 months. He had no history of jaundice or altered bowel habit. He smoked for thirty years during his youthful days in the army. General examination was not remarkable. He had an abdominal mass of 10x8x6cm in the left flank, no hepatosplenomegaly. Abdominal ultrasound showed a mass of 18.8cm on the left flank extending into the left iliac fossa with bilateral mild hydronephrosis. CT scan (Figure 1) showed a 32.3x11.6x21.3cm multiseptated retroperitoneal mass extending from the left hemidiaphragm to the pelvis (S₂-S₃). CT angiography showed minimal blood supply from the IMA not warranting embolization.

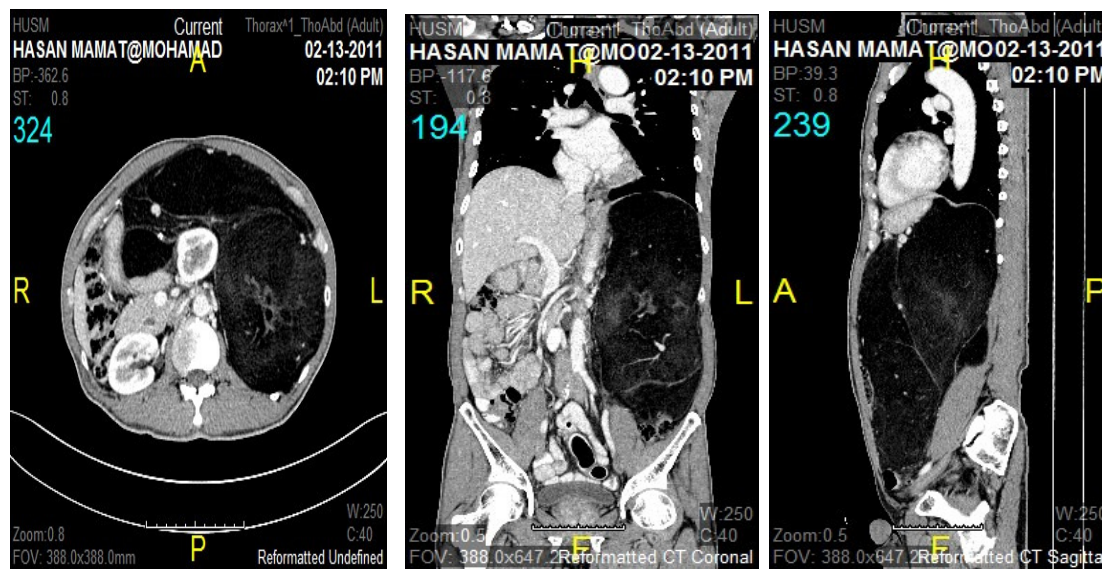


Figure 1. CT scan of our patient showing a left-sided retroperitoneal mass pushing most of the abdominal organs to the right.

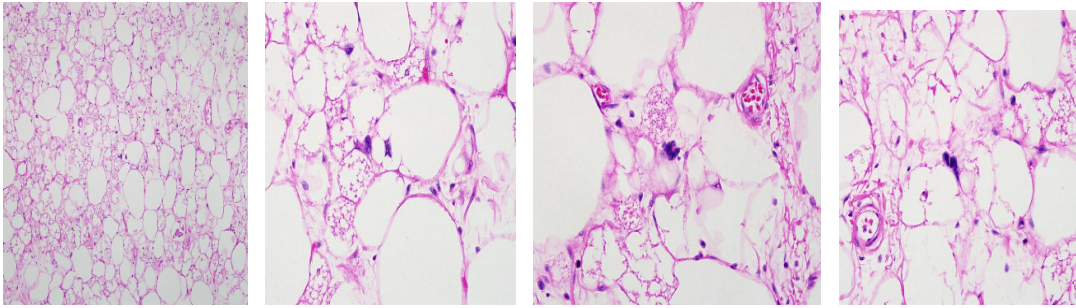


Figure 2. Histological view of liposarcoma in our patient showing peripherally displaced nuclei.

FBC, LFT and RFT were within normal limits. Informed consent was taken and excision of the tumor was done using a midline abdominal incision. A 4.32kg retroperitoneal mass was excised along with the spleen to which it was fixed. Post operative period was uneventful and patient was discharged home.

Discussion

Retroperitoneal tumor is one of the spectrums of diseases that pose both diagnostic and surgical management dilemma¹. Most patients are asymptomatic with abdominal distension being the commonest presentation. They account for 10-15% of soft tissue sarcoma³ and 0.2% of all tumors.⁴ Diagnosis is usually obtained using USS and CT scan as it is difficult to arrive at diagnosis clinically.^{4,5}

Surgical resection remains the mainstay of managing these wide range of tumors² and may involve resection of adjacent structures^{3,6} just as in our patient who had splenectomy.³ The approach to surgical resection remains a dilemma particularly in our patient who had incongruent CT scan and angiography findings.

Most literature favors the use of midline abdominal incision³ which was used in our patient and all the patients who had surgery in our case study. This approach offers the advantage of better haemostasis, resection of adjacent organs infiltrated by the tumor as reported by Strauss et al² in their review of surgical management of primary retroperitoneal sarcoma.³ Although this approach is the most favored, it has the disadvantage of post-operative ileus and long term post operative intestinal adhesions. Retroperitoneal approach is also one of the favored surgical approach as reported by Maurya et al.² This approach has the advantage of reducing intra operative fluid loss, post operative ileus thereby allowing oral feeding as soon as patient is fit enough to feed. It also saves the patient from developing post op adhesion in the future².

Minimal invasive methods using endoscopic surgery is now becoming popular as reported by Johna and co⁷. This is believed to have similar advantage as the retroperitoneal approach with better cosmesis. Liposarcoma is the commonest form of retroperitoneal tumor^{3,5} and has a high propensity for recurrence⁵.

Conclusion

Midline approach in the management of retroperitoneal tumors still remains a well acceptable and formidable route of achieving good oncological margin. This, reduces recurrence and improves survival.^{2,3,5,6,7}



References

1. Norman, S. W. Christopher, J.K.B & Ronan, P.O., 2008. Bailey & Love's Short Practice of Surgery. **25th** edition. Hachette Livre UK: Hodder Arnold. Pg1006-1007.
2. MJAFI 2003; **59** : 73-74
3. Strauss , D.C. et al. 2010. Surgical management of primary retroperitoneal sarcoma. British Journal of Surgery; **97**: 698–706.
4. Arakawa, a. et a. Radiological Findings Of Retroperitoneal Leiomyoma And Leiomyosarcoma: Report of Two Cases. Computerized Medical Imaging and Graphic. Vol. **17**, **No. 2**, pp. 125-131, 1993
5. De Voorde, L.V. et al. 2011. Radiotherapy and Surgery—An Indispensable Duo in the Treatment of Retroperitoneal Sarcoma. Published online in Wiley Online Library (wileyonlinelibrary.com) Cancer Month **00**, 2011
6. Murawa, D. et al. 2005. Cases of giant Retroperitoneal Liposarcomas. Rep Pract Oncol Radiother, **10(3)**: 147-151. Available online at <
<http://www.rpor.pl/pdf.php?MAN=7656>>
7. Johna, S. 2004. Journal of the Society of Laparoendoscopic Surgeons. **8(3)**: 287–289.