

Surgical Experience with Closure of an Isolated PDA at Muhimbili Cardiothoracic Unit in Dar es Salaam, Tanzania

ETM Nyawawa, E. Ussiri, MA Njelekela, U Mpoki, BJ Nyangassa, WBC Wandwi, E. Lugazia
Muhimbili Cardiothoracic Unit, Muhimbili, Dar es Salaam, Tanzania

Correspondence to: Dr. Evarist TM Nyawawa, Email: enyawawa@gmail.com

Background: *This study describes our experience in the management of isolated patent ductus arteriosus; complications and mortality rate. Further it describes the innovative technique for the closure of the duct.*

Methods: *We retrospectively recruited all patients' files that underwent PDA closure from May 2008 to July 2011 in all these patients clinical evaluation and confirmation of diagnosis was made by echocardiography. There were two-treatment group. The first group underwent a standard surgical closure and these were 26 patients this group was obtained from the usual and routinely done PDA ligation. The second group also comprised 26 patients who had undergone a modified closure technique as illustrated by Kirklin¹. Patients' age, sex duration of illness, stage of the disease as classified by New York Heart Association, ventricular function as depicted by left ventricular ejection fraction, any associated lesion were noted. During operation, confirmation of the PDA was done and the total operation time (TOT), total duration of ventilation (VT), and any complication were noted. The total duration of intensive care stay and the postoperative period stay in the ward were noted. Patients had been followed at six months interval for two years; in which during follow up evaluation for their cardiac status to exclude congestive heart failure, presence of residual PDA had been done. All data were entered in a structured data sheet and analyses using Spss window 17 statistical program.*

Results: *A total of 52 patients with clinical diagnosis of PDA, 26 patients in each treatment group of either standard closure or new closure technique. Female patients had outnumbered male patients by 5.5 folds. A total of 46.1% of patients were under five years old. A relatively younger population of patients was seen with the new closure technique as compared to patients in the standard closure technique ($p=0.02$). Similarly a correspondingly less heavier weight was noted in patients who underwent new closure technique as compared to those who had standard closure technique($p=0.03$). Long- term follow up of patients with their treatment modalities it was found that 3 patients and 2 patients had residue lesion and congestive cardiac failure respectively who were exclusively in the standard closure technique, none of such complications were seen with the new closure technique ($p=0.04$). With such evidence, the practice to date has been the new closure technique for definitive surgical treatment for PDA.*

Conclusion *Open surgery for PDA closure remains the procedure of choice for facility and technically deprived countries. The approach and the technique of closure that minimize the postoperative complications is a challenge from centre to centre. However this study with a new closure in which a purse string on the ampulla of the PDA followed by a silk ligature has proved to be efficient and reliable technique that leaves no residual lesion with no long term complications.*

Key words: Closure, Isolated, Patent, ductus arteriosus, PDA

Introduction

Patent ductus arteriosus (PDA) is one of the commonest acyanotic congenital heart disease accounting for 5-10% of all congenital heart diseases^{2,3}. It is a vascular structure that connects the proximal descending aorta to the roof of the main pulmonary artery near the origin of the left pulmonary artery³. It is a normal and essential fetal structure that becomes abnormal if it remains patent after the normal neonatal period. Embryologically is a derivative of the distal portion of the left-sixth aortic arch². Hemodynamically it causes left to right shunt resulting into pulmonary overcirculation and consequently congestive cardiac failure^{3,4}. It may complicate to infective endarteritis, aortic aneurysm and acute aortic dissection^{5,6}. With long standing increase in pulmonary pressure and volume overload

it may lead to hypertensive pulmonary vascular disease^{6,7}. There have been several approaches to definitive closure of PDA^{8,9}. In developed countries where facilities and expertise are available, transcatheter device closure with the use of Nit-Occlud coil, Gianturco-coil, and currently Amplatzer duct occluder is the practice^{10,11,12}. While in developing countries the approach is surgery with a posterolateral thoracotomy^{13,14}. Despite the fact that there are several approaches, surgery is the gold standard and is regarded as the safe, reliable and efficient procedure². The surgical approach though varies from centre to centre but the usual practice has been the standard with a posterolateral thoracotomy followed by use of double ligation of the duct^{13,14,15,16}. We have practiced the same at our centre since the establishment of the centre in May 2008 but on long term follow up of our patients we noted an alarming number of patients presenting with congestive cardiac failure and after thorough evaluation were found to have residual PDA. Consideration was therefore made to retrospectively review the patients' case notes and find out the modalities of closure technique they had undergone. It was also thought that recanalization would only be possible in presence of poor ligature or due to presence of a sinus created by the ligature on the aortic end.

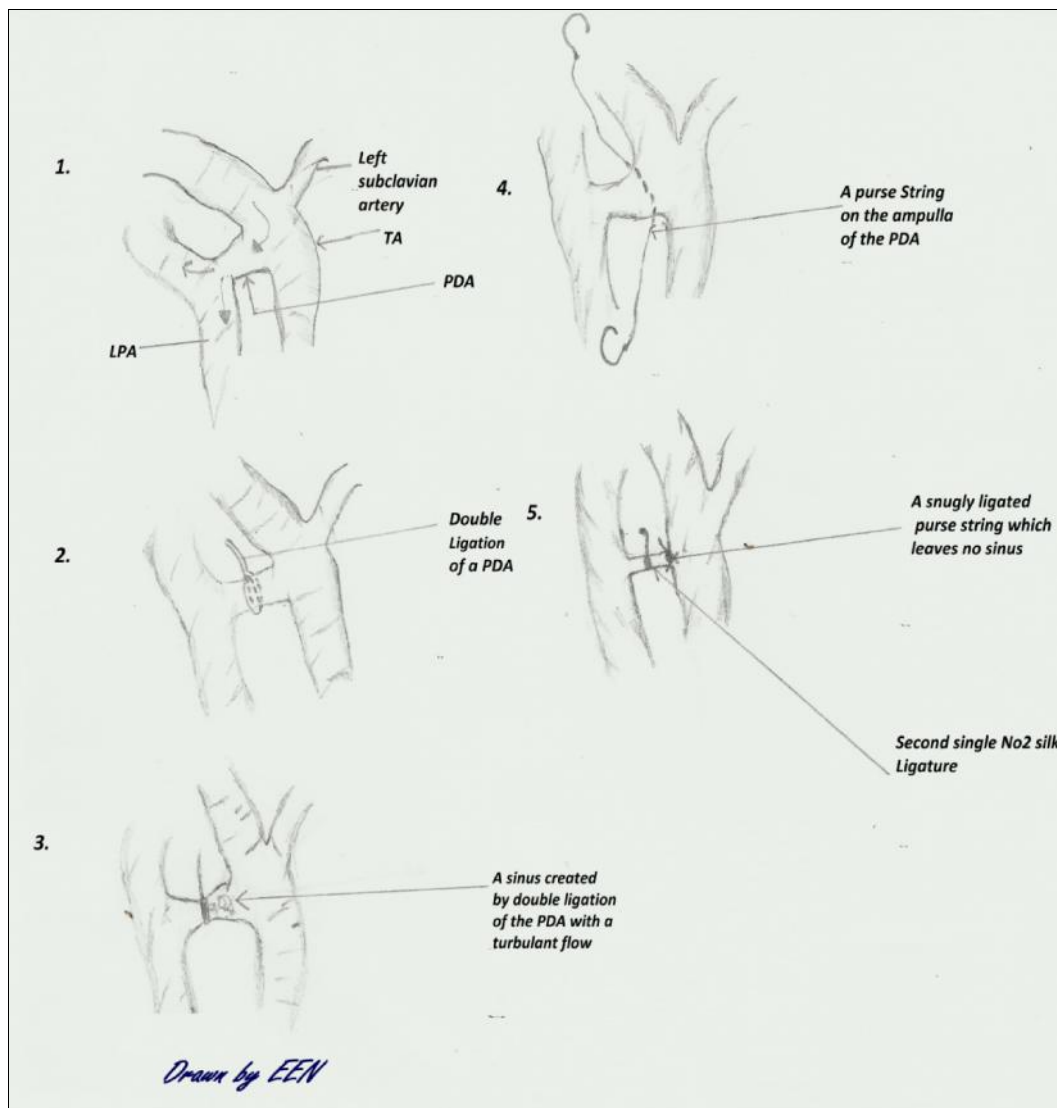


Figure 1 Pathophysiology for Recanalization for PDA after Standard Surgical Closure.

. Undue high flow in the descending aorta causes turbulence in the sinus and untying of the ligature and hence recanalization. The assumption made from frequent recanalization following routine

closure of the PDA by double ligation that; because of the hemodynamic flow of blood, a pressure gradient exists between the aorta and the left pulmonary artery. That during double ligation the ligature usually stays at the narrowest point and in an event that the ligation was not complete or the ampulla remains unclosed these creates a sinus which in turn with continuous aortic blood flow causes turbulence in the aortic sinus created by the ligature. This turbulence because it has high pressure will then continues to dilate the duct or it will cause the ligature to untie and hence recanalization and consequently a residual lesion. By interrupting the PDA with a purse string in the ampulla it leaves no possibility of creating a sinus and hence no turbulent flow.

We had adapted closure technique by Kirklin¹ a new closure technique that ensured no sinus is left behind after closure of the PDA

Patient and Methods

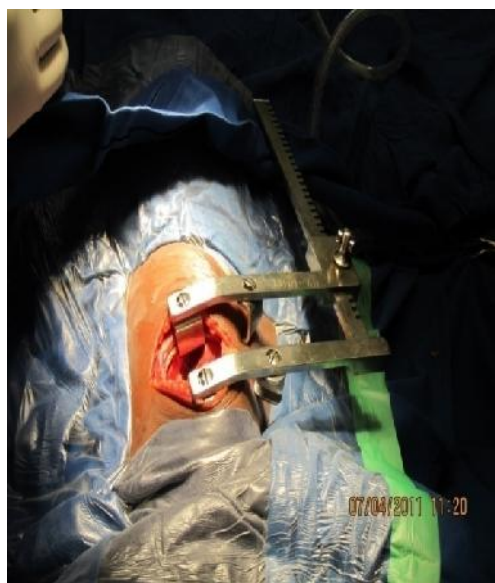We retrospectively recruited all patients' files who underwent PDA closure from May 2008 to July 2011 in all these patients clinical evaluation and confirmation of diagnosis was made by echocardiography. The study was approved by the institutional ethical clearance committee for research and publication. There were two-treatment group. The first group underwent a standard surgical closure and these were 26 patients this group was obtained from the usual and routinely done PDA ligation. The second group also comprised 26 patients who had underwent a modified closure technique as illustrated by Kirklin¹ this had been a new closure technique as it was not usually practiced at the institute. All patients scheduled to undergo surgical operation had prior consent for the surgical procedure and for their data to be used in research, excluded were those who did not consent for the study.

Patients' age, sex duration of illness, stage of the disease as classified by New York Heart Association, ventricular function as depicted by left ventricular ejection fraction, any associated lesion were noted. It was further noted that during operation, confirmation of the PDA was done and the total operation time (TOT), total duration of ventilation (VT), and any complication were noted. The total duration of intensive care stay and the postoperative period stay in the ward were noted. Patients had been followed at six months interval for two years; in which during follow up evaluated for their cardiac status to exclude congestive heart failure, presence of residual PDA had been done. All data were entered in a structured data sheet and analyses using Spss window 17 statistical program.

Surgical technique

These patients *were* scheduled to undergo PDA ligation through a posterolateral thoracotomy and then ligation. It was noted that there were two treatment groups the first group comprised of patients who underwent standard surgical closure technique these were those who underwent routine PDA double ligation. The second group patients comprised those who underwent a modified closure the "new closure technique" as depicted by Kirklin¹.

In either of the surgical closure technique a left posterolateral thoracotomy was done, the serratus anterior was preserved in young children. Then through the fourth intercostal space, the thoracic cavity was entered. The left lung was retracted using lung retractor interposed with pieces of gauze. The visceral pleura over the descending thoracic aorta was split in between and reflected on either side. The supreme intercostal vein was doubly ligated and transected. Exposure of the PDA was therefore made. In the first group of patients; "*Standard closure technique*" this involved mobilizing the PDA and introducing two Vaseline lubricated silk number two behind the duct and before ligating the anaesthesiologist was requested to reduce the systemic pressure to about 100 mmHg, then doubly ligating the duct and hence completing the technique.



Figures 2 – 5. Procedure technique

Figure 2 A left poster lateral thoracotomy and rib retraction

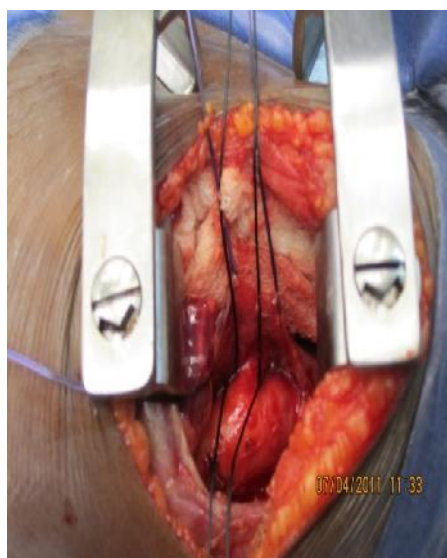


Figure 3 Passing around the PDA two silk sutures number two and separating them.

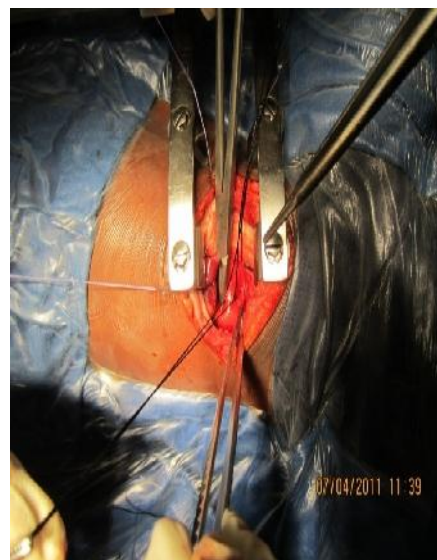


Figure 4 Taking several adventitial purse string bites on the ampulla of the PDA

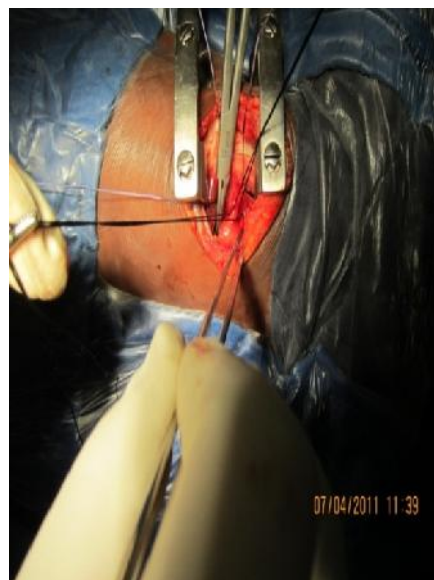

Figure 5 Passing the needle of 4/0 prolene suture in a reverse direction to the posterior of the duct while making an upward traction.

Results

In the second group of patients, *New Closure technique* this involved introducing the same two vaselline lubricated silk sutures no 2, then separating them at a distant: a prolene suture no 4/0 was used to make a purse string by taking bites in the adventitial tissue on the ampulla of the PDA (aortic end of the duct), then the assistant was asked to make a slight upward traction so that the surgeon takes more bites and reverses the needle in order to pass it behind the duct. The purse string was first snugly ligated which immediately and efficiently closes the duct and the murmur and thrill were noted to disappear instantly.

One of the silk sutures inserted earlier was then pulled out and the remaining ligated to safeguard the purse string in the adventitial. The operation was completed by closing the visceral pleural over the aorta that was opened before by several interrupted sutures. A chest tube of desirable size was inserted and connected to underwater seal drainage. The lungs were inflated to remove any atelectasis and the thoracotomy was closed layer by layer using vicryl suture. The patient was shifted to the intensive care unit and monitored closed till when was extubated; further monitoring continued until the patient was transferred back to the ward. Once the patient in the ward a clinical evaluation was made and before discharge a control Echocardiography was done to evaluate the patient. If the patient found to have residual PDA even after closure they were noted and these were followed up closely at outpatient clinic. Further noted during the postoperative period were complications that developed.

Data collection

Patients' data extracted from files were collected and entered into a structured coded data sheet and into a Spss program window 17 and analyzed. Chi-square (χ^2) was used to compare categorical data, analysis of variance and hence F test was done, for continuous variable and significant test was considered at 95% confidence interval.

Results

There were 52 patients, male patients were eight (15.4%) and 44 (84.6%) were female patients. Female patients outnumbered male patients by 5.5 folds. There was equal distribution of patients in either of the treatment groups. Majority of patients were in the age group of 1.1-5 years (46.15%).

Majority of patient were in NYHA class II (67.3%) and class III (23.1%) no statistical significant difference was noted between the two treatment groups

Majority of cases in either of the treatment arm had no major complications 20 (77%) in the standard closure technique and 22 (84.6%) cases in the new closure technique (Figure 7). And there was significant difference in terms of complications with regard to development of arrhythmias and electrolyte imbalance. However a few numbers of patients in the standard closure technique had CCF and low cardiac states which could not occur in patients who underwent new closure technique.

Table1. Age Groups and Treatment Technique

Age group (years)	Surgical closure technique		Total (%)
	Standard	New	
Infants (< 1)	0	6	6 (11.5)
1.1-5	11	13	24 (46.2)
5.1-10	5	4	9 (17.3)
10.1-15	3	1	4 (7.7)
15.1-20	7	2	9 (17.3)
Total	26	26	52 (100.00)

Table 2. Overall statistics in study groups

Variable	Descriptive statistics						Anova	
	Treatment	Number	Mean ±	SD	Minimum	Maximum	F	Significance
Age	Std	26	8.87 ± 6.23		1.3	19	5.76	0.02
	New	26	4.82 ± 5.02		0.5	20		
Weight	Std	26	26.64 ± 21.03		8.5	106	5.24	0.03
	New	26	15.64 ±		6.5	60		
Duration	Std	26	12.58		2	120	0.11	0.75
	New	26	36.00 ± 30.76		3	120		
RVSP	Std	26	33.23 ± 29.14		25	62	1.39	0.25
	New	26	34.31 ±		18	77		
EF	Std	26	9.95		44	79	4.08	0.05
	New	26	33.54 ± 11.62		58	82		
FS	Std	26	62.19 ± 9.11		23	47	2.39	0.13
	New	26	66.81 ± 6.24		23	51		
TOT	Std	26	31.19 ± 7.17		1	3	4.54	0.04
	New	26	34.31 ± 6.51		1	2		
ICUS	Std	25	1.81 ± 0.44		2	6	0.63	0.43
	New	26	1.55 ± 0.41		2	11		
PIHS	Std	24	3.40 ± 1.26		1	25	8.37	0.006
	New	26	3.77 ± 1.80		3	10		
			9.42 ± 5.20					
			6.27 ± 1.64					

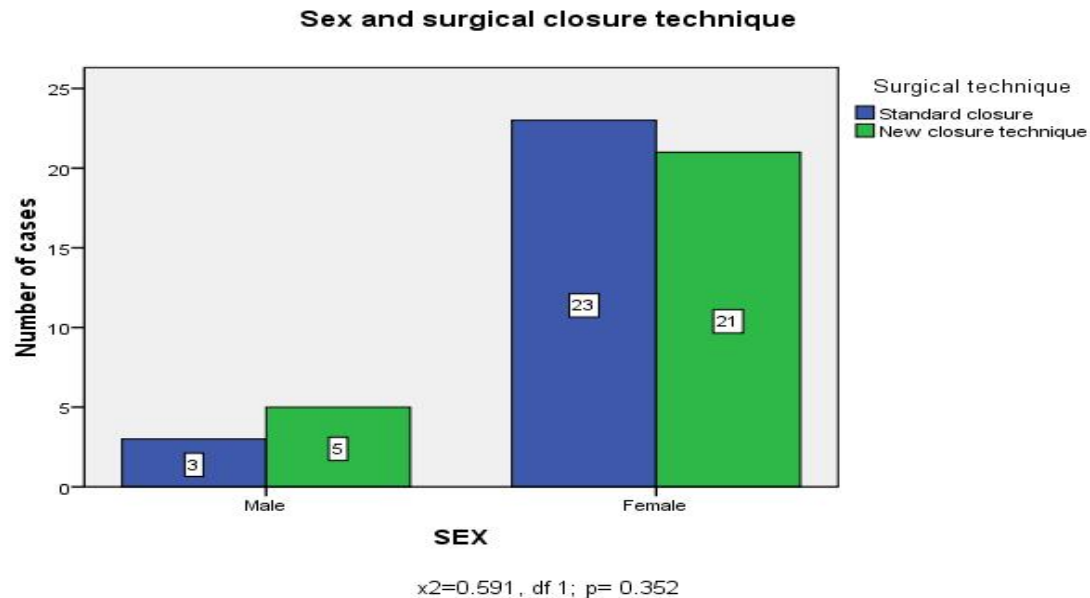
Key: Std= standard closure technique, New= new closure technique, Duration= duration of symptoms, RVSP= right ventricular systolic pressure, EF= ejection fraction, FS= fractioning of shortening, TOT= total operation time, ICUS= intensive care unit stay, PIHS= post intensive care hospital stay.

Table 3. Stage of Cardiac Disease and the Surgical Closure Technique

NYHA	Surgical closure technique		
	Standard N (%)	New N (%)	
I	1 (33.3)	2 (66.7)	I
II	16 (45.7)	19 (54.3)	II
III	8 (66.7)	4 (33.3)	III
IV	1 (50.0)	1 (50.0)	IV
Total No (%)	26 (50.0)	26 (50.0)	Total

$\chi^2=4.124$, df 3; p= 0.248.

One of the patient with a residual lesion in the standard group eventually developed Congestive cardiac lesion and severe mitral regurgitation. Still patients in the standard group who had no known complication in the early follow up one of the patient developed a residual lesion that was associated with severe mitral regurgitation and pulmonary hypertension (Table 4)..



Figures 6. There were 3 and 5 male patients in the standard and new closure technique respectively, and correspondingly 23 and 21 female patients

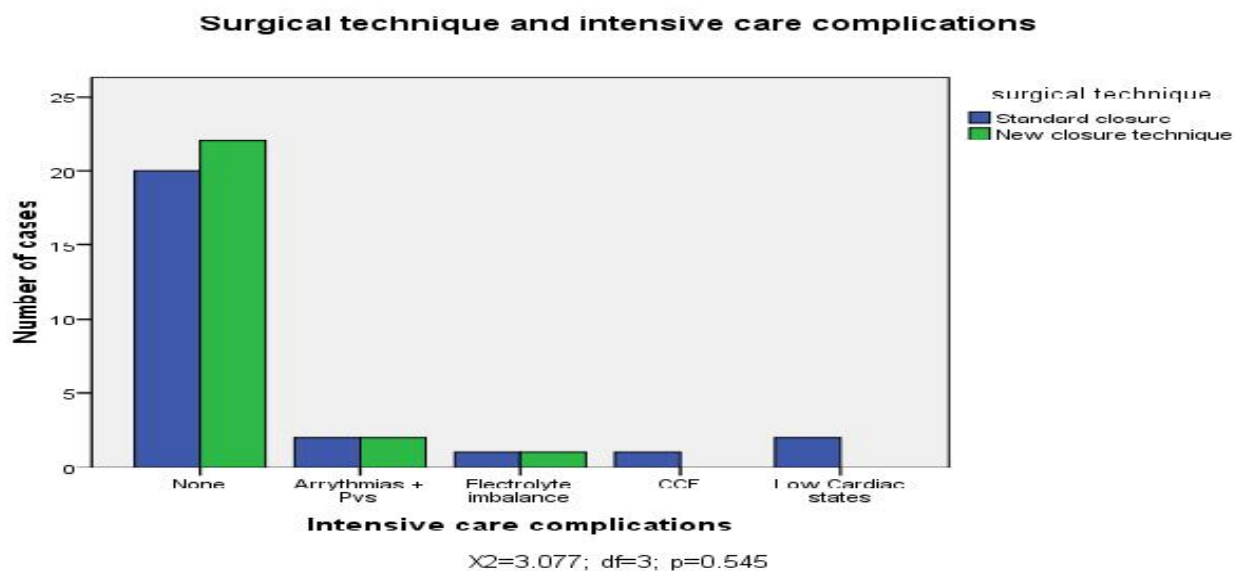


Figure 7.

There were 3 patients in the standard treatment group who died in the intensive care unit. One patient in the new treatment group had missed diagnosis that turned to be aorto pulmonary window, the second patient in the same group died in the intensive care unit due to arrhythmias that was followed by cardiac arrest. All these patients constituted the none applicable (NA)

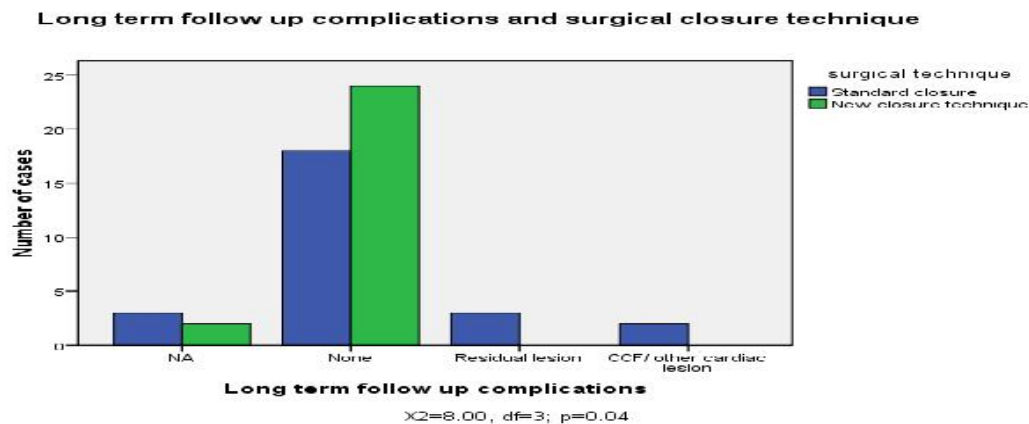


Figure 8. Long Term Follow up Complications

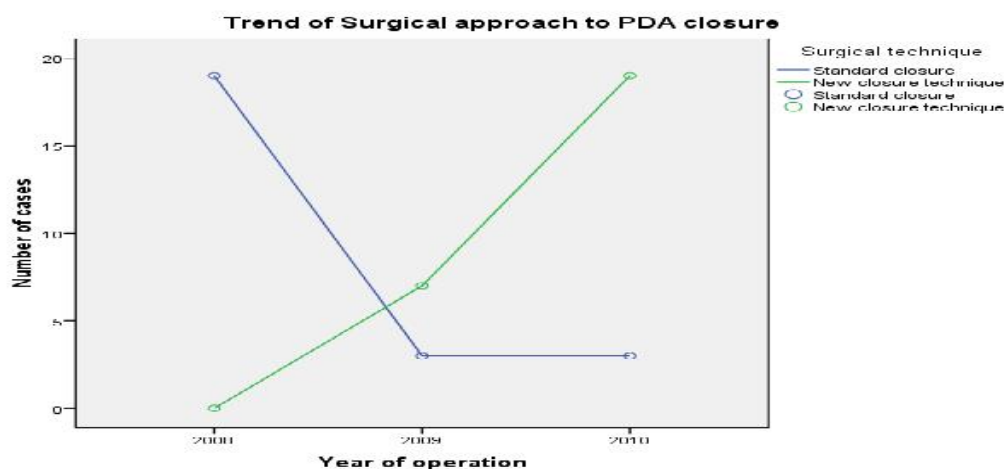


Figure 9

Table 4. Long term follow up at six months interval for 24 months

Complications	Surgical closure technique		Total (%)
	Standard	New	
Not applicable	3 (60.00)	2 (40.00)	5 (9.60)
None	18 (42.90)	24 (57.10)	42 (80.80)
Residual lesion	3 (100.00)	0 (00.00)	3 (5.80)
CCF/other cardiac lesion	2 (100.00)	0 (00.00)	2 (3.80)
Total	26 (50.000)	26 (50.00)	52 (100.00)

$\chi^2=8.00$, $df=3$; $p=0.04$

Discussion

This study has demonstrated a new approach to closure of the PDA that technically leaves no residual lesion and no longer term follow up complications (Table 4 and Figure 3). The study has further shown that it is feasible and easy to perform as the total operation time was shorter as compared to standard closure technique ($p<0.05$). The failure to detect a residual lesion in the early postoperative period but on long term follow up turned up to have a residual lesions; further emphasizes that ligation of a PDA that leaves a sinus behind; on longstanding high blood flow and turbulence leads to gradual untying of the ligature and hence recanalization. That was as one case noted in the standard

closure technique who actually was later found to have congestive cardiac failure with other cardiac lesions such as severe mitral regurgitation and pulmonary hypertension (Table 4).

The incidence of arrhythmias and electrolyte imbalance in the ICU was noted to occur equally, with the two treatment groups; however, there were a relatively higher proportion of patients with congestive cardiac failure and low cardiac state in patients who underwent standard closure. This implies that in patients who has residual lesion, poorly ligated the chance to have failure is higher. Though the treatment groups showed differences in age and weight (Table 2) which could be explained by easy access to treatment as some of patients came from remote areas and even the unit has recently started that the standard group had comprised older age group and hence a relatively higher weight as compared to patients in the new closure technique. However the two treatment group were similar in terms of the stage of the disease (NYHA) and there was no any statistical difference ($P=0.248$). This surgical technique is the probably the ideal technique for facility deprived countries as compared to developed centers where the current practice is interventional using device closure with amplatzer occlude, nit-occlude and many other devices^{10,11,12,13}.

Conclusion

Open surgery for PDA closure remains the procedure of choice for facility and technically deprived countries. The approach and the technique of closure that minimize the postoperative complications is a challenge from centre to centre. However, this study has shown that a purse-string at the ampulla of the PDA is safe and leaves no residual lesion and longer-term complication.

Acknowledgement

I thank Evans and Elline for the time they took for entering data into the statistical programme, once more I thank Evans for his creative anatomical drawings and description in the pathophysiology of recanalization. And finally I thank my family throughout the time of this study.

References

1. Kirklin, Barrat. Patent Ductus Arteriosus. In Cardiac Surgery, Churchill Livingstone. Third Edition, Volume 1, pg 928-945
2. Douglas J, Schneider, John W. Moore. Congenital heart disease for the adult cardiologist, Patent ductus arteriosus. *Circulation* 2006; 114: 1873-1882.
3. Heymann MA, Creasy RK, Rudolph AM. Quantitation of blood flow patterns in foetal lamb in utero. In: proceedings of Sir Joseph Barcroft Centenary Symposium: Foetal and Neonatal physiology. Cambridge UK: Cambridge University press; 1973: 129-135.
4. Carlgren LE. The incidence of congenital heart disease in children born in Gothenburg 1941-1950. *Br Heart J*. 1959; 21: 40-50
5. Reed KL, Meijboom EJ, Sahn DJ, Scagnelli SA, Valdes-Cruz LM, Shenker L. Cardiac Doppler flow velocities in human fetuses. *Circulation*. 1986; 73: 41-46
6. Marquis RM, Miller HDC, Mac Cormack RJM et al. Persistence of ductus arteriosus with left to right shunt in the older patient. *Br Heart J*. 1982; 48: 469-484.
7. Espino-Vela J, Cardenas N, Cruz R. patent ductus arteriosus with special reference to patients with pulmonary hypertension. *Circulation* 1968; 38: (suppl V): V45-V60
8. Taneja K, Gulati M, Jain M, Saxena A, Das B, Rajani M. Ductal arteriosus aneurysm in the adult: role of computed tomography in diagnosis. *Clin Radiol* 1997; 52: 231-234
9. Gross RE, Hubbard JP. Surgical ligation of patent ductus arteriosus: a report of first successful case. *JAMA* 1939; 112: 729-731
10. Rashkind WJ, Cuaso CC. Transcatheter closure of patent ductus arteriosus: successful use in a 3.5kg infant. *Pediatr Cardiol*. 1979; 1: 3-7
11. Fisher RG, Moodie DS, Sterba R, Gill CC. patent ductus arteriosus in adults-long term follow-up: nonsurgical vs surgical treatment. *J Am Coll Cardiol*. 1986; 8: 280-284.

12. Moore JW, Schneider DJ, DiMeglio D. the Duct-Occlud device: design, clinical results and future directions. *J intervent Cardiol* 2001;14: 231-238
13. Pass RH, Hijazi Z, Hsu DT, Lewis V, Hellenbrand WE. Multicenter USA Amplatzer patentductus arteriosus occlusion device trial: initial and one year results. *J Am coll Cardiol* 2004;44: 513-519
14. Ghani SA, Hashim R. Surgical management of patent ductus arteriosus: a review of 413 cases. *JR Coll Surg Edinb.* 1989; 34: 33-36
15. Cetta F, DeLeon SY, Roughneen PT, Graham LC, Lichtenberg RC, Bell TJ, Vitullo Da, Fisher EA. Cost-effectiveness of transaxillary musce –sparing same –day operative closure of patent ductus arteriosus. *Am J Cardiol* 1997;79: 1281-1282
16. Hawkins JA, Minich LL, Tani LY, Sturtivant JE, Orsmond GS, McGough EC. Cost and efficacy of surgical ligation versus transcatheter coil occlusion of patent ductus arteriosus. *J Thorac Cardiovasc Surg.* 1996; 112: 1634-1639.