

## Hepatic haemangioma: a Case Report and Review of Literature

S. A. Salati, A. Al Kadi

Department of Surgery,

Unaizah College of Medicine, Qassim University Qassim, Kingdom of Saudi Arabia

**Correspondence to:** Dr. Sajad Ahmad Salati, Email: [docsajad@yahoo.co.in](mailto:docsajad@yahoo.co.in), docsajad@gmail.com

**Hepatic haemangiomas account for about quarter of all benign tumours of the liver. In last few decades, lot of advances have been made in the field of diagnosis and management of these lesions. This article presents a case of hepatic haemangioma that is under follow-up of the authors. Furthermore the subject is reviewed in the light of recent literature**

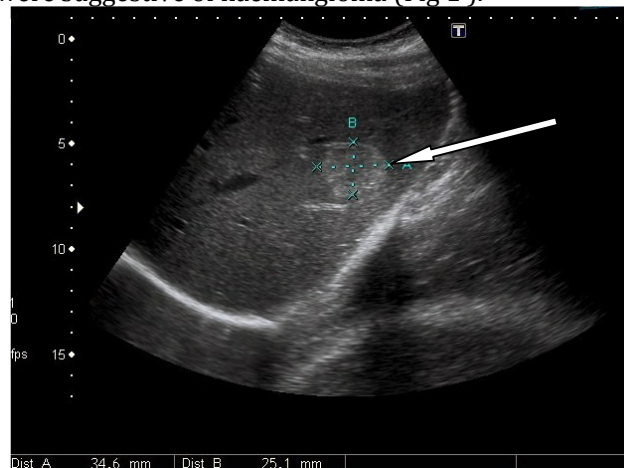
### Introduction

Hepatic haemangioma and is the second most common tumour seen in the liver after metastases and accounts for 73% of all benign liver tumours with a frequency of 0.4-7.3% at autopsy<sup>1</sup>. They are composed of masses of blood vessels with atypical or irregular in arrangement and size. They are also referred to as cavernous haemangiomas due to the cavernous vascular space seen in histological studies. These benign tumours are usually small, solitary or multiple, and asymptomatic<sup>2</sup>.

### Case presentation

A 32 years old female, married with two children, reported with vague pain in upper abdomen of severity of 3/10 on Visual analogue scale. There was no significant past medical, surgical, drug-intake or family history. On examination, the vital signs were stable and the abdominal examination revealed no positive findings.

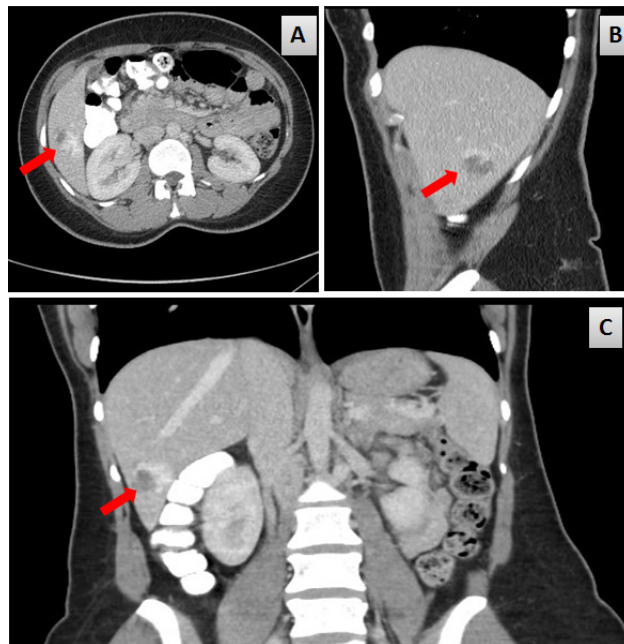
Ultrasonogram of the Abdomen revealed the liver to be of average size (12 cm) with a homogenous parenchymal echo-pattern and normal calibre of portal vein and biliary tree. There was a well-defined hyperechoic lesion seen in the left liver lobe measuring about 3.5 X 2.5 x 2.8 cm and the features were suggestive of haemangioma (Fig 1).



**Figure 1.** Ultrasonogram Depicting Hyperechoic Haemangioma in the Left Lobe of Liver

CT scan of the abdomen and pelvis with IV and oral contrast revealed a 2.7 cm low-attenuation mass in Segment 5 of the liver (in right lobe) showing peripheral puddling of contrast in the portal venous phase characteristic of a haemangioma (Figure 2). There were no other hepatic lesions or intra or extra hepatic biliary ductal dilatation. The gallbladder, spleen, pancreas and

both kidneys/ adrenals had normal features. There was no ascites or retroperitoneal lymphadenopathy.



**Figure 2.** Contrast enhance CT Scan depicting hepatic haemangioma (shown with red arrow) in (A) Transverse plane (B) Sagittal plane (C) Coronal plane .

The first degree family members (parents, two siblings and two children) were screened by abdominal ultrasonography and were found to have no lesions. The patient was counselled under follow up, without any active intervention. USG studies repeated at follow up of one year revealed that the lesion had remained static in dimensions.

### Pathophysiology

The aetiopathogenesis of hepatic haemangiomas is not understood completely. They are postulated to be vascular malformations or hamartomas of congenital origin that undergo enlargement by ectasia rather than by hypertrophy or hyperplasia. No definite familial or genetic mode of inheritance has been described though a few case series have been reported in literature, indicating some role for familial link.

Moser et al<sup>2</sup> presented a report of a large family of Italian origin where three female patients in three successive generations suffered from large symptomatic hepatic haemangiomas. In addition, two other female relatives exhibited asymptomatic haemangiomas on ultrasonography. The authors postulated that restriction of the disease to the females could be explained by sex-dependent differences in penetrance or expressivity of a presumable "liver-haemangioma" gene or the production of proliferative factors, such as female sex hormones. The authors also observed an unexplained increased incidence of thyroid adenomas among members with or without hepatic haemangioma of the reported family. Diez Redondo P et al<sup>3</sup> described a family in which six members from three successive generations presented hepatic haemangiomas. One of the cases was taking oral contraceptives and had a painful giant haemangioma with biochemical abnormalities while the remaining cases were asymptomatic. Li P et al<sup>4</sup> reported two siblings (a male and a female) with Dubin-Johnson syndrome with multiple hepatic haemangioma.

Several pharmacologic agents have been postulated to promote the growth or induce symptoms in haemangioma. These include female sex (endogenous /exogenous) hormones<sup>5,6</sup> and steroids. Spitzer D et al<sup>7</sup> reported asymptomatic increase in hepatic haemangioma in pregnant women following ovarian stimulation therapy with clomiphene citrate and human chorionic gonadotropin. Graham E et al<sup>8</sup> reported a case of symptomatic hepatic haemangioma with haemorrhage during pregnancy and mentioned estrogens to be the possible cause the growth of haemangiomias.

## **Epidemiology**

### **Frequency**

The reported incidence rate varies widely and is approximately 2%. The prevalence rate at autopsy is as high as 2- 7.3%<sup>1,8</sup>. The widespread use of non-invasive abdominal imaging modalities has led to increased detection of asymptomatic lesions in recent times.

### **Sex**

Women, especially with a history of multiparity, are affected more often than men. The female-to-male ratio reported in literature<sup>9</sup> varies from 3-6:1.

### **Age**

Hepatic haemangiomas can occur at all ages though 60 to 80 percent of cases are diagnosed in individuals aged 30-50 years. Female often present at a younger age and with larger lesion. Further the lesions responsible for symptoms are more likely in females<sup>6</sup>. Hepatic haemangiomas may be seen in infancy and have also been detected prenatally in a growing fetus. Isaacs<sup>10</sup> studied 194 foetuses and neonates with hepatic tumours diagnosed prenatally (n = 56) and in the neonatal period (n = 138) and found haemangioma to constitute 60.3% (n=117) of cases.

## **Pathology**

Hepatic haemangiomas vary in size from a few millimetres to many centimetres though usually are 2-4 cm. 70-80% are solitary and the larger lesion may be pedunculated<sup>11-12</sup>.

On gross examination, the lesions appear as dark-purple cystic masses, which collapse when sectioned due to oozing out of blood. They can be found in either of the lobes of the liver, though are predominantly found in the right lobe. Lesions tend to be well circumscribed and often surrounded by a thin capsule /interface<sup>13</sup>. The cut surfaces exhibit a red-brown appearance with a spongy consistency that may show haemorrhage, scarring, phleboliths or calcification.

Microscopically, the tumour is composed of large (cavernous) vascular spaces of varying sizes, lined by a single layer flat tumour endothelial cells (which appear very similar to normal cells). The vascular compartments are separated by thin fibrous septae and may contain thrombi. Large haemangioma may show features of collagenous scars or fibrous nodules as thrombosis occurs and very rarely, there may be focal stromal calcification and ossification.

## **Clinical presentation**

Haemangiomas are generally small, asymptomatic and discovered incidentally when the liver is imaged for unrelated conditions<sup>14</sup> or when the liver is examined at laparotomy or autopsy. Goodman<sup>15</sup> in 1987 found that the symptoms are experienced by 40% of cases with greater than 4-cm haemangioma and by 90% of cases with 10-cm haemangioma. Upper abdominal pain /discomfort or fullness is the most common complaint, when the lesion becomes symptomatic.

Less common complaints include nausea, anorexia, dyspepsia and early satiety, which are seen when large haemangiomas compress the adjacent organs <sup>16</sup>.

The pain is usually mild but can become severe due to thrombosis or bleeding within the lesion and associated stretching and inflammation of Glisson's capsule. Pain from an acute thrombosis can last up to three weeks and be associated with pyrexia and derangement of liver functions <sup>17</sup>. Physical examination is generally normal and the only findings of significance, seen infrequently, are an enlarged liver or the presence of an arterial bruit over the right upper quadrant.

The atypical presentations of hepatic haemangiomas include:

1. High output cardiac failure from massive arteriovenous shunting, particularly in the children <sup>18, 19</sup>.
2. jaundice from compression of the bile ducts <sup>20</sup>,
3. hypothyroidism refractory to hormone replacement therapy, due to the presence of high levels of 3-iodothyronine de-iodinase activity in the haemangioma, that catalyzes the conversion of thyroxine and triiodothyronine to biologically inactive hormones, reverse triiodothyronine, and 3,3'-diiodothyronine <sup>25</sup>
4. Gastrointestinal bleeding from haemobilia <sup>21, 22</sup>, and
5. Pyrexia of unknown origin <sup>23, 24</sup>.
6. polymyalgia rheumatica, resistant to steroids <sup>26</sup>.
7. Kasabach-Merritt syndrome (KMS) is a rare and severe coagulation disorder characterized by profound thrombocytopenia, microangiopathic hemolytic anemia, and consumption coagulopathy <sup>27 -29</sup>

In children, cutaneous haemangiomas may serve as markers for hepatic haemangiomas. Huges JA et al<sup>30</sup> found that asymptomatic hepatic haemangiomas occurred in nearly 25% of infants presenting overall with six or more small or a single large cutaneous haemangiomas.

### **Differential Diagnoses**

Hepatic haemangiomas have to be differentiated from other benign and malignant space-occupying liver lesions. Benign lesions include cysts, adenomas, regenerating nodules, focal nodular hyperplasia, and abscesses and the malignant lesions include hepatocellular carcinoma, hepatic angiosarcoma and hepatic metastases. In histopathology, the specimen needs to be differentiated from:

- i. Hereditary hemorrhagic telangiectasia: the lesion has aberrant portal vessels with dilated vascular channels within portal tracts,
- ii. Infantile hemangioendothelioma: the lesion has cellular atypia.
- iii. Peliosis hepatis: the lesion has no fibrous septa

### **Diagnosis**

Hepatic haemangiomas have certain characteristics that point towards the diagnosis on ultrasonography, computed tomography (CT), or magnetic resonance imaging (MRI) <sup>31-32</sup>. A minority of lesions are however atypical and may require multiple imaging tests or conventional arteriography or even surgical intervention to achieve a confident diagnosis <sup>33</sup>.

**Plain radiograph** — Plain abdominal radiographs may be normal or may show evidence of calcification within the lesion. However this calcification lacks specificity in haemangiomas.

**Ultrasound** — Ultrasound typically reveals a well-demarcated, hyperechoic, homogeneous, mass. Colour Doppler Sonography (CDS) can depict intratumoural flow and peritumoural hepato-fugal portal flow in patients with hepatic haemangiomas accompanied by arterioportal shunt <sup>34</sup>.

Lim<sup>35</sup> presented a series of 45 patients with hepatic haemangiomas and found the tumour depth to be a significant variable that affects the capability of CDS to depict such findings. The frequencies of intratumoural flow and peritumoural hepatofugal portal flow were as high as 88% and 80% for shallow ( $\leq 30$  mm) lesions, and they were 40% and 35% for deep ( $>30$  mm) lesions ( $p=0.0012$ ;  $p=0.0051$ ).

**Contrast-enhanced ultrasound (CEUS)** — Ultrasound contrast agents consist of gas-filled echogenic microbubbles that enhance the ultrasound signal produced by flowing blood. This variant of ultrasonography demonstrates typical haemangioma imaging characteristics, in form of peripheral nodular contrast enhancement and iris-diaphragm sign in a high percentage of patients with undetermined lesions thereby improving the noninvasive functional characterization and differentiation of haemangiomas<sup>36</sup>.

Sirli R et al<sup>37</sup> presented a series which proved that CEUS diagnosed correctly 90% of hemangiomas, all with typical enhancement pattern and diagnosed additional 40% of hemangiomas that could not be diagnosed on the standard ultrasound. Ryu SW et al<sup>38</sup> found that the sensitivity, specificity, and accuracy for CEUS were 94.6% that is comparable to CT and MRI and hence CEUS can be highly reliable if appropriate acoustic window is available.

**Computed tomography** — A non-contrast-enhanced CT scan of a haemangioma usually demonstrates a well-demarcated hypo-dense mass. Calcifications may be seen in approximately 10 % of lesions. The lesions may appear as hyperdense relative to the surrounding parenchyma in patients with fatty liver. The administration of contrast medium results in peripheral nodular or globular enhancement in the early phase (in up to 90- 94 percent of hemangiomas  $>4$  cm in size), followed by a centripetal pattern or "filling in" during the late phase<sup>39</sup>. After a delay of three or more minutes, the lesions classically opacify and remain isodense or hyperdense on delayed scans. Enhancement may however be absent in hemangiomas with large cystic areas or scar tissue.

Recently a retrieval-based computer-aided diagnosis (CADx) system for the characterization of liver lesions in computed tomography (CT) scans has been introduced and in a study by Dankeri P et al<sup>40</sup>, the stand-alone predictive performance of the CADx system was assessed and compared to that of three qualified radiologists who were provided with the same amount of image information to which the CADx system had the access and CADx system was found to be highly reliable.

**Magnetic resonance imaging** — MRI has emerged in recent years as a highly accurate, non-invasive technique for diagnosing haemangiomas because of its high contrast resolution, lack of ionizing radiation, and the possibility of performing functional imaging sequences<sup>41</sup>.

With advances in hardware and coil systems, this modality has a sensitivity and sensitivity of more than 94 percent. Typically, the lesions have low signal intensity on T1-weighted images and are hyperintense on T2-weighted images. When gadolinium diethylenetriaminepentaacetic acid (Gd-DTPA) is used as a contrast agent, the lesions enhance in a fashion similar to that seen on dynamic CT displaying early peripheral discontinuous nodular or globular enhancement on arterial phase scans with progressive centripetal enhancement or "filling in" on delayed scans. Typically, haemangiomas follow the signal intensity of blood and the presence of intralesional fibrosis results in areas of low intensity on T2-weighted images. On High-b-value diffusion-weighted, DW-MR Images, the lesions often show findings that suggest restricted diffusion<sup>42</sup>.

Duran R et al (43) in 2015 presented the results of a retrospective study of 89 patients with 231 hepatic haemangiomas and found that the MR imaging characteristics of haemangiomas were similar in patients with normal compared to fibrotic and cirrhotic livers. Less T2 shine-through effect was seen in haemangiomas developed on cirrhosis, the latter being an important finding to highlight in these patients at risk of developing hepatocellular carcinoma.



**Nuclear medicine studies** — Technetium-99m pertechnetate-labeled red blood cell pool studies (99mTc-RBC pool studies) is a highly specific imaging technique for haemangiomas as its hypervascular nature may create equivocal result on CT or MRI <sup>44</sup>.

The study shows an initial hypoperfusion during arterial flow, which is followed by gradual increase of tracer peaking 30 to 50 minutes after the injection. Delayed images display retention of the isotope within the lesion. The sensitivity of the method has been found to be about 76%, specificity 98%, positive predictive value 98% and negative predictive value 79%. With SPECT (single photon emission computerized tomography), sensitivity of the method increases to 95%, specificity 98%, positive predictive value 98% and negative predictive value 94% <sup>45</sup>. RBC SPECT/CT imaging using this hybrid SPECT/CT system is feasible and useful in the identification or exclusion of suspected hepatic haemangiomas located near regions with high blood activity like the inferior vena cava, the heart or hepatic vessels <sup>46</sup>.

### Management

Hepatic haemangioma are mostly small and asymptomatic at the time of diagnosis, and they do generally tend to remain so or grow very slowly for the rest of the life. In addition, malignant transformation of these lesions has not been reported in literature. Hence most hepatic haemangioma may be left safely alone. However, there are rare cases in literature where the growth of these lesions has been rapid and consistent. Yoshida et al <sup>47</sup> reported an 11-fold growth in hepatic haemangioma over a period of 11 years, when the volume of the lesion had grown from 123 cc to 1343 cc.

### Radiologic study follow-up

Once the diagnosis of hepatic haemangioma is confirmed by radiologic studies, opinion varies whether follow-up radiologic studies are warranted to reassess the size of the lesion.

Yeh et al <sup>48</sup> followed up 180 hepatic haemangiomas in 130 adult patients, for more than 5 years with at least twice ultrasound examinations and found that the diameter of 14 (7.7%) haemangiomas in 13 patients increased and the lesion volume doubling time of ranged from 17.3 to 178.1 months. Kobayashi et al <sup>49</sup> evaluated consecutive ultrasonograms of 27 haemangiomas in 23 patients over a follow-up period ranging from 12 to 114 months (average 44) and found that six (22.2%) haemangiomas changed in size, which included three lesions with increase in size, one lesion with decrease in size and two lesions with spontaneous regression.

Hasan et al <sup>50</sup> in 2014 reported the results of a retrospective cohort study undertaken at an academic hospital tertiary referral centre to evaluate the growth rate of hepatic haemangiomas on cross-sectional imaging studies during a 10-year period (1997-2007). A total of 163 haemangiomas were identified in 123 patients and the mean (SD) initial size was 3.2 (cm). During follow-up, 39.3% of haemangiomas grew 5% or more in mean linear dimension and the mean (SD) annual linear growth rate was found out to be 0.03 (0.21) cm for all lesions and 0.19 (0.23) cm for those that grew 5% or more. By volume, 44.7% of lesions grew 5% or more and the mean (SD) annual volumetric growth rate was 2.8% (21.0%) for all lesions and 17.7% (22.8%) in those that grew 5% or more. The authors concluded that the overall rate of growth is slow but stressed the need for further research to determine the treatment modalities of the patients with more rapidly growing haemangiomas.

Ng et al <sup>51</sup> studied the giant hepatic haemangiomas with the median maximal diameter of the lesions was 5.5 cm (range, 4.0-20.3 cm) in 42 female and 22 male patients with a median age of 49 (range, 27-84) years. The median duration of follow-up was 34 months. Most (54%) of the

patients were asymptomatic, but in 17% the haemangioma enlarged to exceed its original size by more than 20%. There were no haemangioma-associated complications. The authors concluded that if the diagnosis is uncertain, selective further investigations may be necessary but the lesions with a confirmed diagnosis tend to remain static in size and hence performing regular scans for asymptomatic giant liver haemangiomas may not be necessary

### **Medical treatment**

Since 1990s, some cases were reported to show shrinkage of hepatic haemangiomas after interferon therapy <sup>52</sup>. In recent years, cases have been published which show reduction of haemangiomas by inhibition of growth factor and kinase. Mahajan D et al (53) in 2008 reported an incidental reduction in the size of liver haemangioma following use of vascular endothelial growth factor (VEGF) inhibitor bevacizumab.

Yamashita et al <sup>54</sup> reported the successful use of Sorafenib, multikinase inhibitor in the management of a 76-year-old man with a giant cavernous haemangioma measuring more than 20 cm in diameter. Tumour volume reduced from 1492 mL at baseline to 665 mL after 78 days of treatment with sorafenib 600 mg/day. Reports have been published in recent literature that point towards the efficacy of low dose propranolol, a non-selective beta-blocker, in the management of infantile hepatic haemangiomas <sup>55-56</sup>.

### **Surgical Treatment**

The major indications for elective surgical management of hepatic haemangioma <sup>57-59</sup> include abdominal pain, extrinsic compression of adjacent structures, cardiac failure, coagulopathy etc., diagnostic uncertainty and rapid enlargement whereas bleeding after rupture (60) or needle biopsy mandates emergent surgical intervention.

There are three procedures for surgical management of hepatic haemangiomas including:

1. Liver resection
2. Enucleation
3. Liver transplantation

The procedures are conducted by open approach or by minimally invasive (laparoscopic/robotic) approach<sup>1</sup>. The choice of the surgical procedure to be carried out depends upon the location and the morphology of the lesion <sup>59</sup>.

Martinez- Gonzalez et al <sup>59</sup> reported surgical management in 24 patients with symptomatic liver haemangiomas, 16 patients underwent liver resection (66.6%), and 8 lesions were enucleated (33.3%). Four patients (16.6%) presented operative complications including postoperative bleeding in two (8.3%), fever in one (4.1%) and abdominal haematoma in one (4.1%). There was no operative mortality. 22 patients (91%) achieved complete symptomatic relief. Demircan et al <sup>58</sup> operated upon 15 patients and 11 patients underwent enucleation of the lesion while the other 4 patients underwent resection procedures. Complications occurred in 2 (13.4%) patients and 1 patient with the largest tumour (30cm) died of bleeding and coagulopathy. One patient was lost to follow up and 12 out of the remaining 13 operated patients (92.3%) reported complete relief of symptoms. In the series of Kayaoglu et al <sup>57</sup>, enucleation was found to be safe and effective operation in 18 haemangiomas ranging in size from 2-30cm (mean 12.7cm). Ozden et al<sup>61</sup> and Popescu et al <sup>62</sup> also found enucleation to be rapid and safe and hence preferable over resection. But Guiliante et al <sup>63</sup> found resection and enucleation to be equally effective and safe and considered the size of the lesion to be responsible for complications rather than the choice of the procedure. Fu XH et al <sup>64</sup> presented the outcomes in 172 patients who underwent enucleation of hepatic haemangiomas. The lesions were centrally located in 76 patients (44.2%) and peripherally located in 96 patients (55.8%). The authors concluded that enucleation to be a safe surgery for haemangiomas in any

part of the liver, although it is technically more demanding for centrally than peripherally located haemangiomas. Baer et al<sup>13</sup> advocate routinely performing complete extra-hepatic ligation of the main arterial supply before attempting enucleation of a haemangioma to reduce blood loss and define the interface with the normal liver tissue.

Farges et al<sup>65</sup> had 50% of the operated patients with persistent symptoms during follow up and hence stressed on proper preoperative selection and work-up to rule out other causes of abdominal symptoms.

Liver transplantation has also been used successfully to treat selected symptomatic patients with unresectable giant or diffuse haemangiomas and haemangiomas associated with Kasabach-Merritt syndrome<sup>66-68</sup>. Surgical ligation of feeding vessels as a surgical technique is also mentioned in literature for the management of shunting liver haemangiomas that otherwise would rapidly lead to intractable cardiac failure. Rokitansky et al<sup>69</sup> in 1998 presented a successful usage of transhepatic compression sutures using polytetrafluoroethylene (PTFE) pledgets and selective ligation of large feeding vessels from right hepatic artery.

### **Arterial embolization**

Surgical resection may not be technically safe or possible in certain cases due to the massive or diffuse nature of the lesion, proximity to vascular structures, acute bleeding after spontaneous rupture or due the patient's general ill-health. In such situations, arterial embolization has been reported as an option in the literature to control acute bleeding, manage symptoms, and to shrink hemangiomas prior to surgical resection<sup>70-71</sup>. Branches of the hepatic artery are embolized with substances like fat, gel foam, bleomycin or polyvinyl alcohol.

Bozkaya H et al<sup>72</sup> in 2014 described successful embolization with bleomycin mixed with lipiodol of 32 symptomatic giant haemangiomas in 26 patients [21 female, five male; age 41-65 years (mean  $49.83 \pm 1.53$ )] who were otherwise unfit for surgical intervention. Angioembolization results in shrinkage of the lesion, thereby minimizing the risk of complications. The recognized complications of this procedure include pain, fever, abscess formation and non-granulomatous arteritis with eosinophilic infiltration. The long-term success rate of embolization (without subsequent surgical resection) is however not well studied as yet.

### **Radiotherapy**

Hepatic irradiation with a dose of 15-30 Gy in 15-22 fractions over several weeks has been used to treat symptomatic haemangiomas. Reports are published in literature since 1960s and the techniques of delivery have significantly improved over last decade. This modality is however generally reserved for unresectable lesions as it required months to deliver the required fractions of therapy. Tumour regression and symptom relief is noted in most patients, with minimal morbidity<sup>73-76</sup>.

### **Radiofrequency ablation**

In recent years, radiofrequency ablation (RFA) has emerged as a safe, feasible, and effective technique for treatment of giant symptomatic hepatic cavernous haemangiomas. Mode of delivery is through percutaneous, open surgical and laparoscopic routes. Van Tilborg et al<sup>77</sup> reported successful management of 4 patients with a large-volume, symptomatic hepatic cavernous haemangioma of >10 cm were treated with bipolar RFA during laparotomy with ultrasound guidance. Peri-procedural shrinkage of the lesions was remarkable and intermediate-term volume reduction ranged from 58-92% after 6 months. Symptom relief after 6 months was complete in two patients (50%) and considerable in the other two (50%).



Fan et al <sup>78</sup> presented a study of a total of 68 patients, 18 males and 50 females, age 43.1 (30-64), with 104 hepatic haemangiomas, 2.5-11 cm in diameter (mean size = 5.6 cm), who were treated by ultrasound-guided RFA, via percutaneous (n = 19), laparoscopic (n = 29), or open surgical (n = 20) approach. In 7 patients with hepatic lesions larger than 7 cm in diameter, Pringle's manoeuvre was used to occlude the hepatic blood flow during the laparoscopic and open RFA therapy. The authors concluded that RFA therapy to be a safe, feasible and effective treatment option and that hepatic inflow occlusion by Pringle's manoeuvre can reduce the blood loss and increase the therapeutic efficacy significantly.

Fan et al <sup>79</sup> presented the results of another series of 30 patients treated by RFA therapy after suture and ligation surgery (SL group, n = 15, with 18 liver lesions) or RFA therapy without suture and ligation surgery (non-SL group, n = 15, with 17 liver lesions) and concluded that RFA therapy combined with suture and ligation surgery is a safe, feasible, and effective treatment modality for giant hepatic haemangiomas and that it can reduce blood loss, shorten RFA therapy time, and increase therapeutic efficacy of RFA.

### **Role of Biopsy**

Due to the advances and wide availability of a range of diagnostic imaging modalities and the complications of biopsy including rupture, the imaging-guided biopsy of haemangioma is usually not resorted to, except in extremely atypical cases <sup>1</sup>.

### **Hepatic haemangiomas in pregnancy**

In spite of growth promoting influence of estrogens on hepatic haemangiomas<sup>8</sup>, the lesions generally behave indolently during pregnancy and can be observed <sup>80</sup>. However, there are rare reports in literature, where intervention was required on emergent basis due to complications like rupture and coagulopathy <sup>81</sup>.

### **Summary**

Hepatic haemangiomas are the commonest benign tumours of liver. They are usually diagnosed incidentally. Imaging modalities have made the diagnosis specific in recent years. They generally remain asymptomatic and do not require any active intervention or prolonged follow-up. For symptomatic, undefined or complicated lesions, surgical management is the main stay of therapy though other newer, less invasive modalities have come up in last few decades.

### **References**

1. Toro A, Mahfouz AE, Ardiri A, Malaguarnera M, Malaguarnera G, Loria F, Bertino G, Di Carlo I. What is changing in indications and treatment of hepatic hemangiomas. A review. *Ann Hepatol.* 2014; 13(4):327-39.
2. Moser C, Hany A, Spiegel R. Familial giant hemangiomas of the liver. Study of a family and review of the literature. *Praxis (Bern 1994).* 1998; 87(14):461-8.
3. Diez Redondo P, Velicia Llamas R, Caro-Paton A. Familial hepatic hemangiomas. *Gastroenterol Hepatol.* 2004; 27(5):314-6.
4. Li P, Wang Y, Zhang J, Geng M, Li Z. Dubin-Johnson syndrome with multiple liver cavernous hemangiomas: report of a familial case. *Int J Clin Exp Pathol.* 2013; 6(11):2636-9.
5. Glinkova V, Shevah O, Boaz M, Levine A, Shirin H. Hepatic haemangiomas: possible association with female sex hormones. *Gut.* 2004; 53(9):1352-5.
6. van Malenstein H, Maleux G, Monbaliu D, Verslype C, Komuta M, Roskams T, Laleman W, Cassiman D, Fevery J, Aerts R, Pirenne J, Nevens F. Giant liver hemangioma: the role of female sex hormones and treatment. *Eur J Gastroenterol Hepatol.* 2011; 23(5):438-43.
7. Spitzer D, Krainz R, Graf AH, Menzel C, Staudach A. Pregnancy after ovarian stimulation and intrauterine insemination in a woman with cavernous macrohemangioma of the liver. A case report. *J Reprod Med.* 1997; 42(12):809-12.

8. Graham E, Cohen AW, Soulen M, Faye R. Symptomatic liver hemangioma with intra-tumor hemorrhage treated by angiography and embolization during pregnancy. *Obstet Gynecol.* 1993; 81(5 ( Pt 2)):813-6.
9. Taseva A, Tasev V, Bonev S, Dimitrova V. Liver hemangiomas-surgical point of view. *Khirurgiia (Sofia).* 2014 ;( 2):63-8.
10. Isaacs H Jr. Fetal and neonatal hepatic tumors. *J Pediatr Surg.* 2007; 42(11):1797-803.
11. Moon HK, Kim HS, Heo GM, Shin WG, Kim KH, Jang MK, Lee JH, Kim HY, Kim DJ, Cho SJ. A case of pedunculated hepatic hemangioma mimicking submucosal tumor of the stomach. *Korean J Hepatol.* 2011; 17(1):66-70.
12. Kudara N, Chiba T, Andoh T, Tsukahara M, Oana S, Terui T, Endoh M, Inomata M, Orii S, Suzuki K, Uesugi N, Sugai T, Nakamura S, Yoshida T. A case of hepatic hemangioma with pedunculated extrahepatic growth simulating submucosal tumor of the stomach. *Nihon Shokakibyo Gakkai Zasshi.* 2004; 101(3):293-9.
13. Baer HU, Dennison AR, Mouton W, Stain SC, Zimmermann A, Blumgart LH. Enucleation of giant hemangiomas of the liver. Technical and pathologic aspects of a neglected procedure. *Ann Surg.* 1992;216(6):673
14. Bahirwani R, Reddy KR. Review article: the evaluation of solitary liver masses. *Aliment Pharmacol Ther.* 2008; 28(8):953-65.
15. Goodman Z. Benign tumors of the liver. In: Okuda K, Ishak KG. *Neoplasms of the liver.* Tokyo: Springer-Verlag; 1987:105-125.
16. Pudil J, Martinek J, Belsan T, Ryska M. Atypically localised hepatic haemangioma as a cause of dyspeptic syndrome. *Rozhl Chir.* 2006; 85(7):354-6.
17. Pateron D, Babany G, Belghiti J, Hadengue A, Menu Y, Flejou JF, Erlinger S, Benhamou JP. Giant hemangioma of the liver with pain, fever, and abnormal liver tests. Report of two cases. *Dig Dis Sci.* 1991; 36(4):524.
18. Kucherov IuV, Zhirkova IuV, Getman AN, Ivleva SA, Rekhviashvili MG. Clinical case of treatment of hepatic haemangioma by propranolol in the newborn. *Vestn Ross Akad Med Nauk.* 2014 ; (5-6):81-5.
19. Bruce S, Downe L, Devonald K, Ellwood D. Noninvasive investigation of infantile hepatic hemangioma: a case study. *Pediatrics.* 1995; 95(4):595.
20. Ito K, Taira K, Arii S. Intrahepatic bile duct dilatation with a liver cyst and hemangioma: report of a case. *Surg Today.* 2009; 39(3):256-60.
21. Mikami T, Hirata K, Oikawa I, Kimura M, Kimura H. Hemobilia caused by a giant benign hemangioma of the liver: report of a case. *Surg Today.* 1998; 28(9):948-52.
22. Birth M, Ortlepp J, Bontikous S, Amthor M, Weiser HF, Bruch HP. Intermittent activity-induced hemobilia caused by liver hemangioma. *Dig Surg.* 2000; 17(3):292-6.
23. Lee CW, Chung YH, Lee GC, Kim JY, Lee JS. A case of giant hemangioma of the liver presenting with fever of unknown origin. *J Korean Med Sci.* 1994; 9(2):200-4.
24. van Gorcum M, van Buuren HR, Hussain SM, Zondervan PE, IJzermans JN, de Man RA. Fever as a sign of inflammatory syndrome in a female patient with hepatic haemangioma. *Ned Tijdschr Geneesk.* 2005; 149(22):1227-30.
25. Bessho K, Etani Y, Ichimori H, Miyoshi Y, Namba N, Yoneda A, Ooue T, Chihara T, Morii E, Aoki T, Murakami M, Mushiake S, Ozono K. Increased type 3 iodothyronine deiodinase activity in a regrown hepatic hemangioma with consumptive hypothyroidism. *Eur J Pediatr.* 2010; 169(2):215-21.
26. Kadry Z, Mentha G, Cereda JM. Polymyalgia rheumatica as a manifestation of a large hepatic cavernous hemangioma. *J Hepatol.* 2000; 32(2):358.
27. Watzke HH, Linkesch W, Hay U. Giant hemangioma of the liver (Kasabach-Merritt syndrome): successful suppression of intravascular coagulation permitting surgical removal. *J Clin Gastroenterol.* 1989; 11(3):347-50.
28. Wakabayashi S, Yamaguchi K, Kugimiya T, Inada E. Successful anesthetic management for resection of a giant hepatic hemangioma with Kasabach-Merritt syndrome using FloTrac system. *Masui.* 2011; 60(11):1326-30.
29. Vogel T, Lammers B, von Herbay A, Kunz BM, Donner AJ, Furst G, Goretzki PE. Kasabach-Merritt syndrome in giant hemangioma of the liver. A case report. *Chirurg.* 2002; 73(7):729-32.
30. Hughes JA, Hill V, Patel K, Syed S, Harper J, De Bruyn R. Cutaneous haemangioma: prevalence and sonographic characteristics of associated hepatic haemangioma. *Clin Radiol.* 2004; 59(3):273.

31. O'Neill EK, Cogley JR, Miller FH. The ins and outs of liver imaging. Clin Liver Dis. 2015; 19(1):99-121.
32. Klotz T, Montoriol PF, Da Ines D, Petitcolin V, Joubert-Zakeyh J, Garcier JM. Hepatic haemangioma: common and uncommon imaging features. Diagn Interv Imaging. 2013; 94(9):849-59.
33. Cha EY, Kim KW, Choi YJ, Song JS, Cho KJ, Lee MG. Multicystic cavernous haemangioma of the liver: ultrasonography, CT, MR appearances and pathological correlation. Br J Radiol. 2008; 81(962):e37-9.
34. Choi SH, Kim KW, Hong GS, Lee SJ, Kim SY, Lee JS, Kim HJ. Sonography of hepatic hemangioma accompanied by arterioportal shunt. Clin Mol Hepatol. 2014; 20(1):85-7.
35. Lim KJ, Kim KW, Jeong WK, Kim SY, Jang YJ, Yang S, Lee JJ. Colour Doppler sonography of hepatic haemangiomas with arterioportal shunts. Br J Radiol. 2012; 85(1010):142-6.
36. Dietrich CF, Mertens JC, Braden B, Schuessler G, Ott M, Ignee A. Contrast-enhanced ultrasound of histologically proven liver hemangiomas. Hepatology. 2007; 45(5):1139-45.
37. Sirli R, Sporea I, Popescu A, Danila M, Martie A, Bota S, Jurchis A, Sendroiu M. Contrast enhanced ultrasound for the diagnosis of liver hemangiomas in clinical practice. Med Ultrason. 2011; 13(2):95-101.
38. Ryu SW, Bok GH, Jang JY, Jeong SW, Ham NS, Kim JH, Park EJ, Kim JN, Lee WC, Shim KY, Lee SH, Kim SG, Cha SW, Kim YS, Cho YD, Kim HS, Kim BS. Clinically useful diagnostic tool of contrast enhanced ultrasonography for focal liver masses: comparison to computed tomography and magnetic resonance imaging. Gut Liver. 2014; 8(3):292-7.
39. Bilello M, Gokturk SB, Desser T, Napel S, Jeffrey RB Jr, Beaulieu CF. Automatic detection and classification of hypodense hepatic lesions on contrast-enhanced venous-phase CT. Med Phys. 2004; 31(9):2584-93.
40. Dankerl P, Cavallaro A, Tsymbal A, Costa MJ, Suehling M, Janka R, Uder M, Hammon M. A retrieval-based computer-aided diagnosis system for the characterization of liver lesions in CT scans. Acad Radiol. 2013; 20(12):1526-34.
41. Taouli B, Koh DM. Diffusion-weighted MR imaging of the liver. Radiology. 2010; 254(1):47-66.
42. Agnello F, Ronot M, Valla DC, Sinkus R, Van Beers BE, Vilgrain V. High-b-value diffusion-weighted MR imaging of benign hepatocellular lesions: quantitative and qualitative analysis. Radiology. 2012; 262(2):511-9.
43. Duran R, Ronot M, Di Renzo S, Gregoli B, Van Beers BE, Vilgrain V. Is magnetic resonance imaging of hepatic hemangioma any different in liver fibrosis and cirrhosis compared to normal liver? Eur J Radiol. 2015; 84(5):816-22.
44. Borse R, Mahapatra GN, Meht R, Plumber S, Dhuri S, Ali S. Scintigraphic finding of a silent hepatic haemangioma. J Assoc Physicians India. 2010; 58:637-40.
45. Artiko MV, Sobic-Saranovic PD, Perisic-Savic SM, Stojkovic VM, Radoman BI, Knezevic SJ, Petrovic SN, Obradovic BV, Milovic V. 99mTc-red blood cells SPECT and planar scintigraphy in the diagnosis of hepatic hemangiomas. Acta Chir Jugosl. 2008; 55(4):23-6.
46. Schillaci O, Danieli R, Manni C, Capocchetti F, Simonetti G. Technetium-99m-labelled red blood cell imaging in the diagnosis of hepatic haemangiomas: the role of SPECT/CT with a hybrid camera. Eur J Nucl Med Mol Imaging. 2004; 31(7):1011-5.
47. Yoshida J, Yamasaki S, Yamamoto J, Kosuge T, Takayama T, Hasegawa H, Takayasu K, Muramatsu Y, Moriyama N, Hirohashi S. Growing cavernous haemangioma of the liver: 11-fold increase in volume in a decade. J Gastroenterol Hepatol. 1991; 6(4):414-6.
48. Yeh WC, Yang PM, Huang GT, Sheu JC, Chen DS. Long-term follow-up of hepatic hemangiomas by ultrasonography: with emphasis on the growth rate of the tumor. Hepatogastroenterology. 2007; 54(74):475-9.
49. Kobayashi T, Kawano M, Tomita Y, Tamano T, Saegusa S, Horinaka M, Monma T, Oguma M, Yanagisawa N, Ohe T. Follow-up study of hepatic hemangiomas. Nihon Shokakibyo Gakkai Zasshi. 1995; 92(1):41-6.
50. Hasan HY, Hinshaw JL, Borman EJ, Gegios A, Levenson G, Winslow ER. Assessing normal growth of hepatic hemangiomas during long-term follow-up. JAMA Surg. 2014; 149(12):1266-71.
51. Ng WW, Cheung YS, Lee KF, Wong J, Yu SC, Lee PS, Lai PB. Is regular follow-up scan for giant liver haemangioma necessary? Hong Kong Med J. 2007; 13(5):353-8.
52. Yanai S, Tsutsumi H, Hotsubo T, Takahashi A, Miyao N, Satoh M, Chiba S. Development of a testicular haemangioma after interferon therapy for hepatic haemangiomas: a case report. Eur J Pediatr. 1997; 156(10):784-6.

53. Mahajan D, Miller C, Hirose K, McCullough A, Yerian L. Incidental reduction in the size of liver hemangioma following use of VEGF inhibitor bevacizumab. *J Hepatol.* 2008; 49(5):867-70.
54. Yamashita S, Okita K, Harada K, Hirano A, Kimura T, Kato A, Okita K. Giant cavernous hepatic hemangioma shrunk by use of sorafenib. *Clin J Gastroenterol.* 2013; 6(1):55-62.
55. Kuchеров IuI, Zhirkova IuV, Getman AN, Ivleva SA, Rekhviashvili MG. Clinical case of treatment of hepatic haemangioma by propranolol in the newborn. *Vestn Ross Akad Med Nauk.* 2014;(5-6):81-5.
56. Muthamilselvan S, Vinoth PN, Vilvanathan V, Ninan B, Amboiram P, Sai V, Anand V, Scott JX. Hepatic haemangioma of infancy: role of propranolol. *Ann Trop Paediatr.* 2010; 30(4):335-8.
57. Kayaoglu HA, Hazinedaroglu S, Ozkan N, Yerdel MA. Surgical treatment of symptomatic cavernous hemangiomas of the liver. *Acta Chir Belg.* 2004; 104(2):172-4.
58. Demircan O, Demiryurek H, Yagmur O. Surgical approach to symptomatic giant cavernous hemangioma of the liver. *Hepatogastroenterology.* 2005; 52(61):183-6.
59. Martinez-Gonzalez MN, Mondragon-Sanchez R, Mondragon-Sanchez A, Gomez-Gomez E, Garduno-Lopez AL, Bernal-Maldonado R, Onate-Ocana LF, Ruiz-Molina JM. Cavernous hemangioma of the liver and hepatic hemangiomatosis. Indications and results of the surgical resection. *Rev Gastroenterol Mex.* 2003; 68(4):277-82.
60. De Beul P, Roels P, Heirwegh G, Janssen A, Claijens B. Spontaneous rupture: a rare complication of hepatic hemangiomas. *JBR-BTR.* 2014; 97(5):287-8.
61. Ozden I, Emre A, Alper A, Tunaci M, Acarli K, Bilge O, Tekant Y, Ariogul O. Long-term results of surgery for liver hemangiomas. *Arch Surg.* 2000; 135(8):978.
62. Popescu I, Ciurea S, Brasoveanu V, Hrehoret D, Boeti P, Georgescu S, Tulbure D. Liver hemangioma revisited: current surgical indications, technical aspects, results. *Hepatogastroenterology.* 2001; 48(39):770.
63. Giuliani F, Ardito F, Vellone M, Giordano M, Ranucci G, Piccoli M, Giovannini I, Chiarla C, Nuzzo G. Reappraisal of surgical indications and approach for liver hemangioma: single-center experience on 74 patients. *Am J Surg.* 2011; 201(6):741-8.
64. Fu XH; Lai EC; Yao XP; Chu KJ; Cheng SQ; Shen F; Wu MC; Lau WY. Enucleation of liver hemangiomas: is there a difference in surgical outcomes for centrally or peripherally located lesions? *Am J Surg.* 2009; 198(2):184-7.
65. Farges O; Daradkeh S; Bismuth H. Cavernous hemangiomas of the liver: are there any indications for resection? *World J Surg.* 1995; 19(1):19-24.
66. Vagefi PA, Klein I, Gelb B, Hameed B, Moff SL, Simko JP, Fix OK, Eilers H, Feiner JR, Ascher NL, Freise CE, Bass NM. Emergent orthotopic liver transplantation for hemorrhage from a giant cavernous hepatic hemangioma: case report and review. *J Gastrointest Surg.* 2011; 15(1):209-14.
67. Meguro M, Soejima Y, Taketomi A, Ikegami T, Yamashita Y, Harada N, Itoh S, Hirata K, Maehara Y. Living donor liver transplantation in a patient with giant hepatic hemangioma complicated by Kasabach-Merritt syndrome: report of a case. *Surg Today.* 2008; 38(5):463-8.
68. Kumashiro Y, Kasahara M, Nomoto K, Kawai M, Sasaki K, Kiuchi T, Tanaka K. Living donor liver transplantation for giant hepatic hemangioma with Kasabach-Merritt syndrome with a posterior segment graft. *Liver Transpl.* 2002; 8(8):721-4.
69. Rokitansky AM, Jakl RJ, Gopfrich H, Voithl P, Anzbock W, Wassipaul M, Sacher M, Hruby W. Special compression sutures: a new surgical technique to achieve a quick decrease in shunt volume caused by diffuse hemangiomatosis of the liver. *Pediatr Surg Int.* 1998; 14(1-2):119-21.
70. Jain V, Ramachandran V, Garg R, Pal S, Gamanagatti SR, Srivastava DN. Spontaneous rupture of a giant hepatic hemangioma - sequential management with transcatheter arterial embolization and resection. *Saudi J Gastroenterol.* 2010; 16(2):116-9.
71. Lupinacci RM, Szejnfeld D, Farah JF. Spontaneous rupture of a giant hepatic hemangioma. Sequential treatment with preoperative transcatheter arterial embolization and conservative hepatectomy. *G Chir.* 2011; 32(11-12):469-72.
72. Bozkaya H, Cinar C, Besir FH, Parlilar M, Oran I. Minimally invasive treatment of giant haemangiomas of the liver: embolisation with bleomycin. *Cardiovasc Intervent Radiol.* 2014; 37(1):101-7.
73. Issa P. Cavernous haemangioma of the liver: the role of radiotherapy. *Br J Radiol.* 1968; 41(481):26-32.
74. Okazaki N, Yoshino M, Yoshida T, Ohno T, Kitagawa T. Radiotherapy of hemangioma cavernosum of the liver. *Gastroenterology.* 1977; 73(2):353-6.

75. McKay MJ, Carr PJ, Langlands AO. Treatment of hepatic cavernous haemangioma with radiation therapy: case report and literature review. *Aust N Z J Surg.* 1989; 59(12):965-8.
76. Lee HL, Chung TS, Chen SW, Lao WT. CT and MRI findings correlate with the time-course of unresectable cavernous haemangioma of the liver after fractionated radiotherapy. *Br J Radiol.* 2012; 85(1011):e49-52.
77. van Tilborg AA, Nielsen K, Scheffer HJ, van den Tol P, van Waesberghe JH, Sietses C, Meijerink MR. Bipolar radiofrequency ablation for symptomatic giant (>10 cm) hepatic cavernous haemangiomas: initial clinical experience. *Clin Radiol.* 2013; 68(1):e9-e14.
78. Fan RF, Chai FL, He GX, Li RZ, Wan WX, Bai MD, Zhu WK, Cao ML, Li HM, Yan SZ. Clinical evaluation of radiofrequency ablation therapy in patients with hepatic cavernous hemangiomas. *Zhonghua Yi Xue Za Zhi.* 2005 ;85(23):1608-12.
79. Fan RF, Chai FL, He GX, Wan WX, Bai MD, Cao ML, Li HM, Yan SZ. Radiofrequency ablation therapy combined with suture and ligation surgery for patients with giant cavernous hemangiomas of the liver. *Zhonghua Yi Xue Za Zhi.* 2006; 86(30):2134-7.
80. Cobey FC, Salem RR. A review of liver masses in pregnancy and a proposed algorithm for their diagnosis and management. *Am J Surg.* 2004; 187(2):181.
81. Ebina Y, Hazama R, Nishimoto M, Tanimura K, Miyahara Y, Morizane M, Nakabayashi K, Fukumoto T, Ku Y, Yamada H. Resection of giant liver hemangioma in a pregnant woman with coagulopathy: Case report and literature review. *J Prenat Med.* 2011; 5(4):93-6.