

Separation of Conjoined Twins in Harare, Zimbabwe: Case Report.

F D Madzimbamuto¹, B Mbuwayesango², T Zimunhu².

¹Department of Anaesthesia and Critical Care Medicine

Department of Health Professions Education.

²Department of Surgery, University of Zimbabwe College of Health Sciences

Correspondence to: FD Madzimbamuto, Email: faraitose@hotmail.com

Conjoined twins are rare, and those surviving beyond the first 24hrs occur about 1:200,000 pregnancies. There are often conflicting interests in their management. Medically, few are separable. The families may not want separation for emotional, religious and ethical reasons. Technically the surgery is often difficult and resource intensive. The occurrence of conjoined twins in a resource poor setting presents all these challenges. We present a case of successful elective separation of conjoined twins, in a resource poor setting.

Key words: Conjoined, twins, separation

DOI: <http://dx.doi.org/10.4314/ecajs.v21i3.15>

Introduction

The following is a case review of our experience with separation of a pair of male conjoined twins undertaken at Harare Children's Hospital, Zimbabwe.

Case Presentation

Two male babies were delivered by caesarean section at a district hospital, and found to be conjoined twins. They were transferred to the Harare Children's Hospital where they were admitted and investigated to establish an anatomical diagnosis, under the care of the paediatricians. Clinically they were well looking and had a joint birth weight of 3.65kg. They were breastfeeding well and put on weight. Twin A was smaller than twin B.

The anatomical diagnosis was thoraco-omphalo-pagus, made by radiological investigation. The twins were joined from sternum to umbilicus and had separate gastrointestinal tracts. The livers were conjoined but did not appear to share circulation. The pericardia were conjoined but appeared to have a plane between them. The hearts were separate with no cardiac abnormalities. There was continuity of abdominal muscle and skin from one twin to the other. [Fig 1]

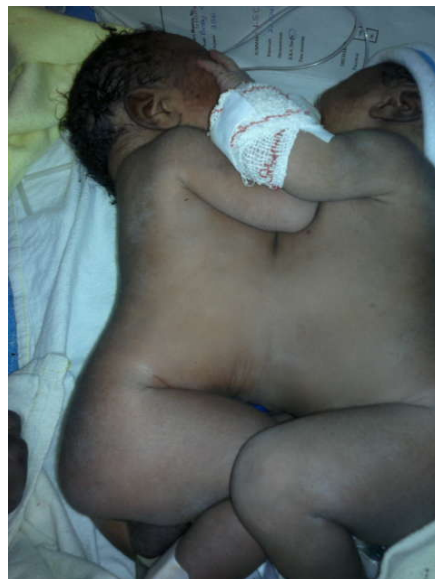

Figure 1. Conjoined twins preoperatively

The initial anaesthetic assessment of the twins for separation was at six weeks when their joint weight was 6.4kgs. Laboratory results were almost the same for each twin for full blood count and electrolytes. The larger twin [Twin B] appeared easier to intubate, and could adequately laterally rotate his head for a laryngoscopy to be performed with ease. The area of abdominal wall attachment was large, which raised concerns about potential blood loss and respiratory embarrassment post-operatively. The twins had good veins, leaving the option of inhalation or intravenous induction open. The extent of cross-circulation was unquantified, also raising concerns about anaesthetic drugs crossing from one twin to the other especially at induction since this was going to be done sequentially. This could be a potential problem at separation. If one twin was dependant on the anaesthetic crossing from the other twin to achieve a suitable depth of anaesthesia, separation would then expose that twin to risk of lightening anaesthesia and waking up.

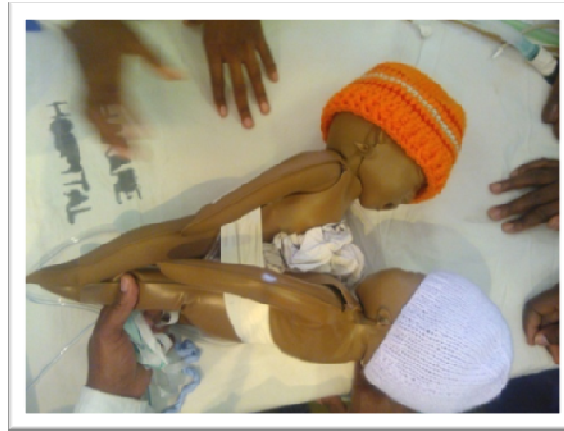

Figure 2. Use of manikins for practice drill-runs. The team responsible for each baby was identified by the colour of the baby's hat, and wore a similar colour hat

The Procedure

In preparation, two anaesthetic, surgical and nursing teams were established to prepare, practice drill-runs and perform the separation. The practice drills were crucial for the appreciation of the spatial positioning of the babies, sequencing of the operation and associated intraoperative events [Fig 2]. The separation was done at 10 weeks and 5 days, when the twins' joint weight was 8.2kgs. Anaesthetic and surgical equipment was available in duplicate in theatre. The babies were placed on the theatre table in a pre-determined orientation so that each baby and his team were on one side of the theatre. A sevoflurane inhalation induction was done sequentially starting with twin B, and intubations with size 4.0 endotracheal tubes were performed after establishing intravenous access for each baby [Fig 3]. The BiSpectral Index (BIS) was used to monitor the induction of anaesthesia in both twins. Twin A seemed to sleep when twin B (the first one) was induced although his BIS remained at 97%. Fentanyl and atracurium were given intravenously for analgesia as needed. Drugs and fluids were calculated for the combined body weight and given in a ratio of 60:40 between twins B:A, based on a visual estimate of relative sizes. Attempts to site central venous lines in both babies were unsuccessful despite ultrasound guidance.

After induction and skin preparation, the babies were turned over for surgery to begin on the 'down' side, in order to free the skin. The approximate centre between the two babies was marked for the skin incision. The muscles were divided also until the peritoneum was exposed but left intact. Haemostasis was achieved and the wound packed with gauze. Monitoring cables, intravenous fluid lines and ventilation tubes were crossed during this period. After release of the skin the babies were turned again so the planned operative side was now the 'up' side for the rest of the operation. Lines were then uncrossed. Another incision in the approximate centre was made and extended to the peritoneum. Unipolar diathermy was used for both cutting and coagulation. The peritoneal sac was opened. All viscera

were separate and intact except for the livers which were joined. Each baby had a separate gastrointestinal tract down to the anus, separate genitourinary system and spleens. The liver was fused in the midline, but the biliary systems and pancreas were separate. The liver was divided down the midline. The xiphisternum and lateral costal margins were fused anteriorly; division was easily accomplished. The pericardial sacs were fused in the midline with a small window connecting them. These were separated and the window closed. The diaphragms were separate with no hernias. The babies were then detached from each other and placed on separate tables in the same operating theatre. The estimated combined blood loss was 70mls, about 10% of their total blood volume. Twin B was transfused 40mls while twin A was given 30mls.

The abdominal wall defect was too large in each baby to effect primary closure. This was achieved with mesh but the skin was left open to allow shrinkage and granulation over time [Fig 4].

Intravenous fluids, blood loss and urine were calculated hourly to keep up with fluid balance. Monitoring consisted of pulse oximetry, non-invasive blood pressure, electrocardiogram, core temperature, BiSpectral Index, end-tidal carbon dioxide. Sevoflurane was monitored for both inspired and expired gas fraction and minimum alveolar concentration (MAC).

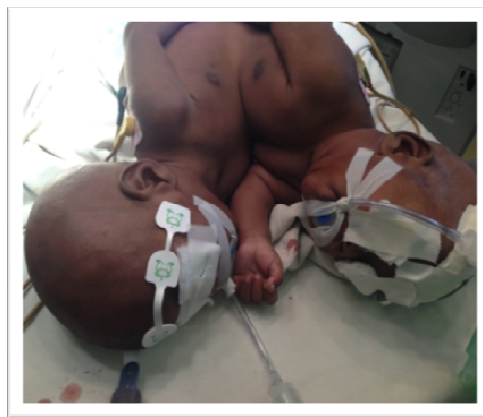

Figure 3. Both babies intubated and monitors positioned.

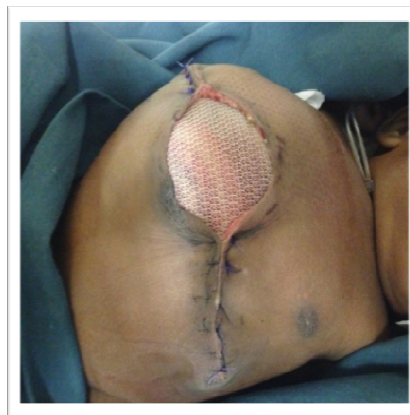


Figure 4. Mesh closure of abdominal wall at end of surgery

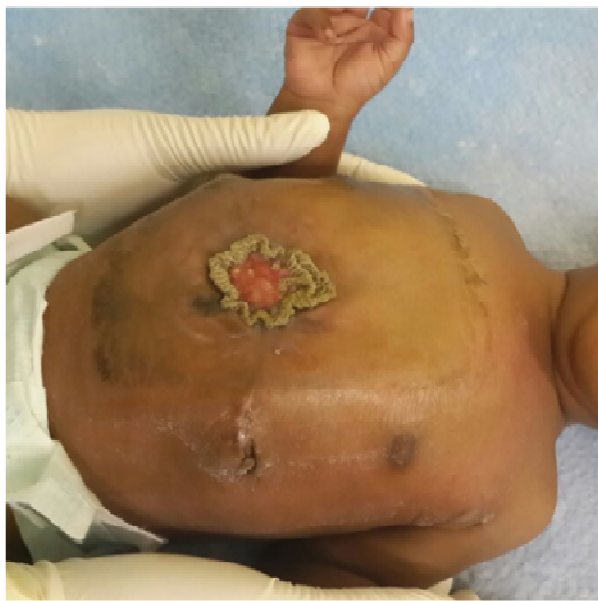

Figure 5. At Follow up, defect almost closed.




Figure 6. Sculpture by Zimbabwean artist Zephania Tshuma 'Separation' [courtesy of Dr David Katzenstein]

Post operative management:

Both babies were admitted ventilated to ICU, sedated with fentanyl and ketamine infusions. Baby B had a stormy recovery in ICU for the first 48 hours with periods of low urine output. Both babies were extubated within 18hrs and started on naso-gastric breast milk feeds at 36hrs. By 48hrs they had both recovered very well and were able to breast feed orally. They were discharged home at two weeks when most of the mesh had been removed [Fig 5]. Regular outpatient reviews followed and their last surgical review was done at 18 months with good progress and the twins growing well.

Discussion

The incidence of conjoined twins is quoted to be between 1:50 000 to 1:100 000 pregnancies ¹. About 60% die in-utero or are stillborn, making the incidence of those born alive nearer 1:200 000. A significant proportion of these die in the first 24 hrs.¹ Based on this incidence, it would be expected that one set of live conjoined twins would be born every five years in the Greater Harare Maternity Unit with approximately 40 000 deliveries a year. In 1985, a set of conjoined twins were successfully separated at Harare Central Hospital but not reported ². In 2005 a set of conjoined twins from Chiweshe district, in north east Zimbabwe, were transferred for separation to Canada, and are now healthy 10 year-old boys ³. Shortly after the currently reported conjoined twin separation was performed, another case was reported in the press ⁴. In 1983 Viljoen ⁵ reported on conjoined deliveries in Namibia, South Africa and Zimbabwe, reporting that Zimbabwe showed the highest incidence.

Fully separate twins achieve complete separation in-utero by day 15-17 post-fertilization. The 'fission' theory suggests that failure to achieve separation results in conjoined twins, based on the conjoined twins always being identical ⁶. The 'fusion' theory suggests that in twins that are fully separate but physically close, 'like' embryonic cells migrate between them, so potential liver cells in one can migrate to be liver cells in the other. An intrauterine diagnosis can be made by ultrasound from 12 weeks, and organ conjunction can be diagnosed from 20 weeks by ultrasound. The presence of fluid in the foetal lungs makes cardiac echocardiography easier and cardiac abnormalities can be diagnosed and followed from 20 weeks⁷. Heart and lung abnormalities are the main cause of non-viable fetuses.

The type of conjoinedness is classified according to Spenser et al as symmetric or asymmetric ⁸. 'Pagus' refers to the place of joining or 'fixing / frozen' (Greek). There are three categories of symmetric conjoined twins: anterior (ventral) pagus, posterior (dorsal) pagus and lateral pagus.

The medical literature on conjoined twins consists mainly of case reports of single cases of conjoined twins or rarely a series of a few cases going back 20 or more years^{6,9-12}. Developments have mostly been in early intrauterine diagnosis, especially using ultrasound in diagnosis of twin pregnancies and preoperative anatomical diagnosis. This enables medical management and counselling to be well planned for a suitable outcome for both family and medical team ^{7,12}. The surgery of separation of conjoined twins is generally complex and resource intensive. Only a small proportion of conjoined twins are amenable to surgical separation. In a Brazilian series over 20 years, out of 21 pairs of conjoined twins, 12 pairs were amenable to surgery and 16 infants out of the 24 (66%) survived.⁷ In a South African series only one set out of three sets of conjoined twins having emergency surgery survived compared to 11 out of 14 sets who had elective surgery ¹².

Separation of conjoined twins where one of the twins is certainly or most likely not going to survive has resulted in religious, legal and moral uncertainty. There are also questions about whether conjoined twins are one or two persons and what constitutes beneficence and non-maleficence in this context ^{13,14}. The decision to operate or not to operate is usually taken by people other than the children: parents, surgeons, courts etc and what is in the best interests of the children can be conflicted. Many conjoined twins who have survived childhood to adulthood have not wanted separation, depending on the risk to themselves. Families are often reluctant to have separation if there is a risk of sacrifice of one of the twins.

Conjoined twins have fascinated society for millennia, from being shrouded in superstition and religion, to being exhibited as circus freaks and the wonder of successful surgery ¹⁵. There are historical records of conjoined twins from as early as six millennia BC, such as the 'double goddess' ⁶. Many young African medical students today state as their inspiration to study medicine the story of Ben Carson, the African-American paediatric neurosurgeon who was the first to successfully separate craniopagus twin ¹⁶.

The key lesson from this case is that surgical separations are possible for some cases in resource-limited settings if conducted with thorough and adequate preparation and planning. This preparation is not isolated to the surgical process but involves the entire journey from diagnosis to successful child development. The groundwork for the case presented in this report involved use of counselling services to establish the parents' wishes and anxieties and to ensure full commitment to the surgery. For the medical team, there were concerns based on previous experience that if the children went home before surgery, they may not return and may face possible harm or neglect. According to Pathisa Nyathi, 'Multiple births have traditionally caused alarm and apprehension among African societies' ¹⁷. Historically in Zimbabwe twins were regarded as bad omens and were left to die. Although this no longer happens, children who are "different" are regarded with superstitious concern in many African communities. There are also religious sects that counsel against medical intervention of any kind. In the case presented here, the parents were very keen to have the babies separated and to look after them well. To give the maximum chance of a surgical outcome, the children were kept in the hospital for the whole preoperative period. The medical and nursing teams worked together closely for four weeks discussing and planning the operation so that a common understanding developed about how the babies and parents would be looked after. As with other 'separation' operations, there was a lot of media and public interest both local and international in these twins, and pride on the part of the health system when the outcome was successful.

Acknowledgements:

Prof Ray for reviewing manuscript.

Surgical team	Anaesthetic team	Nursing team
Mbuwayesango B, [Consultant: team blue: leader] Zimunhu T [Consultant: team red: leader] Chitsika E [Consultant] Dube I [Consultant] Muteweye W [Consultant: Cardiothoracics] Munanzvi K [House Officer] Moyo M [House Officer] Mutambanengwe P [House Officer] Muparadzi C [House Officer] Mushonga M [House Officer] Gwatorisa [House Officer]	Chifamba HN [Consultant: team leader] Shumbairerwa S [Consultant: team red-lead] Madzimbamuto FD [Consultant: team blue-lead] Mutetwa E [Senior Reg] Chimhundu-Sithole T [Registrar] Mugadza F [Registrar] Mazonde S [Consultant] Chikumba E [Consultant] Nyamayaro RT (Consultant) Mutukwa T (Registrar)	Shaka I [Matron] Charumbira C [Matron] Bikisoni P [Theatre Sister-in-Charge] Simbini B [Operating Theatre Nurse-OTN] Rutsito M [Lead blue team-Operating Theatre Nurse] Maarira [Lead red team-Operating Theatre Nurse] Paediatric team Chimhini G [Consultant] Chimhuya S [Consultant]

References

- Martínez-Frías ML, Bermejo E, Mendioroz J et al. Epidemiological and clinical analysis of a consecutive series of conjoined twins in Spain. *Journal of Pediatric Surgery* 2009; 44: 811-820.
- Marks L, Dunkley A. [personal communication. 2015].
- G Eagle. Surviving in Zimbabwe: conjoined twins separated in Canada alive and well. *The Peterborough Examiner*. February 5, 2011. At www.thepeterboroughexaminer.com/2011/02/05/surviving-in-zimbabwe-conjoined-twins-separated-in-canada-alive-and-well (accessed 1 Oct 2015)
- New Zimbabwe News. Mt Darwin woman gives birth to conjoined twins. <http://www.newzimbabwe.com/news18027Couple+in+shock+over+conjoined+twins/news.aspx>
- Viljoen DL, Nelson MM, Beighton P. The epidemiology of conjoined twinning in Southern Africa. *Clinical Genetics* 1983;24: 15-21
- Lewis S. Hunterian Lecture: Surgery for conjoined twins. *Ann R Coll Surg Engl* 2003; 85: 230-235
- Kingston CA, McHugh K, Kumara Devan J et al. Imaging in the Preoperative Assessment of Conjoined Twins. *RadioGraphics* 2001; 21:1187-1208
- Spencer R. Anatomic Description of Conjoined Twins: A Plea for Standardized Terminology *Journal of Pediatric Surgery*, 1996;31(7): pp 941-944

9. Lalwani J, Bubey KP, Shah P. Anaesthesia for the separation of conjoined twins. *Indian J Anaesth* 2011;55:177-80. DOI: 10.4103/0019-5049.79902
10. Tannuri AC, Batatinha JA, Velhote MC, Tannuri U. Conjoined twins – twenty years' experience at a reference center in Brazil. *Clinics*. 2013;68:371-377.
11. Rode H, Fieggen AG, Brown RA et al. Four decades of conjoined twins at Red Cross Children's Hospital – lessons learned. *SAMJ* 2006;96: 10.
12. Thomas JM, Lopez JT. Conjoined twins – the anaesthetic management of 15 sets from 1991–2002 *PediatricAnesthesia* 2004 14: 117–129
13. Paris JJ, Elias-Jones AC. "Do we murder Mary to save Jodie?" An ethical analysis of the separation of the Manchester conjoined twins. *Postgrad Med J* 2001;77:593–598
14. Lee M, Gosain A K, Becker, D. The Bioethics of Separating Conjoined Twins in Plastic Surgery. *Plastic and Reconstructive Surgery*. 2011;128:328e–334e. DOI: 10.1097/PRS.0b013e3182268c54
15. Orser JA. *The Lives of Chang and Eng: Siam's Twins in Nineteenth-Century America*. University of North Carolina Press , Chapel Hill. 2014
16. Carson B, Murphey C. *Gifted Hands: The Ben Carson Story*. Publisher: Zondervan : Grand Rapids, Michigan. 1991
17. NyathiPathisa. The myths surrounding multiple births. *Zimbabwe's Cultural Heritage*. Page 40-42. Amabooks. Bulawayo. 2005