

[www.ajbrui.net](http://www.ajbrui.net)

*Afr. J. Biomed. Res. Vol.15 (May 2012); 93 - 96*

*Research Article*

## **Palmar Flexion Creases Variants among Nigerians**

**<sup>1</sup>Adetona M. O., <sup>1,2</sup>Oladapo O. O. and <sup>3</sup>Akinyemi J. O.**

<sup>1</sup>*Department of Anatomy, College of Medicine, University of Ibadan.*

<sup>2</sup>*Department of Medicine, College of Medicine, University of Ibadan.*

<sup>2</sup>*Department of Epidemiology, Medical Statistics and Environmental Health, University of Ibadan*

---

**ABSTRACT:** Line formations of the palm (palmar flexion creases) as part of field of dermatoglyphics can be used for non-invasive investigations of congenital abnormalities. Numerous studies have found correlation between line patterns, diseases and psychological conditions. The pattern of palmar flexion creases had been studied in some Caucasian and Asian populations, but not much had been written about sub-saharan Africa populations. Four hundred and thirty five palmar prints of healthy volunteered Nigerians, comprising 259 males and 166 females aged 14 and 70 years were randomly sampled. The prints were taken using the Antonuk's ink method. Prints were examined for normal variants of flexion creases based on classification defined by Milton and Cummins. Pattern lines A, B and C were the most common patterns among Hausa, Igbo and Yoruba ethnic groups, while lines D to G patterns vary in frequency from 86% to absence of pattern G among Hausa and Igbo ethnic groups. Other variants of extra line pattern on thenar eminence, numerous criss-crossing patterns, double line A and double line B, M pattern type of lines A, B, C and D were found to be present among the ethnic groups. Simian crease pattern: 0.5% on right hand and 0.2% were found to be normal among Nigerians. Normal palmar flexion crease identification based on this study elucidates normal variants lines A to G and other uncommon but normal variants within the Nigeria population.

**Key words:** Palmar flexion creases, ethnic groups, Nigerians

---

### **INTRODUCTION**

Line formations of the palm as part of field of dermatoglyphics can be used for non-invasive investigations of congenital abnormalities. The pattern of palmar flexion creases had been studied in some Caucasian and Asian populations, but not much had been written about sub-Saharan Africa populations. Numerous studies have found correlation between line patterns and different diseases and psychological conditions (Schaumann and Kimura, 1991). Unusual palmar flexion creases have been reported in Down's syndrome (Penrose and Smith, 1966), trisomy (Uchida

and Smith 1962), Cri du-chat syndrome (Hijmans and Shearin, 1965) and prenatal rubella (Achs *et al.*, 1966). Palmar flexion creases develop in the embryo (Poch, 1925) and are readily evident at birth. Physician may inspect them during the perinatal examination for early diagnosis of congenital anomalies. The recognition of unusual configurations demands that normal variants must be recognized; therefore systematic study of palmar creases in individuals who seem quite normal in the population will be helpful.

In the study of pattern of palmar flexion creases among the Igbos of south eastern Nigeria (Okoro and Uloneme, 2004), most subjects were shown to have three major creases, while about one-third had midpalmar longitudinal crease. Of the palmar flexion creases, the transverse creases have received the most attention clinically especially when distal and proximal transverse lines fused to form a single transverse line from ulnar to radial border of the palm, called simian or 4-finger crease (Milton, 1970). Sydney line had also been described as the proximal transverse crease extending across the entire palm, while the distal crease appears normal. Purvis-Smith (Purvis-Smith and

---

\*Address for correspondence:

[moses.detona@mail.ui.edu.ng](mailto:moses.detona@mail.ui.edu.ng)

Received: January 2012; Accepted (Revised): May 2012

Menser, 1968) has called this a Sydney line as he observed it in patients examined in Sydney, Australia.

This study aims to establish normal variants of palmar flexion creases among Nigerians and simple classification of variants.

## MATERIALS AND METHODS

The sample consisted of 425 Nigerians (200 Yoruba, 136 Hausa and 89 Igbo), 259 males and 166 females aged 14 to 70 years, residing in a cosmopolitan city, Ibadan, south west Nigeria.

The subjects were healthy and physically able bodied volunteers. Informed consent statement was fully explained to volunteers that were unable to read and write, while informed consent form was administered to literate volunteers.

Right and left palmar and digital prints were obtained by ink procedure (Antonuk, 1970). The prints were obtained on A4 plain papers, already marked right and left, and spaces provided for biographic information.



**Fig 1**  
Schematic representation of Milton classification of palmar flexion creases

Several classifications had been used for palmar lines by Poch (1925), Fere (1900), Leiber (1960) but classification defined by Milton (1970) and Cummins (1960) was followed in this study while variants to these classifications was analyzed in the right and left palms of male and female Nigerian subjects.

Schematic representation by letters A-G according to Milton (Fig. 1 and Table 1) and corresponding name given by Cummins (Table 1) and definition of variants (Table 3) were used in this study for easy identification.

**Table 1**  
Classification according to Milton and Cummins

Milton	Cummins	Definitions
A	Radial longitudinal line	Deepest crease along the border of the thenar eminence when the thumb is opposed.
B	Proximal transverse line	Promixal transverse line
C	Distal transverse line	Distal transverse line
D	Middle longitude line	Longitudinal crease proximal to the middle finger in middle of the palm (middle finger crease)
E	Ring finger crease	Longitudinal crease proximal to the ring finger (ring finger crease)
F	Little finger crease	Longitudinal crease proximal to the little finger (little finger crease)
G	Ulnar longitudinal line	

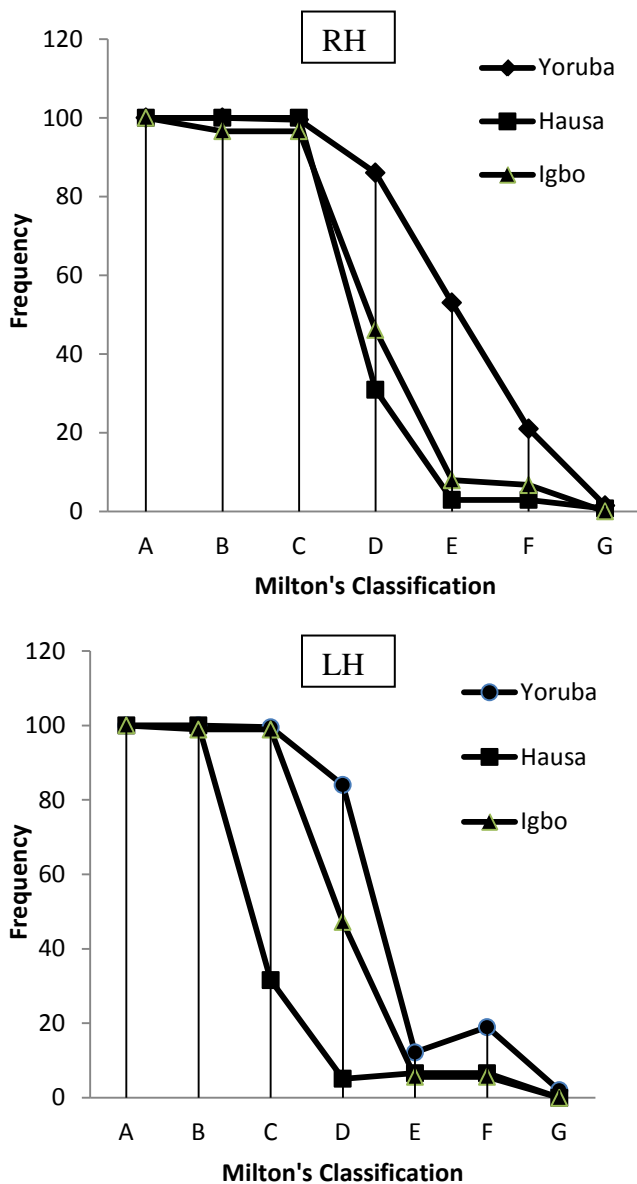
**Statistical Analysis:** Only clear prints were analyzed, palmar flexion lines and variants were coded using SPSS statistics. Data entry and analysis were done using Statistical Package for Social Sciences (SPSS) 16.0. Frequency tables were generated for categorical variables. Cross tabulations were generated to summarize the pattern of palmar prints across relevant characteristics as defined by schematic representation A-G.

## RESULTS

The most common configuration of the palmar creases among Nigerians was line A, which showed 100% presence among the three ethnic groups, for both right and left hands of male and female sexes (Fig. 2).

Line B shows 100% presence for both right and left hands among Yoruba and Hausa ethnic groups, while it is present at 96.6% and 98.9% for both right and left hands for Igbo.

Line C frequency is 99.5% for right and left hand of Yoruba ethnic group, present 100% on right hand and 31.6% of Igbo left hand. It is present at 96.6% and 98.9% of right and left hand respectively of Hausa ethnic group.



**Fig 2**  
Line Chart showing percentage frequency of right hand (RH) and left hand (LH) palmar flexion crease patterns within Nigeria three ethnic groups

The percentage frequency of the lines D to G reduces in frequency for both right and left hand as revealed in Fig. 2. Line G is absent in the left hand of Hausa and absent in both right and left hand of Igbo ethnic group.

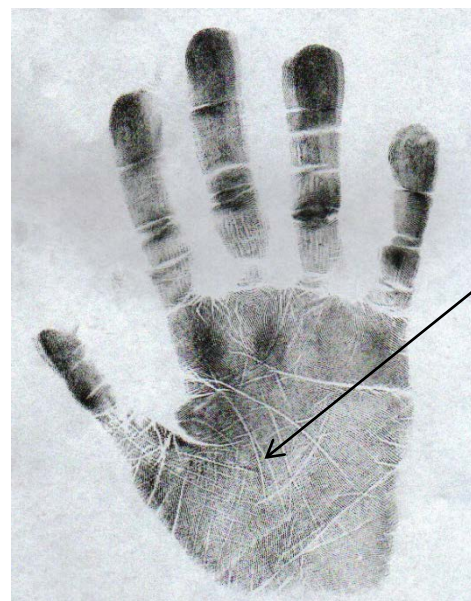Percentage frequency of variants that are found to be normal in both right and left hand of the three ethnic groups are shown in table 3. Lines A and B with radial base points occur in 53.2% of right hand and 50.7% of the left hand among the ethnic groups. Palmar prints with cascade of lines occurred in 31.3% of right hand and 33.6% of left hand of the ethnic groups.

**Table 3**

Definition and percentage frequency of variants of palmar flexion creases among three ethnic groups.

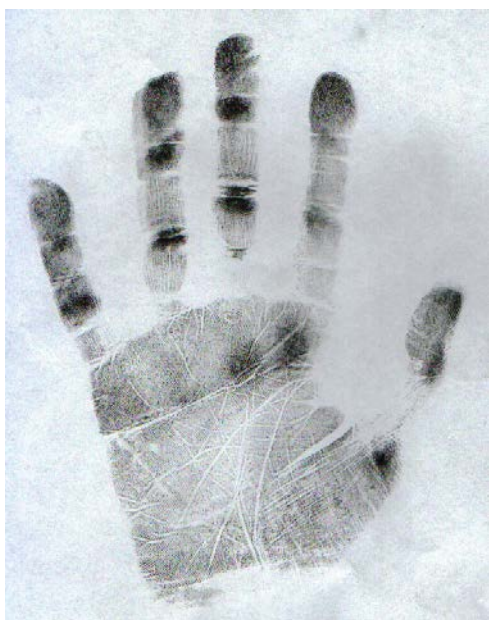Variants	Description	Frequency	
		RH	LH
Extra line on thenar eminence	Additional line to line A on thenar eminence	9.4	9.4
Numerous criss-crossing lines	Pattern less lines crossing lines A, B, and C	31.3	33.6
Double line A, double line B	Duplication of lines A and B	0	0.2
M type of lines A, B, C, D	Pattern arrangement of lines A, B, C, D like letter M	5.4	5.7
Simian crease	Lines A and B join before laterally at base of thumb	0.5	0.2
Bifurcation of line A close to distal wrist crease	Line A bifurcate proximally, unite distally	0	0.2
Merged lines B and C with middle enclosure	Lines B and C as single line medially and laterally with middle circle	0.2	0
Joining of lines A and B laterally (radial basepoint)	Lines A and B join midway between base of thumb and base of index finger	53.2	50.7

*RH = Right Hand; LH = Left Hand*



**Fig. 3**  
Showing Lines A, B, C, D with extra line on thenar eminence





**Fig. 4**  
Lines A, B, C, D with cascades



**Fig. 5**  
Lines A, B, C, D arranged in letter 'M'

## DISCUSSION

This simple observation of the pattern of palmar crease lines found among ethnic groups in Nigeria is a starting point to investigate anomalies and to easily recognize abnormalities in both clinical and non-clinical settings.

The observation made by Okoro and Uloneme (2004) that three main lines (thenar crease, proximal transverse crease and distal transverse crease) were the

most common among Igbo ethnic group of South East Nigeria was found to be corroborated by this study. Palmar flexion lines A, B, and C was also found to be most predominant for Hausa and Yoruba ethnic groups. The presence of simian crease; 0.5% and 0.2% right and left hand respectively among the three ethnic groups gives a precaution in diagnosing the simian line as abnormal within the Nigeria population.

The recognition of the variants as outlined in different prints either as extra line on thenar eminence, numerous criss-crossing lines (cascade of lines), double lines A and B, lines with bifurcations, lines with enclosure and variations in point of joining at lateral edges are important identification points.

This study was aimed at making the classification and recognition of the clinical significance of palmar crease lines easy; this is achievable with the classification adopted in this article.

## REFERENCES

- Achs R, Harper RG, Siegel M (1966)** Unusual dermatoglyphic findings associated with rubella embryopathy. *New Eng J Med* 274: 148-150.
- Antonuk SA (1975)** The method of receiving human palmar prints. *Voprosy Anthropology* 50:217-221..
- Cummins H (1966)** The skin and breasts. Morris' Human Anatomy, ed New York, McGraw-Hill Book Co. Inc., pp 113-114.
- Fere C (1900)** Les lignes papillaires de la paume de la main. *J Anat Physiol* 36: 376-392
- Hijmans JC, Shearin DB (1965)** Partial deletion of short arms of chromosome No.5. *Amer J Dis Child* 109:85-89.
- Lieber B (1960)** Zur systematic und Klinischen Bedeutung des menschlichen hand-furchenbildes. *Z menschl vererb konstit* 35: 205-232.
- Milton Alter (1970)** Variation in Palmar creases. *Amer J Dis Child* 120: 424-431.
- Okoro IO, Uloneme GCJ (2004)** The pattern of palmar flexion creases among the Igbos of south eastern Nigeria. *J Expt & Clin Anat* 3(2): 38-40.
- Penrose LS, Smith GF (1966)** Down's anomaly. J&A Churchill Ltd London.
- Poch H. Uber Handliniesn. (1925):***Mitt Antrop Ges* 55: 133-159,
- Purvis-Smith SG, Menser MA (1968)** Dermatoglyphics in adults with congenital rubella. *Lancet*; 1: 141-3.
- Schaumann B.A, Kimura S (1991)** Palmar, planter and digital flexion creases: Morphological and clinical considerations. *Birth Defects Orig Article Ser* 27(2):229-52.
- Uchida IA, Patau K, Smith DW (1962)** Dermal patterns of 18 and D trisomies. *Amer J Hum Genet* 14:345-352.