

[www.ajbrui.net](http://www.ajbrui.net)

*Afr. J. Biomed. Res. Vol.16 (May 2013); 115 - 123*

*Full Length Research Paper*

## **The Effect of Dextromethorphan on the Testes of Adult Sprague-Dawley Rats**

**Biose I. J<sup>1</sup>, Oremosu A. A<sup>2</sup>, Gbotolorun S.C<sup>3\*</sup>, Adegoke A. A<sup>4</sup>, Akang N. E<sup>5</sup> and Bakare A. A<sup>6</sup>**

*Department of Anatomy, Faculty of Basic Medical Sciences, College of Medicine, University of Lagos, P.M.B. 12003, Lagos, Nigeria.*

### **ABSTRACT**

Dextromethorphan (DM) is a dextro-rotatory isomer of levophanol and a major constituent of over 125 over the counter (OTC) cough syrups. *In-vivo* and *ex-vivo* studies have shown that DM has pain suppressive properties comparable to ketamine via its N-methyl-D-Aspartate (NMDA) receptor antagonism. There is a wide spread abuse of Cough syrups in Nigeria particularly amongst adolescent males. NMDA receptor antagonists have been reported to have anti-fertility properties. Pure samples of DM constituted in normal saline was administered orally to twenty mature male adult Sprague-Dawley rats of weight  $177.75 \pm 7.68$  g daily for 8 weeks. The animals were divided randomly into 4 groups; A, B, C, D (n=5). DM-HBr was administered at the following dosages: group A: Normal saline (control); group B: 0.214 mg/ kg b.w; group C: 0.571 mg/ kg b.w; group D: 4.285 mg/ kg b.w. At sacrifice; Routine histology, semen analysis, serum and intra-testicular levels of male reproductive hormones and testicular oxidative stress markers were assayed. Groups C and D showed a significant difference ( $p < 0.05$ ) in sperm count, sperm motility and abnormal morphology as well as reduction in the intra-luminal spermatozoa population compared to the control. Furthermore, a significant increase ( $p < 0.05$ ) in testicular oxidative stress markers and a reduction in mean values of reproductive hormones were observed. DM may induce oxidative stress which could lead to a decline in reproductive function following chronic administration. These effects are dose dependent.

**Keywords:** Dextromethorphan (DM), cough syrup, semen, testosterone, Leydig cells, oxidative stress markers

### **INTRODUCTION**

DM (3-methoxy 17-methylmorphinan) is a dextrorotatory isomer of Levomethorphan; the codein analog of Levophanol (Desai *et al.*, 2006). DM is a constituent of over 125 OTC cough and cold syrups (WHO, 2012).

The availability of OTC drugs in many countries is facilitated by pharmacies and increasing number of

outlets such as supermarkets, convenience stores and most recently the internet (Schwartz, 2005; Logan, 2009; Logan *et al.*, 2009; Shek, 2012). Reports have shown episodic and sporadic abuse of DM in several countries particularly, the United States of America, Canada, Denmark and most part of Asia (Murray and Breweton, 1993; Wolfe and Caravati, 1995; Darboe *et al.*, 1996; Shek, 2012).

\*Address for correspondence:

Phone. +2348038098631

E-mail: [scgbotl@yahoo.com](mailto:scgbotl@yahoo.com)

Date Received: January 2013

Date Accepted: April, 2013

**Abstracted by:**

*Bioline International, African Journals online (AJOL), Index Copernicus, African Index Medicus (WHO), Excerpta medica (EMBASE), CAB Abstracts, SCOPUS, Global Health Abstracts, Asian Science Index, Index Veterinarius, African Journals online*

Recently, Cough syrup abuse has been reported in the Southern and Northern parts of Nigeria (Uwadiae, 2011; Tijani *et al.*, 2012). In addition to the call for attention over the dangers of DM abuse, some observers have further highlighted on the role of the internet in facilitating this abuse (Bem and Peck, 1992; Logan, 2009). The purposeful ingestion of DM particularly among young people is performed at consciousness altering proportions (Cranston and Yoast, 1999; Boyer, 2004; Miller, 2005; Shek, 2012). However, the scope of DM abuse among Adolescents is still unknown (Falk *et al.*, 2006).

Soyka and colleagues have showed that DM also acts as a glutamate antagonist and this has been implicated for its addictive potential; it produces a psychotropic effect similar to that of alcohol (Soyka *et al.*, 2000). Furthermore, the documented dependence and physical withdrawal sequel to DM abuse may be secondary to serotonergic and sigma-1 opioidergic properties of the drug (Miller, 2005). This may explain the addiction and euphoria these recreational abusers derive (Helfer *et al.*, 1990; Hinsberger *et al.*, 1994; Logan *et al.*, 2009; Majilesi *et al.*, 2011).

Some street names of DM are: ‘Robo’, ‘C-C-C’; ‘Dex’; ‘Dextro’; ‘DM’; ‘Drex’; ‘DXM’; ‘Red Devils’; ‘Robo’; ‘Rojo’; ‘Tussin’; ‘Velvet’; ‘Vitamin D’ (Desai *et al.*, 2006; Logan, 2009; WHO, 2012).

It has been shown that the gonads are affected by a series of factors like exposure to physical agents, irradiation, hypoxia and certain types of drugs (Heywood and Wardsworth, 1980). One third of infertile couples may have a male factor present, and recreational OTC drugs abuse may be a factor (Fronczak *et al.*, 2012).

Yunsung *et al.*, (2012) in their study of the psychotoxic effect of DM, suggested that DM may reduce male reproductive function by suppressing the secretion of gonadotropin releasing hormone (GnRH) from the hypothalamus. A previous research has indicated that NMDA-receptor antagonists may reduce GnRH, thereby reducing male reproductive functions (Parlaktas *et al.*, 2008).

Due to paucity of literature on the effect of DM on the male reproductive system and function, and also the increasing abuse of this drug amongst teens, it became imperative to investigate the effect of DM-HBr on male reproduction using an animal model.

## MATERIALS AND METHODS

**Source of DM-HBR:** The pure substance of DM-HBr was manufactured by Long range Europe Ltd with:

Batch number; LU49JH, Manufacture Date; December 2011 and Expiry Date; January 2016.

**Animal Model:** Twenty sexually mature male adult Sprague-Dawley rats about 4 months old were obtained from the Animal house of Anatomy Department, College of Medicine of the University of Lagos. Animals were fed *ad libitum* with water and standard rat chow purchased from Okoko and Okoko Feeds Plc Lagos, Nigeria. They were maintained at 12-h light/12-h dark cycle, humidity of 50±10% and at temperatures of 25 ± 2°C. The animals were allowed to acclimatize for 3 weeks before the commencement of the experiment. During and at completion of the experiment, the animals were observed for clinical signs of drug toxicity. All procedures involving animals in this study were approved by the Departmental Committee on the use and care of animals and tissue collection.

**Experimental Protocol:** The animals were divided randomly into four groups: A, B, C, D. Each group consisted of five rats (*n*=5). Experimental groups B – D were administered increasing oral daily dosages of DM-HBr and treatment lasted for eight weeks:

Group A: received 2.857 ml/kg b.w. normal saline only, and served as experimental control.

Group B: received 0.214 mg/ kg b.w. DM

Group C: received 0.571 mg/ kg b.w. DM

Group D: received 4.285 mg/ kg b.w. DM

**Blood Sampling and Hormonal Assay:** Blood samples were collected from the orbital plexus of veins by capillary microtube into clean sample bottles and left to clot for separating the serum after centrifugation at 3000 rpm for 15 minutes. Serum samples were immediately frozen at –80 °C until hormonal assay was performed. Testosterone, Luteinising (LH), and Follicle-Stimulating Hormones (FSH) were measured as described by (Huhtaniemi *et al.*, 1985; Haavisto *et al.*, 1993; van Casteren *et al.*, 2000).

**Testes Sample Collection:** After blood sample collection and excision of caudal epididymis, the testes were excised immediately. The left testis of each rat was frozen and stored for intratesticular testosterone and markers of oxidative stress assay, while the right testes were weighed using Mettler Toledo light scale (AL204, Switzerland) and immediately put into Bouin’s fixative (0.2% picric acid/2% (v/v) formaldehyde in PBS) for the preparation of histological sections.

**Antioxidant Enzymes Assay:** The left testes and epididymides were homogenized using a Potter–

Elvehjem homogenizer. A 20% (1/5 w/v) homogenate of the tissue was prepared in 50 mM Tris-HCl buffer (pH 7.4) containing 1.15% potassium chloride and centrifuged at 10,000 g at 4 °C for 10 min. The supernatant was collected for the estimation of catalase (CAT) activity using hydrogen peroxide as the substrate (Clairborne, 1995). The H<sub>2</sub>O<sub>2</sub>-mediated oxidation of Fe<sup>+2</sup> to Fe<sup>+3</sup> was measured spectrophotometrically at 560 nm using xylenol orange dye (FOX-1) according to the method reported by Wolff, (1994). Superoxide dismutase (SOD) was assayed by the method described by Misra and Fridovich, (1972). Glutathione (GSH) was determined at 412 nm using the method described by Sedlak and Lindsay, (1968). Lipid peroxidation (LPO) was quantified as malondialdehyde (MDA) according to the method described by Ohkawa *et al.*, (1979) and as modified by Farombi *et al.*, (2000) and was expressed as micromolar of MDA per gram of tissue. Protein contents in the tissue were determined by the method of Lowry *et al.*, (1951).

**Seminal Analysis:** The caudal epididymis of the control and treated animals were excised and minced in 1 ml of normal saline and gently placed on a clean slide. The sperm progressive motility was determined according to the method described by Bearden and Fluquary (1980). The spermatozoa were counted by hemocytometer using the improved Neubauer (Deep 1/10 mm, LABART, Germany) chamber as described by Pant and Srivastava, (2003). Microscopic examinations of the seminal smears stained with Eosin Nigrosin stain were carried out to determine the percentages of sperm morphology. This was done using a binocular microscope (Leica DM 750, Switzerland) at 40× and 100× magnifications.

**Tissue Preparation for Histology:** Testes of the control and treated rats were cleared of connective tissues and fixed in Boiun's fluid (0.2% picric acid/2% (v/v) formaldehyde in PBS). After fixation, the piece of organ was dehydrated by bathing it successfully in graded mixture of ethanol and water (70 - 100%). The ethanol was then replaced with a solvent miscible with the embedding medium (xylene). As the tissues were infiltrated with xylene, it became transparent (clearing). Once the tissue was impregnated by xylene it was placed in molten paraffin, in an oven maintained at 58 - 60°C (embedding). The heat caused the solvent to evaporate and the spaces within the tissues become filled with paraffin. The tissue together with its impregnating paraffin was allowed to harden after been taken out of the oven. The hard block containing the tissue was then taken to the microtome and sectioned by the microtome steel. The sections were then floated on water and

transferred to a glass slide and stained with heamatoxylin and eosin stains. The microscopic slides were labeled appropriately. Photomicrographs were captured at magnifications of ×400 and ×1000 using Leica binocular microscope (Leica DM 750, Switzerland).

**Statistical Analysis:** Results are expressed as Mean±Standard Error of Mean (SEM). Differences between groups were assessed by one-way analysis of variance (ANOVA) using the SPSS software package for Windows. Statistical significance between groups was determined by Tukey multiple comparison posthoc test and *P* values less than 0.05 were considered to be statistically significant..

## RESULTS

### Effect of DM-HBr on mean testicular and body weight of adult male Sprague-Dawley rats

The effect of DM-HBr on mean testicular and body weight is shown in Table 1. There was a statistically significant (*p* < 0.05) dose related increase in the mean body weight of all the treated groups when compared with the control group.

**TABLE 1:**  
The Effect of DM-HBr on Body Weight in Male Sprague-Dawley Rats.

Treatment Groups	Initial Weight (g)	Final Weight (g)	Weight Difference (g)
Control	171.80 ± 9.77	215.8 ± 5.09	10.40 ± 5.72
0.214 mg/kg	178.20 ± 10.73	205.4 ± 8.08	11.12 ± 7.2*
0.571 mg/kg	176.80 ± 10.12	228.8 ± 7.72	12.0 ± 8.08*
4.285 mg/kg	171.33 ± 9.58	213.0 ± 23.69	41.67 ± 20.47*

*N*=5, Mean±SEM,

\**P*<0.05, compared with control using one-way ANOVA

### Effect of DM-HBr on sperm count, motility and morphology of adult male Sprague-Dawley rats.

Caudal epididymal sperm count was significantly reduced (*p* < 0.05) in a dose dependent manner when compared with the control group. The study also revealed a statistically significant reduction in sperm motility in the groups treated with 0.571 and 4.285 mg/kg b.w of DM-HBr. Also observed was an increase (*p* < 0.05) in abnormal sperm morphology in a dose dependent manner, compared to the control (Table 2).

**TABLE 2:**  
**Effect of DM-HBr on Semen Parameters in Male Sprague-Dawley Rats.**

Treatment Groups	Motility (%)	Count(10 <sup>6</sup> /ml)	Abnormal Morphology (%)
Control	90.4 ± 3.71	61.60 ± 2.05	6.20 ± 0.80
0.214 mg/kg bw	90.2 ± 3.40	56.70 ± 1.41*	7.10 ± 2.96*
0.571mg/kg bw	84.8 ± 2.44*	47.40 ± 3.55*	9.60 ± 3.96*
4.285 mg/kg bw	72.0 ± 7.39*	36.76 ± 1.86*	19.67 ± 1.14*

N=5, Mean±SEM,

\*P<0.05, compared with control using one-way ANOVA.

**Effect of DM-HBr on mean intratesticular and serum levels of testosterone, FSH and LH of adult male Sprague-Dawley rats.**

There was a statistically significant reduction ( $p < 0.05$ ) in the mean values of serum and intra-testicular testosterone levels across all the groups treated with DM-HBr when compared with the control group in a dose dependent manner (Table 3). The study did not

reveal any statistically significant difference in the mean serum levels of FSH in all the treated groups compared to the control group. Also observed was a statistically significant reduction ( $p < 0.05$ ) in the mean serum levels of LH in the groups treated with 0.571 mg/ kg b.w and 4.285 mg/ kg b.w of DM-HBr compared to the control.

**Effect of DM-HBr on testicular biochemical stress marker; GSH, SOD, CAT and MDA in adult male Sprague-Dawley rats.**

The study showed a statistically significant reduction ( $p < 0.05$ ) in the mean testicular levels of GSH across all the groups treated with DM-HBr when compared with the control group in a dose dependent manner. The study also observed a statistically significant increase ( $p < 0.05$ ) in the mean testicular levels of SOD in all the treated groups in a dose dependent manner when compared with the control group. The mean testicular levels of MDA in the groups treated with 0.571 and 4.285 mg/kg b.w of DM-HBr significantly increased ( $p < 0.05$ ) compared to the control group. However, the study did not record any statistically significant difference in the mean testicular levels of CAT in all the treated groups compared to the control group (Table 4).

**TABLE 3:**  
**Effect of DM-HBr on the Hormonal Assay of Male Sprague-Dawley Rats**

Group	Serum LH (miu/ L)	Serum FSH (miu/ L)	Serum Testosterone (nmol/L)	Intratesticular Testosterone (nmol/L)
Control	2.64±0.31	3.59± 0.19	26.2±7.54	62.5±2.08
0.214 mg/kg bw	2.56±0.31	3.64±0.02	23.76±6.24*	57.76±3.45*
0.571 mg/kg bw	1.40±0.52*	3.73±0.20	16.2±6.46*	55.5±5.0*
4.285 mg/kg bw	1.07±0.56*	3.85±0.13	6.5±1.85*	49.9±7.73*

N=5, Mean±SEM, \*P<0.05, compared with control using one-way ANOVA.

**Table 4:**  
**Effects of DM-HBr on the Biochemical Stress Markers of Male Sprague-Dawley Rat Testes.**

TREATMENT GROUPS	GSH (unit/mg protein)	SOD (unit/mg protein)	CAT (unit/mg protein)	MDA (unit/mg protein)
Control	0.226 ± 0.05	3.590 ± 0.73	29.99 ± 4.01	0.195 ± 0.02
0.214 mg/kg bw	0.134 ± 0.13*	5.084 ± 0.66*	31.31 ± 2.18	0.178 ± 0.19
0.571 mg/kg bw	0.136 ± 0.25*	6.978 ± 0.26*	31.58 ± 2.19	0.283 ± 0.27
4.285 mg/kg bw	0.130 ± 0.30*	8.367 ± 0.84*	31.46 ± 0.12	0.231 ± 0.06

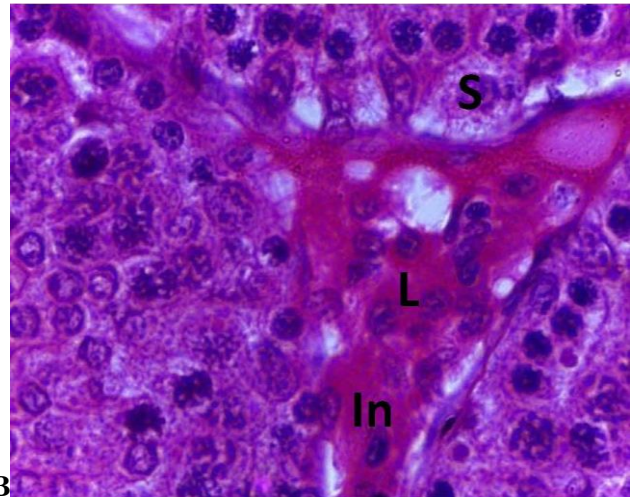
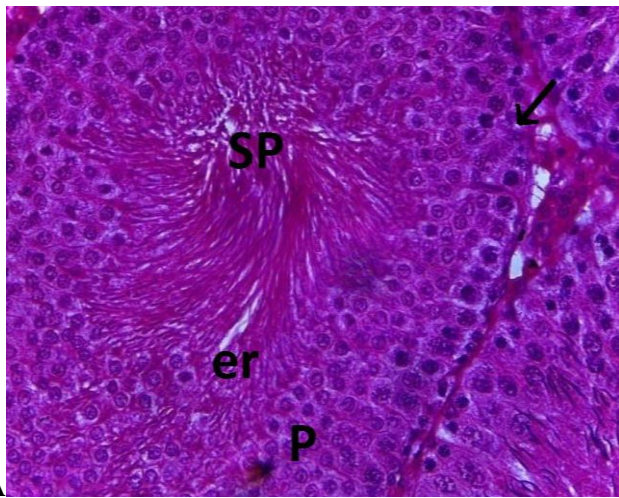
N=5, Mean±SEM, \*P<0.05, compared with control using one-way ANOVA.

**Testicular histological findings of adult male Sprague-Dawley rats treated with DM.**

The normal cytoarchitecture of the testis is shown in figs 1A and 1B; demonstrating a normal germinal epithelium and interstitial tissue respectively. The seminiferous tubules show an organized arrangement of the spermatogenic series, numerous spermatids with a rich population of spermatozoa in the lumen. Normal Sertoli and Leydig cells are seen in the interstitium.

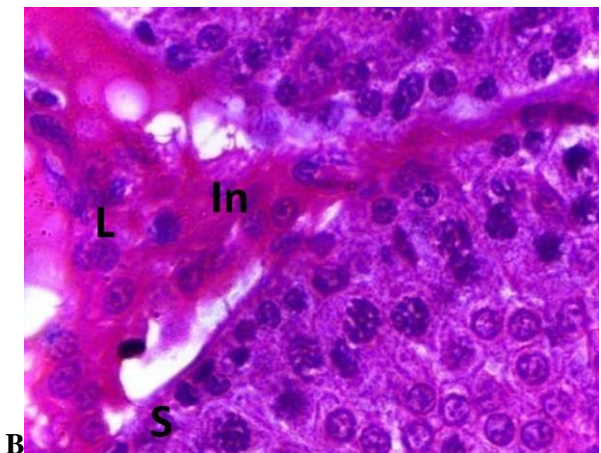
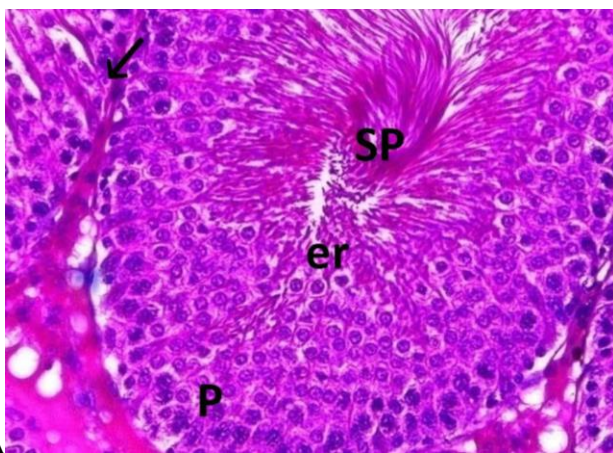
The histological sections of the groups treated with 0.214 mg/kg bw showed no relative difference in the cytoarchitecture of the testis compared to the control

(figs 2A and 2B). Groups treated with 0.571 mg/kg bw of DM-HBr showed moderately reduced populations of both adluminal spermatozoa as well as spermatids and also a distortion in the interstitium compared to the control (fig 3A and 3B). Histological sections of groups treated with 4.285 mg/kg bw of DM-HBr, showed a lumen almost devoid of spermatozoa, few spermatids and a disorganization in the arrangement of the spermatogenic series (fig 4A). Also observed was a disintegration of the interstitium and moderate degeneration of the Sertoli cells compared to the control (fig 4B).



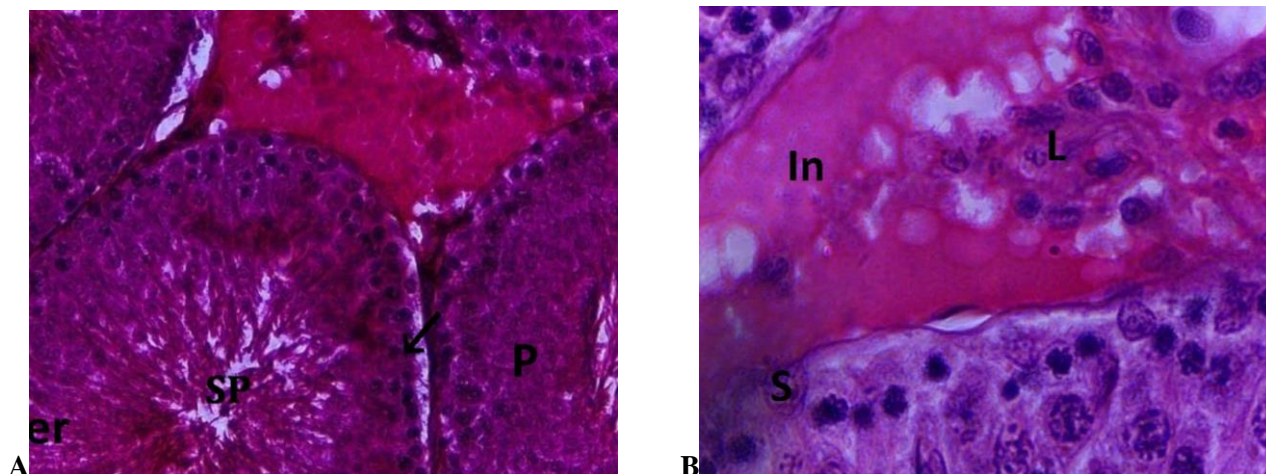
**Plate 1:**

**A.** Light micrograph of the testes of the control, showing normal germinal epithelium and interstitial tissues. The seminiferous tubules: showing a double basal layer of spermatogonia (arrow), numerous basal layers of primary spermatocytes (P) and numerous spermatids (er). The lumen shows high population of spermatozoa (SP). (H & E)  $\times 400$ . **B.** Light micrograph of the testes of control group demonstrating normal Sertoli cells (S), normal interstitium (In) and Leydig cells (L). (H & E)  $\times 1000$ .



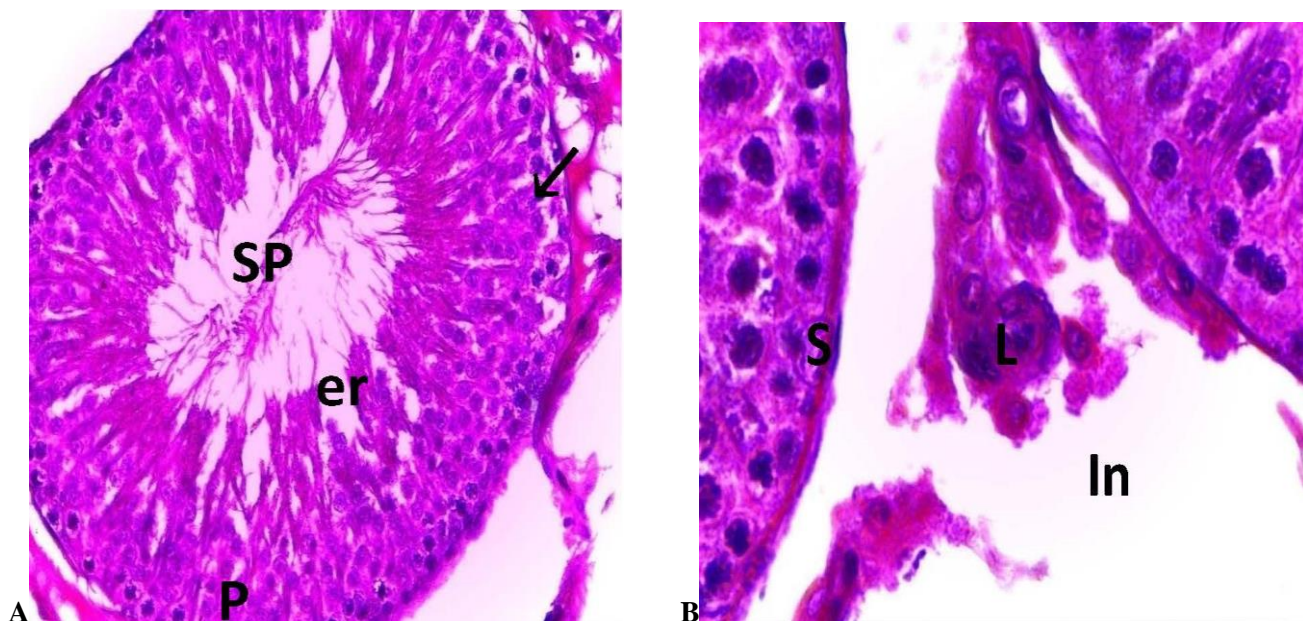
**Plate 2:**

**A.** Light micrograph of the testes of the group treated with 0.214 mg/kg b.w of DM-HBr, showing normal germinal epithelium and interstitial tissues. A seminiferous tubule is shown demonstrating a double basal layer of spermatogonia (arrow), numerous basal layers of primary spermatocytes (P) and numerous spermatids (er). The lumen shows numerous populations of spermatozoa (SP). (H & E)  $\times 400$ . **B.** Light micrograph of the testes of the group treated with 0.214 mg/kg b.w of DM-HBr, showing normal Sertoli cells (S), normal interstitium (In) and Leydig cells (L) measuring 20um in diameter. (H & E)  $\times 1000$ .



**Plate 3:**

**A.** Light micrograph of the testes of the group treated with 0.571 mg/kg b.w of DM-HBr, showing normal germinal epithelium and interstitial tissues. The seminiferous tubule is seen demonstrating a double basal layer of spermatogonia (arrow) and few basal layers of primary spermatocytes (P). The lumen shows moderately reduced population of spermatozoa (SP) and spermatids (er). (H & E)  $\times 400$ . **B.** Light micrograph of the testes of the group treated with 0.571 mg/kg DM-HBr showing normal Sertoli cells (S) normal interstitium (In) and Leydig cells (L). (H & E)  $\times 1000$ .



**Plate 4:**

**A.** Light micrograph of the testes of group C, showing degenerative changes in the germinal epithelium and interstitial tissues. The seminiferous tubules show a single basal layer of spermatogonia (arrow), few basal layers primary spermatocytes (P) and several degenerating spermatids (er). The lumen almost empty of spermatozoa population (SP) is seen. (H & E)  $\times 400$ . **B.** Light micrograph of the testes of group C, showing normal Sertoli cells (S), Leydig cells (L) and marked distortion of the interstitium (In). (H & E)  $\times 1000$ .

## DISCUSSION

This research was carried out to investigate the effect of DM-HBr containing cough syrups on the male reproductive function.

A total of 2 deaths were recorded in the groups that received DM-HBr at the highest dose during the 6<sup>th</sup> and

the 8<sup>th</sup> week of treatment respectively. However, before the deaths occurred, a steady decline in bodyweight was observed. The deaths recorded may be due to toxicity resulting from chronic treatment with DM-HBr. The result of this present study is consistent with the reports of Logan *et al.*, (2009) who reported the deaths of five teenagers who purposefully ingested large doses of

dextromethorphan obtained over the internet for recreational purposes and died as a result of the direct toxic effects of the drug.

However, in spite of the decline in weight observed in the two animals that died, a statistically significant dose dependent increase in mean body weight was observed in all the treated groups. This significant weight increase could be as a result of chronic stress produced by DM-HBr. Stress can affect virtually any part of the body and produces physical, mental and emotional symptoms including allergies, dizziness, headache, heart palpitations, environmental sensitivity, impaired coordination, impaired immunity and weight-gain (James, 2001).

Under stress, the body excretes corticotrophin-releasing hormone and adrenalin. This reaction stimulates the release of cortisol from the adrenal cortex. In turn, cortisol, a glucocorticoid, stimulates the release of glucose into the bloodstream, which, during periods of chronic stress, creates an excessive release of insulin. Insulin is a fat-storage hormone that overrides the stress signal from adrenalin to burn fat. The excess release of insulin gives the body the message to store fat (Facchini *et al.*, 2000).

On the other hand, the significant dose dependent increase in weight may be as a result of the increase in fat metabolism and/ or a consequent increase in feed consumption. However, no study has reported on the effect of DM-HBr on food consumption patterns.

The significant dose-dependent increase in the mean levels of SOD and the slight increase in the levels of CAT observed in the treated animals is an indication of their response to the increased levels of reactive oxygen species and/or free radicals in the testicular tissue (Sikka, 2001; Dandekar, 2002; Shweitta *et al.*, 2005). Similarly, the decreased levels of GSH observed in the present study across all the treated groups' showed that the mechanism of H<sub>2</sub>O<sub>2</sub> removal from the testicular cells had become overwhelmed and consequently, this may lead to a state of oxidation resulting to oxidative stress (Aitken and Roman, 2008). It is well known that GSH is involved in the mopping up of H<sub>2</sub>O<sub>2</sub> in testicular cells (Sikka, 2001; Shweitta *et al.*, 2005). H<sub>2</sub>O<sub>2</sub> is formed by the conversion of superoxide anion (O<sub>2</sub><sup>-</sup>) in the presence of SOD (Aitken and Roman, 2008). The elimination of H<sub>2</sub>O<sub>2</sub> is either effected by CAT or GSH, with GSH predominating in the testes (Zini and Schlegel, 1996). Furthermore, the observed significant increase in the mean levels of testicular MDA is an indicator for lipid peroxidation (Aitken and Roman, 2008). The observed increase in testicular MDA levels is a clear indication that DM induces oxidative stress (Sharma and Agarwal, 1996; Sikka, 2001; Dandekar *et al.*, 2002; Armagen *et*

*al.*, 2006). The result of this study is consistent with the study of Parlaktas *et al.*, (2007), in which the authors reported that NMDA receptor antagonists increased oxidative stress levels in rats. However, the present study is at variance with the study of Topsakal *et al.*, (2002), who demonstrated the acute antioxidant activity of DM in erythrocytes of rats following spinal cord tissue injury.

The significant decrease in sperm count recorded in all the treated groups in this study, strongly correlates with the histological reports as seen in the photomicrographs in which a dose dependent decline in spermatozoa content was observed in the seminiferous tubules. This result is in concord with a recent study on the psychotoxic effect of DM conducted by Nam *et al.*, (2012). These authors reported that the psychotoxicity of DM in male mice affects the quality of sperm parameters.

Serum FSH levels were also observed to be slightly increased. This correlates with the result of the photomicrograph in which Sertoli cell function was preserved.

The significant reduction in serum and intratesticular testosterone at all treatment dosages observed in the present study is in concord with the observed decline in serum LH. Androgen deficiency disturbs the spermiation process (Saito *et al.*, 2000) by altering the spermatid-sertoli cell junctions, which results in premature detachment of round spermatids from sertoli cells and seminal epithelium (Beardsley and O'Donnell, 2003). Testosterone is known to be critically important in the development of sperm cells, and results in the Leydig cells dysfunction and testicular steroidogenesis disorder (Zhang *et al.*, 2001). It therefore follows that the observed decrease in sperm parameters may be due to the observed decreased levels of serum testosterone across all the treated groups.

Furthermore, free radical-induced oxidative damage to spermatozoa, has gained considerable attention for its role in inducing poor sperm function and infertility (Sikka, 2001; Dandekar *et al.*, 2002; Shweitta *et al.*, 2005). Most of these harmful effects of sperm function and motility have been attributed to elevated levels of ROS (Sikka, 2001; Dandekar *et al.*, 2002; Shweitta *et al.*, 2005). Therefore, the significant reduction in the observed hormonal levels of LH, serum and intratesticular levels of testosterone as well as the significant reduction of sperm parameters, shows clearly that increased ROS and/ or free radicals (oxidative stress) is implicated for the testicular toxicity observed in this study.

In conclusion, the effect of DM is dose dependent and thus may induce oxidative stress which could cause a decline in the reproductive function of chronic abusers.

#### Acknowledgement

We thank Mrs Nmaka Tijani, the regulatory Affairs Manager of Fidson Healthcare Plc., who facilitated the importation of this drug. Our heartfelt appreciation also goes to Mr. Decland Ugwu of NAFDAC, Yaba for making the link with Fidson Healthcare Plc possible.

#### REFERENCES

**Aitken RJ, Roman D (2008):** Antioxidant systems and oxidative stress in the testes. In: *Molecular Mechanisms in spermatogenesis*, edited: Cheng CY. Landes Bioscience and Springer Science Bussiness Media.

**Armagen A, Uz E, yilmaz HR, Soyuoek S, Oksay T, Ozseilik (2006)** Effects of melatonin on lipid peroxidation-induced diabetic rat's testis. *Asian J Androl* 8: 595-600.

**Bearden HJ, Fluquary J (1980)** In Applied Animal Reproduction, Restore Publishing Co. Inc., Reston, Virginia, USA, Page 158-160.

**Beardsley A, O'Donnell L (2003)** Characterization of normal spermiation and spermiation failure induced by hormone suppression in adult rats. *Biol Reprod* 68: 1299-1307.

**Bem JL, Peck R (1992)** Dextromethorphan. An overview of safety issues. *Drug Saf* 7:190-199.

**Boyer EW (2004).** Dextromethorphan abuse. *PediatrEmerg Care* 20: 858-863.

**Clairborne A (1995)** Catalase activity. In: Greewald AR (ed) Handbook of methods for oxygen radical research. CRC Press, Boca Raton, FL, pp 237-242.

**Cranston JW, Yoast R (1999)** Abuse of dextromethorphan. *Arch Fam Med.* 8:99-100.

**Dandekar SP, Nadkarni GD, Kulkarni VS, Punekar S (2002)** Lipid peroxidation and antioxidant enzymes in male infertility. *JPGM* 48: 186-189.

**Darboe MN, Keenan GR, Richards T K (1996)** "The abuse of dextromethorphan-based cough syrup: a pilot study of the community of Waynesboro, Pennsylvania," *Adolescence.* 31: 633-644.

**Desai S, Aldea D, Daniels E, Soliman M, Braksmajer AS, Kopes-Kerr CP (2006)** A serious drug abuse and addiction related to dextromethorphan containing cough preparations. *J Am Board Fam Med* 19: 320-323.

**Facchini FS, Hua NW, Reaven GM, Stoohs RA (2000)** Hyperinsulinemia: The missing link among oxidative stress and age-diseases? *Free Radic Biol Med* 29: 302-306.

**Falk R, Li L, Carlson R, Wang J (2006)** The prevalence of DM Abuse among high school students. *Pediatrics.*118: 2267-2269.

**Farombi EO, Tahnteng JG, Agboola AO, Nwankwo JO, Emerole GO (2000):** Chemoprevention of 2-acetylaminofluorene-induced hepatotoxicity and lipid peroxidation in rats by kolaviron-a Garcinia kola seed extract. *Food Chem Toxicol* 38: 535-541.

**Fronczak CM, Kim ED, Barqawi AB (2012)** The Insults of Illicit Drug Use on Male Fertility. *J Androl* 33: 515-528.

**Haavisto AM, Pettersson K, Bergendahl M, Perheentupa A, Roser JF, Huhtaniemi I (1993)** A supersensitive immunofluorometric assay for rat luteinizing hormone. *Endocrinol* 132: 1687-1691.

**Helfer J, Kim OM (1990)** Psychoactive Abuse Potential of Robitussin DM. *Am J Psychiatry* 147: 672-673.

**Heywood R, Wardsworth PF (1980)** The experimental toxicity of estrogen. and blood cell counts of the treated wistar rats. The J Inter Encyclop Pharmacol Therapeutics 8: 125-142.

**b Cognitive deterioration from long term abuse of dextromethorphan: A case report. J Psychiatr Neurosci** 19: 375-377.

**Huhtaniemi I, Nikula H, Rannikko S (1985)** Treatment of prostatic cancer with a gonadotropin-releasing hormone agonist analog: acute and long term effects on endocrine functions of testis tissue. *J Clin Endocrinol Metab* 61: 698-704.

**James BL (2001).** Stress: The hidden factor for weight gain? April issue of Science News.

**Logan BK (2009)** Combined dextromethorphan and chlorpheniramine intoxication in impaired drivers. *J Forensic Sci* 54: 1176-1180.

**Logan BK, Goldfogel G, Hamilton R, Kuhlman J (2009)** Five deaths resulting from abuse of dextromethorphan sold over the internet. *J Anal Toxicol* 33: 99-103.

**Lowry OH, Rosenbrough NJ, Farr AL, Randall RJ (1951)** Protein measurement with folin phenol reagent. *J Biol Chem* 193: 265-275.

**Majilesi N, Lee DC, Ali SS (2011)** Dextromethorphan abuse masquerading as a recurrent sequence disorder. *Pediatric Emergency Care* 27: 210-211.

**Miller SC (2005)** Dextromethorphan psychosis, dependence and physical withdrawal. *Addict Biol* 10: 325-327.

**Misra HP, Fridovich I (1972)** The role of superoxide anion in the autooxidation of epinephrine and a simple assay for superoxide dismutase. *J Biol Chem* 247: 3170-3175.

**Murray S, Brewerton T (1993)** Abuse of over-the-counter dextromethorphan by teenagers. *South Med J* 86: 1151-1153.

**Ohkawa H, Ohishi N, Yagi K (1979)** Assay for lipid peroxides in animal tissues by thiobarbituric acid reaction. *Anal Biochem* 95: 351-358.

**Pant N, Srivastava SP (2003)** Testicular and spermatotoxic effects of quinalphos in rats. *J Appl Toxicol* 23: 271-274.

**Parlaktas BS, Ozyurt B, Ozyurt H, Tunc AT, Akbas A (2008)** Levels of Oxidative stress parameters and the protective effects of melatonin in psychosis model rat testis. *Asian J Androl* 10: 259-265.

**Saito K, O'Donnell L, McLachlan RI, Robertson DM (2000)** Spermiation failure is a major contributor to early spermatogenic suppression caused by hormone withdrawal in adult rats. *Endocrinol* 141: 2779-2785.

**Schwartz RH (2005)** Adolescent abuse of dextromethorphan. *Clin Pediatr (Phila)* 44: 565-568.

**Sedlak J, Lindsay RH (1968)** Estimation of total, protein-bound and non-protein sulfhydryl groups in tissue with Ellman's reagent. *Anal Biochem* 25:192-205.



- Sharma RK, Agarwal A (1996)** Role of reactive oxygen species in male infertility. *Urol* 48: 835-850.
- Shek DT L (2012)** Personal Construction of Cough Medicine among Young Substance Abusers in Hong Kong. *The ScientificWorld Journal*.1: 1-14.
- Shweitta SA, Tilmsany AM, Al-Sawaf H (2005).** Mechanisms of male infertility: a role of antioxidants. *Curr Drug Metab*.6: 495-501.
- Sikka SC (2001)** Relative impact of oxidative stress on male reproductive function. *Curr Med Chem* 8: 851-862.
- Soyka M, Bondy B, Eisenberg B, Schutz CG (2000)** NMDA receptor challenge with dextromethorphan subjective response, neuroendocrinological findings and possible clinical implications. *J NeuralTransm* 107: 701-714.
- Tijani AY, Salawu OA, John-Africa LB, Abubakar S, Chindo BA (2012)** Behavioural effects of Benylin-Codein in mice. *Nature and Science* 10: 1-5
- Topsakal C, Erol FS, Ozveren MF, Yilmaz N, Ilhan N (2002)** Effects of methylprednisolone and dextromethorphan on lipid peroxidation in an experimental model of spinal cord injury. *Neurosurgical Review* 25: 258-266.
- Uwadiae E (2011)** Psychoactive substance use/abuse among students in Igbinedion University, Okada, Nigeria –New challenges. *Nig J Gen Prac* 9: 31-34.
- van Casteren JI, Schoonen WG, Kloosterboer HJ (2000)** Development of time-resolved immunofluorometric assays for rat follicle-stimulating hormone and luteinizing hormone and application on sera of cycling rats. *Biol Reprod* 62: 886-894.
- Wolfe TR, Caravati EM (1995)** Massive dextromethorphan ingestion and abuse. *Am J Emerg Med* 13: 174-176.
- Wolff SP (1994)** Ferrous ion oxidation in the presence of ferric ion indicator xylenol orange for measurement of hydroperoxides. *Methods Enzymol* 233: 182-189.
- World Health Organisation (2012).** Dextromethorphan Pre-Review Report, 35<sup>th</sup> Expert Committee on Drug Dependence (ECDD) Hammamet, Tunisia, 4-8 June 2012 Agenda item 5.1.
- Yunsung N, Eun-Joo S, Boo-Keun Y, Jae-Hyung B, Ji Hoon J, Yoon Hee C, Eon Sub P, Zhengyi L, Kee-Won K, Young-Bae K, Toshitaka N, Hyoung-Chun K (2012)** Dextromethorphan-induced psychotoxic behaviors cause sexual dysfunction in male mice via stimulation of  $\sigma$ -1 receptors. *Neurochem Inter* 61: 913-922.
- Zhang X, Yamamoto N, Soramoto S, Takenaka I. (2001).** Cisplatin-induced germ cell apoptosis in mouse testes. *Arch Androl*. 46: 43-49.
- Zini A, Schlegel RN (2003).** Effect of hormonal manipulation on mRNA expression of antioxidant enzymes in rat testis. *J Urol*. 169: 1767-1771.