



Middle East Fertility Society  
**Middle East Fertility Society Journal**

www.mefsjournal.com  
www.sciencedirect.com



ORIGINAL ARTICLE

# Transvaginal power Doppler sonography can discriminate between benign and malignant endometrial conditions in women with postmenopausal bleeding

Mahmoud El-Morsi Aboul-Fotouh <sup>a,\*</sup>, Mohammed Hani Mosbeh <sup>a</sup>,  
Ahmed Fathi El-Gebaly <sup>b</sup>, Ahmed Nageeb Mohammed <sup>a</sup>

<sup>a</sup> OB/GYN Dept., Suzan Mubarak University Hospital, Minia, Egypt

<sup>b</sup> Radiology Dept., Minia University Hospital, Minia, Egypt

Received 17 October 2010; accepted 12 July 2011

Available online 6 August 2011

## KEYWORDS

Postmenopausal bleeding;  
Transvaginal sonography;  
Power Doppler sonography;  
Office hysteroscopy;  
Hysteroscopic guided biopsy

**Abstract** *Objective:* To evaluate the role of transvaginal power Doppler sonography in differentiation between benign and malignant endometrial conditions in women with postmenopausal bleeding.

*Setting:* OB/GYN Dept., Suzan Mubarak University Hospital and Radiology Dept., Minia University Hospital, Minia University, Minia, Egypt.

*Study design:* Prospective observational study.

*Patients:* Eighty patients with postmenopausal bleeding.

*Intervention(s):* Grey scale transvaginal sonography, power Doppler study of the endometrium and endometrial-myometrial interface, and office hysteroscopy and the final diagnosis by histopathological examination of hysteroscopic guided biopsy.

\* Corresponding author. Address: Ob/Gyn Dept., Faculty of Medicine, Minia University, Minia, Egypt. Current address: Taiba Hospital, Mubarak Alkabeer Governorate, Sabah Alsalem Area, Block 3, Street 3, P.O. Box 66482, Bayan 43755, Kuwait. Tel.: +2 086 2345388, mobile: +965 65683887.

E-mail address: [mmorsi72@yahoo.com](mailto:mmorsi72@yahoo.com) (M. El-Morsi Aboul-Fotouh).



**Results:** Endometrial power Doppler signals were positive in 69 out of the eighty patients (86.25%); 8 cases showed multiple vessel pattern -A- (10%); 19 cases with single vessel pattern -B- (23.75%); 42 cases with scattered vessel pattern -C- (52.5%) while in the remaining 11 cases (13.75%), no power Doppler signals were detected. The hysteroscopic findings were endometrial polyp in 16 cases (20%), atrophic endometrium in 14 cases (17.5%), hyperplasic endometrium in 32 cases (40%), submucous fibroid in 6 cases (7.5%), cervical polyp in 3 cases (3.75%) and suspicious endometrium for malignancy in 8 cases (10%). Hysteroscopy was more accurate in cases with intra-cavitary masses (polyps and submucous fibroids) than power Doppler, but power Doppler had a more predictive value for malignant endometrium.

**Conclusion:** Power Doppler blood flow mapping of the endometrium in women with postmenopausal bleeding is useful to discriminate carcinoma from other endometrial pathologies.

© 2011 Middle East Fertility Society. Production and hosting by Elsevier B.V. All rights reserved.

## 1. Introduction

Abnormal uterine bleeding at any age in women's life is disruptive and worrisome, but post menopausal bleeding is of special concern because it is the only common clinical indication of the presence of endometrial carcinoma (1).

Endometrial carcinoma is currently the most frequent gynecological cancer and postmenopausal bleeding is usually the first symptom. Although only about 10–15% of women presenting with postmenopausal bleeding will actually have an endometrial cancer, definitive diagnosis in this clinical setting is warranted (2).

Several different approaches have been proved to be clinically useful screening methods for early detection of endometrial abnormality in women with irregular uterine bleeding, these include dilatation and curettage (D&C) (3), hysteroscopy (4), and sonohysterography (5), and transvaginal sonography (TVS) with the measurement of endometrial thickness (6).

Doppler velocimetric study of the uterine artery offers another simple, non invasive and valuable method in screening women with post menopausal bleeding (1,7). Transvaginal color Doppler imaging allows the assessment of endometrial vascularization although some authors have argued that endometrial echotexture may help to differentiate carcinoma from polyps and hyperplasia.

In patients with thickened endometrium, a secondary test such as power Doppler could play a role in refining the diagnosis (2,8).

Power Doppler or color Doppler energy is a new technology that has some advantages over conventional color Doppler. Power Doppler is based on the amplitude of the Doppler signal but not on the Doppler frequency shift. It is insonation angle independent, does not have aliasing and is more sensitive to low-velocity blood flow. All these features make this technique advantageous for blood flow mapping by facilitating the detection of flow where present and depicting more clearly and reliably the vascular architecture (2).

The advantages of the power Doppler technique have been demonstrated in adnexal masses by Guerriero et al. (9). Another study has demonstrated a high correlation between microvessel density and power Doppler findings in breast carcinoma (10).

**Aim of the work:** The purpose of this study was to evaluate the role of transvaginal power Doppler sonography in differentiation between benign and malignant endometrial conditions in women with postmenopausal bleeding.

## 2. Patients and methods

This prospective observational study was conducted at the Endoscopy & Radiology units of Department of Obstetric and Gynecology Suzan Mubarak University Hospital, from November, 2007 to the first of July, 2008. It included eighty patients with postmenopausal bleeding recruited from the attendees of the outpatient Gynecology clinic of the Department of Obstetrics and Gynecology, Suzan Mubarak University Hospital, Minia University.

The study was approved by the ethical committee of the Faculty of Medicine, Minia University. All patients were counseled about the procedure and a written informed consent was obtained from all cases.

Inclusion criteria included: (1) Natural menopause; defined as 1 year of absence of menstruation in women older than 45 years provided that the amenorrhea was not explained by medication or disease, (2) Postmenopausal bleeding; defined as any vaginal bleeding in a postmenopausal woman not on hormone replacement therapy. While Exclusion criteria included; hormonal therapy, coagulation disorders, hypothyroidism or hyperthyroidism, liver diseases, evidence of PID, neglected IUD or pessary or any cervical abnormality.

All the patients were submitted to the following: thorough history taking, general examination, gynecological examination, cervical cytology (Pap. smear) and laboratory investigations (complete blood count, liver function tests, kidney function tests, thyroid function tests and a coagulation profile). Then transvaginal sonography was performed for all patients using a 7.5-MHz endovaginal transducer G.E. (General Electric LOGIC 5 PRO, USA) equipped with color, power and pulsed Doppler capabilities.

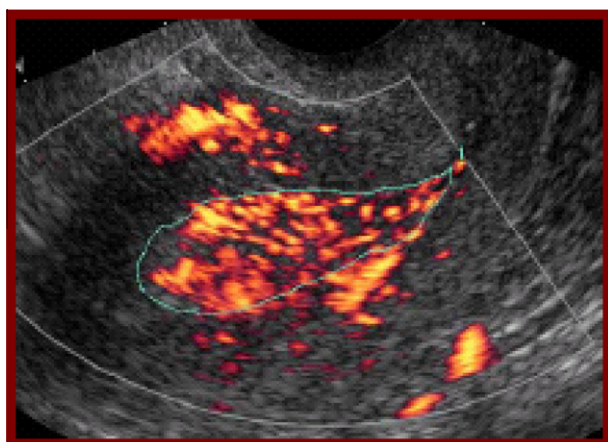
First, conventional gray-scale sonography was performed to obtain longitudinal and transverse sections of the uterus. Maximum endometrial thickness (double-layer) was measured in the longitudinal plane with the detection of any focal lesions.

Thereafter, power Doppler study of the endometrium was carried out. The power Doppler gate was activated (7.5 MHz) for blood flow mapping of the endometrium and endometrial-myometrial interface. Power Doppler settings were set to achieve maximum sensitivity for detecting low-velocity flow without noise.

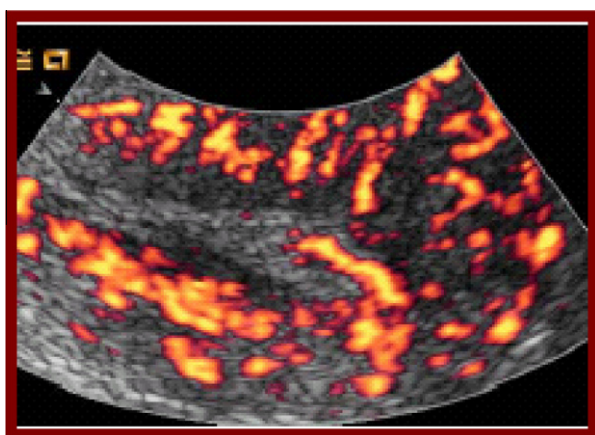Analysis of the power Doppler signals included visual evaluation of number, size, regularity of vessel branching, and presence of areas of densely packed blood vessels (color splashes).

According to power Doppler flow mapping, three different vascular patterns were defined (2):

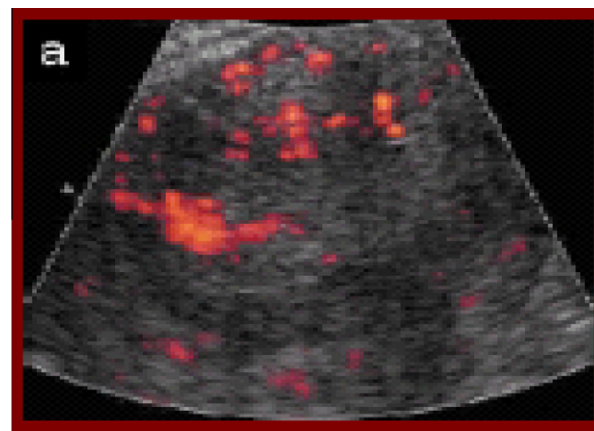
1. Multiple-vessel pattern (pattern A): Multiple vessels were found within the endometrium and in the myometrial-endometrial interface (Fig. 1). This pattern of blood flow was considered as characteristic of endometrial cancer. It reflects the neoangiogenic phenomena that occur within the tumor tissue and the surrounding areas.
2. Single-vessel pattern (pattern B): A single prevalent vessel was identified penetrating the endometrium from the myometrium (Fig. 2). This pattern was considered as characteristic of endometrial polyp as this vessel is thought to correspond to the vascularized polyp's pedicle.
3. Scattered-vessel pattern (pattern C): Scanty vessels were identified scattered in the endometrium (Fig. 3). This pattern was considered as characteristic of endometrial hyperplasia since some studies have shown that angiogenesis is limited in this pathology.
  - Once the vessels have been identified, the pulsed Doppler sample volume was activated to obtain a flow velocity waveform (FVW). Resistance index (RI), pulsatility index (PI) and peak systolic velocity (PSV) was automatically calculated from three consecutive FVWs.
  - The lowest RI and PI, and the highest PSV found were recorded.



**Figure 1** Endometrial vascular pattern (A).



**Figure 2** Endometrial vascular pattern (B).



**Figure 3** Endometrial vascular pattern (C).

- Only endometrial and endometrial-myometrial interface vessels were included.

Then office hysteroscopy was done for all patients within 24 h after power Doppler study using a 2.7 mm Ackermann Office Hysteroscopy (Germany), with an angle of vision of 30 degree. No anesthesia was used, as dilatation of cervix was not needed; only a nonsteroidal analgesic was given 1 h before the procedure.

Distension of the uterus was done with 0.9% saline. The procedure was monitored by autoclavable 3CCD camera head (Olympus, Tokyo, Japan) attached to the eyepiece and the image was displayed on a color monitor. The hysteroscope had side channels for instrumentation and another for suction and continuous irrigation.

Hysteroscopic guided biopsy was taken from suspicious areas of the endometrium under vision and in patients with normal hysteroscopic findings, endometrial samples were taken from the fundus, anterior wall and posterior wall; and the specimens were sent for histopathological examination.

Statistical analysis: Collection of data, correlation between results of power Doppler study and the results of hysteroscopic guided biopsy was done. Statistical calculations were undertaken using the Statistical Package for the Social Sciences (SPSS Inc., Chicago, Illinois, USA, version 13).

Evaluation of predictive power was based on:

Sensitivity: proportion of patients with the condition in question that tests can detect.

Specificity: proportion of patients without the condition that tests finds to be negative.

True positive (TP): Diseased persons with abnormal test results.

True negative (TN): Non-diseased persons with normal test results.

False positive (FP): Non-diseased persons with abnormal test results.

False negative (FN): Diseased persons with normal test results.

$\text{Sensitivity} = \frac{\text{true positives (TP)} \times 100}{\text{TP} + \text{false negatives (FN)}}$

Specificity = true negatives (TN)  $\times$  100/TN + false positives (FP).

Positive predictive value [Predictive value of abnormal test results (PPV)]: It is the proportion of abnormal test results that are true positive. [(PPV) = TP  $\times$  100/TP + FP].

Negative predictive value [Predictive value of normal test results (NPV)]: It is the proportion of normal test results that are true negative [(NPV) = TN  $\times$  100/TN + FN].

Efficacy = TP + TN  $\times$  100/TP + TN + FP + FN.

A *P*-value  $\leq$  0.5 was considered statistically significant for all tests used.

### 3. Results

This study included 80 women with postmenopausal bleeding. The mean age was  $51.7 \pm 5.4$  years (range 45–65 years). These women were postmenopausal for 1–16 years (Mean  $\pm$  SD,  $4.69 \pm 3.63$ ). Parity ranged from 1 to 12 with mean value of  $5.5 \pm 2.5$ . The duration of bleeding ranged from 1 to 30 days (mean  $7.6 \pm 3.5$  days).

The histopathological diagnosis of the hysteroscopic guided biopsies is shown in Table 1. Atrophic endometrium and proliferative endometrium were considered normal diagnoses, while endometrial hyperplasia, endometrial polyp, and endometrial cancer were considered abnormal diagnoses.

Patients with endometrial carcinoma were noticed to be with older age, lower parity and longer postmenopausal duration. The mean endometrial thickness in atrophic endometrium, endometrial hyperplasia, endometrial polyp, and endometrial carcinoma were  $3 \pm 1.2$  mm,  $8.6 \pm 4.2$  mm,  $10.6 \pm 3.9$  mm, and  $18 \pm 6$  mm, respectively. There was a statistically significant difference in the mean endometrial thickness between women with endometrial carcinoma and women with normal endometrium  $18 \pm 6$  mm, and  $4.6 \pm 2.08$  mm, respectively (*P*-value = 0.021).

Taking an endometrial thickness of 5 mm as a cut off value for prediction of endometrial malignancy had 100% sensitivity, 51.9% specificity, 60.9% positive predictive value, 100% negative predictive value, and 48.7% diagnostic accuracy. All cases diagnosed as endometrial carcinoma had endometrial thickness of  $\geq 8$  mm, measured by TVS, so raising the cut of value to 8 mm also had 100% sensitivity, but with much higher specificity, positive predictive value, negative predictive value and diagnostic accuracy (80.4%, 73.7%, 100% and 75%, respectively). Furthermore, combining thick endometrium  $\geq 8$  mm to suspicious endometrial picture (heterogenous echogenicity and (or) irregular endometrial-myometrial

border), gives much greater increase in the diagnostic values of the TVS (100%, 94.5%, 90%, 98.6%, and 93.75%, respectively regarding sensitivity, specificity, positive predictive value, negative predictive value and diagnostic accuracy).

Endometrial power Doppler signals were positive in 69 out of the eighty patients (86.25%) [62 out of 73 patients with non-neoplastic endometrium (84.9%) and in 7 out of 7 patients with neoplastic endometrium (100%)], while in the remaining 11 cases, no power Doppler signals were detected (13.75%); either due to thin endometrium (atrophic) in 6 cases (54.5%), or due to enlarged uterus (by fibroid) in 4 cases (36.4%), and in the remaining case (9%) the endometrial thickness was 10 mm with average sized uterus and the histopathological diagnosis revealed endometrial hyperplasia.

The power Doppler vascular patterns of the 69 patients were as follows: 8 cases showed multiple vessel pattern -A- (10%); 6 of them were diagnosed by histopathology as endometrial carcinoma (75%), 19 cases with single vessel pattern -B- (23.75%); 13 of them were diagnosed as endometrial polyp (68.4%), 42 cases with scattered vessel pattern -C- (52.5%); 29 of them were diagnosed as endometrial hyperplasia (66.6%).

Atrophic endometrium showed pattern C in 8 of 15 cases (53.3%), pattern B in one case (6.6%), and no signals were detected in 6 cases (40%).

Taking hysteroscopic guided biopsy as the gold standard, the diagnostic performance of power Doppler pattern (A) for detecting endometrial cancer was; 6 true positive cases, 2 false positive cases, one false negative case, and 71 cases of true negative results.

Taking hysteroscopic guided biopsy as the gold standard, the diagnostic performance of power Doppler pattern (B) for detecting endometrial polyp was; 13 true positive cases, 6 false positive cases, 3 false negative cases, and 58 cases of true negative results.

Taking hysteroscopic guided biopsy as the gold standard, the diagnostic performance of power Doppler pattern (B) for detecting endometrial hyperplasia was; 29 true positive cases, 13 false positive cases, 9 false negative cases, and 29 cases of true negative results.

Taking hysteroscopic guided biopsy as a gold standard diagnostic tool for detecting endometrial cancer, endometrial polyp, and endometrial hyperplasia; the diagnostic indices of power Doppler vascular patterns are shown in Table 2.

Endometrial carcinoma showed relatively high PI and PSV ( $0.92 \pm 0.034$  and  $10.91 \pm 0.21$ , respectively) compared to endometrial hyperplasia ( $0.88 \pm 0.068$  and  $10.1 \pm 0.55$ ), but endometrial polyp had the highest PI ( $0.97 \pm 0.059$ ). RI was noticed to be lowest in carcinoma.

The hysteroscopic findings of the studied 80 women were endometrial polyp in 16 cases (20%), atrophic endometrium in 14 cases (17.5%), hyperplastic endometrium in 32 cases (40%), submucous fibroid in 6 cases (7.5%), cervical polyp in 3 cases (3.75%) and suspicious endometrium for malignancy [Irregular growth, abnormal vascularity, necrotic and hemorrhagic areas] in 8 cases (10%).

The diagnostic performance of office hysteroscopy in various endometrial lesions is shown in Table 3.

Comparing the diagnostic performance of office hysteroscopy and power Doppler, hysteroscopy is more accurate in cases with intra-cavitary masses (polyps and submucous fibroids) than power Doppler, but power Doppler gives more predictive value for malignant endometrium.

**Table 1** Endometrial histopathology in all patients.

Histopathological diagnoses	Number (n)	Percent (%)
<i>Normal histopathology</i>		
Atrophic	15	18.75
Proliferative	1	1.25
<i>Abnormal histopathology</i>		
Endometrial hyperplasia	38	47.5
Endometrial polyp	16	20
Cervical polyp	3	3.75
Adenocarcinoma	7	8.75
Total	80	100

**Table 2** Predictive values of various power Doppler vascular patterns.

Test characteristics	Power Doppler vascular pattern			P-value
	A (Carcinoma)	B (Polyp)	C (Hyperplasia)	
Sensitivity (%)	85.71	81.25	76.31	NS
Specificity (%)	97.26	93.54	69.05	
Positive predictive value (%)	75	68.42	69.05	
Negative predictive value (%)	98.61	95.08	76.31	
Diagnostic accuracy (%)	96.25	88.75	72.5	

NS = non-significant.

**Table 3** Diagnostic indices, predictive value, and diagnostic accuracy of office hysteroscopy.

Test characteristics	Hysteroscopic finding					P-value
	Polyp	Hyperplasia	Carcinoma	Atrophy	Myoma	
Sensitivity (%)	100	82.05	71.42	85.7	100	NS
Specificity (%)	100	78.05	95.89	96.9	100	
Positive predictive value (%)	100	78.05	62.5	80	100	
Negative predictive value (%)	100	82.05	97.22	96.9	100	
Diagnostic accuracy (%)	100	80	93.75	93.75	100	

NS = non-significant.

**Table 4** Combining positive results of TVS and hysteroscopy to results of power Doppler.

Diagnostic tool	Sensitivity (%)	Specificity (%)	Positive predictive value (%)	Negative predictive value (%)	Diagnostic accuracy (%)	P-value
Vascular pattern (A) + thickened endometrium by U/S	100	98.86	85.7	100	98.75	NS
Vascular pattern (A) + positive hysteroscopic finding	100	97.26	77.7	100	97.5	

NS = non-significant.

Combining the positive results of power Doppler (vascular pattern –A), with the positive result of TVS (irregular heterogeneous thick endometrium) using the cut off value  $\geq 8$  mm, raised the sensitivity, specificity, positive and negative predictive values and diagnostic accuracy of conventional TVS for malignant endometrium up to 100%, 98.86%, 85.7%, 100%, and 98.75%, respectively. Also, combining the positive results of power Doppler (vascular pattern –A), with the positive result of office hysteroscopy raised the sensitivity, specificity, positive and negative predictive values and diagnostic accuracy of office hysteroscopy to 100%, 97.26%, 77.7%, 100% and 97.5%, respectively (Table 4).

#### 4. Discussion

In the present study we found that the mean endometrial thickness measured by TVS in cases with atrophic endometrium, endometrial hyperplasia, endometrial polyp and endometrial carcinoma was  $3 \pm 1.2$ ,  $8.6 \pm 4.2$ ,  $10.6 \pm 3.9$ ,  $18 \pm .6$  mm, respectively. A cut off value of 5 mm for the prediction of

endometrial carcinoma showed 100% sensitivity, 51.9% specificity, 60.9% positive predictive value, 100% negative predictive value, and 48.7% diagnostic accuracy.

In the present study all cases diagnosed as endometrial carcinoma had endometrial thickness of  $\geq 8$  mm. measured by TVS, so raising the cut of value to 8 mm also had 100% sensitivity, but with much higher specificity, positive predictive value, and diagnostic accuracy (80.4%, 73.7% and 75%, respectively). Furthermore, combining thick endometrium  $\geq 8$  mm to suspicious endometrial picture (heterogeneous echogenicity and/or irregular endometrial-myometrial interface), gave a much more increase in the diagnostic values of TVS (94.5%, 90%, 98.6%, and 93.75%, respectively). This is in agreement with Opolskiene et al. (11), who concluded that heterogeneous endometrial echogenicity is superior to endometrial thickness in the prediction of endometrial cancer.

Endometrial blood flow can be evaluated non-invasively by color and power Doppler ultrasound. Power Doppler imaging is more sensitive than color Doppler imaging at detecting low velocity flow and hence improves the visualization of small

vessels; power Doppler provides a unique tool by which the blood supply of the whole endometrium and the subendometrial region could be examined (12).

Our results indicate that the use of the three vascular patterns as depicted by power Doppler is useful to discriminate endometrial carcinoma from endometrial hyperplasia and endometrial polyps. All cases with endometrial cancer showed endometrial vascularization (7 of 7) cases (100%). This is in agreement with Epstein et al. (13) who detected power Doppler signals in all cases with endometrial malignancy (16 of 16), in 84% (46 of 54) of those with benign pathological endometrium and in 77% (10 of 13) of women with normal endometrium.

Amit et al. (14) counted the endometrial blood vessels detected by power Doppler in women with postmenopausal bleeding. They found vessels in the majority of cases with endometrial malignancy (12 of 14 cases; 86%) and in 26% (12 of 46 cases) of those with benign endometrium. Their lower incidence may be due to their inclusion of a small number of cases in their study.

In another study by Szpurek et al. (15), the presence of "new, irregular vessels" was subjectively evaluated and found in 81% of women with endometrial cancer and in 12% of women with hyperplasia but in none with normal endometrium.

The differences in results between studies could be explained by differences in ultrasound equipment, machine setting, experience of the examiners, and by lack of standardized criteria for subjective evaluation of endometrial vascularity.

In contrast to studies of power Doppler, Aleem et al. (16) and Sheth et al. (17) reported, using conventional color Doppler, as many as 44–57% of the cancers had no color signals. This may be explained by the technical differences between color and power Doppler which were previously mentioned.

In the present study, 6 of 7 cases (85.7%) with endometrial cancer showed the typical multiple-vessel pattern and one case with endometrial cancer showed scattered-vessel pattern (14.2%). Taking hysteroscopic guided biopsy as a gold standard diagnostic tool for detecting endometrial cancer, the diagnostic performance of power Doppler for detecting endometrial carcinoma was: sensitivity 85.71%, specificity 97.26%, positive predictive value 75%, negative predictive value 98.61% and diagnostic accuracy 96.25%. These results were in agreement with Alcazar et al. (2) who reported a sensitivity, specificity, positive predictive value, and negative predictive values of power Doppler vascular pattern for endometrial carcinoma of 78.8%, 100%, 100%, and 89%, respectively.

Opolskiene et al. (11) studied the endometrial vascular pattern in cases of endometrial cancer. They reported lower sensitivity and specificity of power Doppler for endometrial carcinoma (80% and 54%, respectively).

In the present study, power Doppler signals were found in 16 of 16 (100%) cases with endometrial polyps, 13 cases (81.25%) of them presented the single-vessel pattern. Amit et al. (14) using conventional color Doppler have also reported this typical pattern in cases with endometrial polyps.

Taking hysteroscopic guided biopsy as a gold standard diagnostic tool for detecting endometrial polyps, the diagnostic performance of power Doppler for endometrial polyps was: sensitivity 81.25%, specificity 93.54%, positive predictive value 68.42%, negative predictive value 95.08% and diagnostic accuracy 88.75%. These results were in agreement with Alcazar et al. (2), who reported sensitivity, specificity, positive

predictive value, and negative predictive value of power Doppler vascular pattern for detecting endometrial polyps of 89.2%, 87%, 82.5%, and 92.2%, respectively.

In the present study, power Doppler signals were found in 37 of 38 (97.36%) cases with endometrial hyperplasia, most of these cases (29 of 38, 76.3%) showed a scattered-vessel pattern. However, this pattern was also shown in most cases of endometrial atrophy 8 of 15 cases (53.3%), which makes a difficulty to differentiate between them. Alcazar et al. (2) reported sensitivity, specificity, positive predictive value, and negative predictive value of power Doppler vascular pattern for endometrial hyperplasia as: 57.1%, 88.3%, 47.1%, and 91.9%, respectively. They concluded that power Doppler is not useful to detect endometrial hyperplasia due to low sensitivity.

Regarding velocimetric parameters, we found that malignant endometrium had a much lower RI (mean =  $0.47 \pm 0.04$ , range = 0.44:0.51), and higher PSV (mean =  $10.91 \pm 0.21$ , range = 10.7:11.1) than other causes of postmenopausal bleeding. Our results were in agreement with those of previously reported studies by Chan et al. (18), Sladkevicius et al. (19) and Sheth et al. (17).

Alcazar et al. (20) correlated intratumoral blood flow as assessed by transvaginal color Doppler with tumor histopathologic characteristics. They reported a significantly lower RI and higher PSV in tumors with grade III or more and infiltrative growth pattern.

Also Kupesic and Kurjak (21) reported low vascular resistance (RI =  $0.42 \pm 0.02$ ) in the vessels of the central parts of the lesion as well as the surrounding myometrial vessels if positive for invasion. They suggested that the possible cause is the deficient endothelial membrane and leaky structure. On the other hand, Opolskiene et al. (22) reported that flow indices could not discriminate well between the benign and malignant endometrium.

In cases with endometrial polyps, we reported a higher RI (mean =  $0.65 \pm 0.16$ , range 0.56:0.73) than cases with endometrial carcinoma. This is in agreement with Kupesic and Kurjak (21) who reported RI higher than 0.45 in cases with endometrial polyp except if peripheral necrosis occurs in the polyp the blood flow impedance is markedly reduced.

In cases with endometrial hyperplasia we reported a significantly higher RI (mean =  $0.52 \pm 0.04$ , range = 0.50:0.53) than cases with endometrial carcinoma. This is in agreement with Kupesic and Kurjak (21) who reported RI higher than 0.55 in cases with endometrial hyperplasia (in carcinoma mean RI =  $0.42 \pm 0.02$ ).

In our study, a considerable overlap of RI, PI and PSV values was found, which limits the clinical use of a cut off value in diagnosis of endometrial malignancy. This is in agreement with Kupesic and Kurjak (21) who concluded that a reliable differentiation between endometrial hyperplasia and carcinoma is not possible due to overlap in the Doppler indices. This is in contrast to Amit et al. (14), who used power Doppler to identify endometrial vessels then used a cut-off PI  $\leq 1.0$  as a selection criterion to discriminate between endometrial carcinoma and benign conditions. They found that power Doppler plus PI had higher sensitivity and specificity as compared with measurement of endometrial thickness alone. However, they did not analyze conventional color Doppler imaging. In the same context, Mercé et al. (23) concluded that the vascularity index (VI), 3D power Doppler indices, and the intratumoral RI were

more useful than endometrial thickness for differentiating between hyperplasia and endometrial carcinoma. Likewise, Alcazar and Galvan (24) reported that VI was the best parameter for the prediction of endometrial cancer.

In the present study, the diagnostic performance of office hysteroscopy in predicting endometrial carcinoma had a sensitivity of 71.42%, specificity of 95.89%, positive predictive value of 62.5%, negative predictive value of 97.22% and a diagnostic accuracy of 93.75%. For endometrial hyperplasia, the figures were; 82.05%, 78.05%, 78.05%, 82.05% and 80%, respectively.

According to Tinelli et al. (25), hysteroscopy revealed sensitivity of 98%, specificity of 91%, a positive predictive value of 88%, a negative predictive value of 98%, and diagnostic accuracy of 94% in detecting focal endometrial lesions. The higher diagnostic performance obtained by Tinelli et al. (25) was due to their inclusion of any endometrial focal lesions as a single entity, while in our study, we calculated the specific diagnostic performance for each type of lesions separately regardless presence or absence of endometrial focal lesions.

In a comparison between TVS and outpatient hysteroscopy for diagnosis of postmenopausal bleeding, Tinelli et al. (25) found that hysteroscopy is a significantly more accurate diagnostic method for the detection of endometrial pathology than TVS. It has better specificity and should be considered for all patients with AUB with an endometrial thickness of more than 4 mm.

Combining morphological criteria of the endometrium and power Doppler vascular pattern for prediction of endometrial malignancy, we found a higher sensitivity, specificity, positive predictive value, negative predictive value and diagnostic accuracy (100%, 98.86%, 85.7%, 100% and 98.75%, respectively). Also, combining the positive results of power Doppler (vascular pattern –A), with the positive result of office hysteroscopy raised the sensitivity, specificity, positive and negative predictive values and diagnostic accuracy of office hysteroscopy to 100%, 97.26%, 77.7%, 100% and 97.5%, respectively. This is in agreement with Kupesic and Kurjak (21) who combined the morphological criteria of the endometrium obtained by TVS and power Doppler vascular pattern for the diagnosis of endometrial carcinoma and reported increased sensitivity up to 91.67%.

In conclusion, the use of power Doppler blood flow mapping as a secondary test in women not taking hormone replacement therapy presenting with postmenopausal bleeding and a thickened endometrium at baseline sonography is useful to discriminate carcinoma from other causes of endometrial thickening. Also, it might be a promising screening tool for asymptomatic postmenopausal women with risk factors for endometrial carcinoma.

#### Disclosure of interests

None.

#### Contribution to authorship

All authors have significantly contributed to this work. ME and MH-M conceived the idea for this paper and designed the original study. ME, MH-M and AM-N were the study gynecologists who performed hysteroscopy and TVS, and

collected the data and performed the analyses. Inter-observer bias was overcome by the requirement of inter-observer agreement. AF-E performed the power Doppler. All authors read and approved the final manuscript.

#### Details of ethical approval

The study was approved by the ethical committee of the Faculty of Medicine, Minia University.

#### Funding

None.

#### Acknowledgment

None.

#### References

- (1) Mosbeh MH, Mohamed MA, Ibrahim E, Sabry M. Accuracy of color Doppler and transvaginal sonography in detecting endometrial abnormalities in women with perimenopausal and postmenopausal bleeding. *El-Minia Med Bull* 2000;11(2):43–53.
- (2) Alcazar JL, Castillo G, Minguez JA, Galan MJ. Endometrial blood flow mapping using transvaginal power Doppler sonography in women with postmenopausal bleeding and thickened endometrium. *Ultrasound Obstet Gynecol* 2003;21:583–8.
- (3) Stock RT, Kanbour A. Prehysterectomy curettage. *Obstet Gynecol* 1975;45(4):531–7.
- (4) Cacciatore B, Ramsay T, Lettovitra P, Ylostalo P. Transvaginal sonography and hysteroscopy in postmenopausal bleeding. *Acta Obstet Gynecol Scand* 1994;73:413–6.
- (5) Kamel HS, Darwish AM, Mohamed S. Comparison of transvaginal sonography and vaginal sonohysterography in the detection of endometrial polyps. *Acta Obstet Gynecol Scand* 2000;79:60–4.
- (6) Weber G, Merz F, Bahlmann E, Rosch B. Evaluation of different transvaginal sonographic parameters in women with postmenopausal bleeding. *Ultrasound Obstet Gynecol* 1998;12:265–70.
- (7) Vuento MH, Pirthonen J, Makinen JI, Tyrkko LJ, Laippala P, Gronroos M, Salmi TA. Screening of endometrial cancer in asymptomatic postmenopausal women with conventional and color Doppler sonography. *Br J Obstet Gynecol* 1999;106:14–20.
- (8) de Kroon CD, Hiemstra E, Trimboos JB, Jansen FW. Power Doppler area in the diagnosis of endometrial cancer. *Int J Gynecol Cancer* 2010;20(7):1160–5.
- (9) Guerriero S, Alcazar JL, Ajossa S, Lai MP, Errasti T, Mallarini G, Melis GB. Comparison of conventional color Doppler imaging and power Doppler imaging for the diagnosis of ovarian cancer: results of a European study. *Gynecol Oncol* 2001;83:299–304.
- (10) Yang WT, Tse GM, Lam PK, Metreweli C, Chang J. Correlation between color power Doppler sonographic measurement of breast tumor vasculature and immunohistochemical analysis of microvessel density for the quantitation of angiogenesis. *J Ultrasound Med* 2002;21(12):1227–35.
- (11) Opolskiene G, Sladkevicius P, Valentin L. Ultrasound assessment of endometrial morphology and vascularity to predict endometrial malignancy in women with postmenopausal bleeding and sonographic endometrial thickness  $\geq 4.5$  mm. *Ultrasound Obstet Gynecol* 2007;30(3):332–40.
- (12) Ernest Hung YN, Carina CW, Oi S, William SB, Pak CH. Endometrial and subendometrial blood flow measured by three-dimensional power Doppler ultrasound in patients with small intramural uterine fibroids during IVF treatment. *Human Reprod* 2005;20(2):501–6.

- (13) Epstein E, Skoog L, Isberg PE, De Smet F, De Moor B, Olofson PA. An algorithm including results of gray-scale and power Doppler ultrasound examination to predict endometrial malignancy in women with post-menopausal bleeding. *Ultrasound Obstet Gynecol* 2002;20:370–6.
- (14) Amit A, Weiner Z, Ganem N, Kerner H, Edwards CL, Kaplan A, Beck D. The diagnostic value of power Doppler measurements in the endometrium of women with postmenopausal bleeding. *Gynecol Oncol* 2000;77(2):243–7.
- (15) Szpurek D, Sajdak S, Moszynski R, Roszak A. Estimation of neovascularisation in hyperplasia and carcinoma of endometrium using a 'power' angio-Doppler technique. *Eur J Gynaecol Oncol* 2000;21:405–7.
- (16) Aleem F, Predanic M, Calame R, Moukhtar M, Pennisi J. Transvaginal color and pulsed Doppler sonography of the endometrium: a possible role in reducing the number of dilatation and curettage procedures. *J Ultrasound Med* 1995;14:139–45.
- (17) Sheth S, Hamper UM, McCollum ME, Caskey CI, Rosenshein NB, Kurman RJ. Endometrial blood flow analysis in postmenopausal women: can it help differentiate benign from malignant causes of endometrial thickening? *Radiology* 1999;195:661–5.
- (18) Chan FY, Chau MT, Pun TC, Lam C, Ngan HY, Leong L, Wong RL. Limitations of transvaginal sonography and color Doppler imaging in the differentiation of endometrial carcinoma from benign lesions. *J Ultrasound Med* 1994;13:623–8.
- (19) Sladkevicius P, Valentin L, Marsal K. Endometrial thickness and Doppler velocimetry of the uterine arteries as discriminators of endometrial status in women with postmenopausal bleeding: a comparative study. *Am J Obstet Gynecol* 1994;171:722–8.
- (20) Alcazar JL, Galan JM, Jurado M, Lopez C. Intratumoral blood flow analysis in endometrial carcinoma: correlation with tumor characteristics and risk for recurrence. *Gynecol Oncol* 2002;84(2):258–62.
- (21) Kupesic S, Kurjak A. Uterine Lesions. *Medicinski Glasnik* 2005;2(2):49–59.
- (22) Opolskiene G, Sladkevicius P, Jokubkiene L, Valentin L. Three-dimensional ultrasound imaging for discrimination between benign and malignant endometrium in women with postmenopausal bleeding and sonographic endometrial thickness of at least 4.5 mm.. *Ultrasound Obstet Gynecol* 2010;35:94–102.
- (23) Mercé LT, Alcazar JL, Lopez C, Iglesias E, Bau S, Alvarez de los Heros J, Bajo JM. Clinical usefulness of 3-dimensional sonography and power Doppler angiography for diagnosis of endometrial carcinoma. *J Ultrasound Med* 2007;26(10):1279–87.
- (24) Alcazar JL, Galvan R. Three-dimensional power Doppler ultrasound scanning for the prediction of endometrial cancer in women with postmenopausal bleeding and thickened endometrium. *Am J Obstet Gynecol* 2009;200(1):441–6.
- (25) Tinelli R, Tinelli FG, Cicinelli E, Malvasi A, Tinelli A. The role of hysteroscopy with eye-directed biopsy in postmenopausal women with uterine bleeding and endometrial atrophy. *Menopause* 2008;15(4):737–42.