

## Case Report

# A Case of Isolated Laryngeal Candidiasis Mimicking Laryngeal Carcinoma in an Immunocompetent Individual

Arun B NAIR<sup>1</sup>, Jagdish CHATURVEDI<sup>1</sup>, Manjula Battlahalli VENKATASUBBAREDDY<sup>2</sup>, Majorie CORREA<sup>1</sup>, Nandakumar RAJAN<sup>1</sup>, Anisha SAWKAR<sup>3</sup>

Submitted: 11 Oct 2010  
Accepted: 21 Nov 2010

<sup>1</sup> Department of Otorhinolaryngology–Head and Neck Surgery, St John's Medical College, Bangalore 560 029, India

<sup>2</sup> Department of Pathology, St John's Medical College, Bangalore 560 029, India

<sup>3</sup> Department of Radiology, St John's Medical College, Bangalore 560 029, India

## Abstract

Respiratory fungal infections are usually found in immunocompromised individuals who have received either long-term steroid therapy or broad-spectrum anti-microbial therapy or have a non-resolving underlying chronic disease. These infections are seen as a part of bronchopulmonary fungal infections, and their isolated and primary occurrence as laryngeal diseases is highly uncommon. Laryngeal fungal infections can also mimic various diseases, such as gastroesophageal reflux disease, granulomatous diseases, leukoplakia, and carcinoma, thereby misleading the treating team from correct diagnosis and management. It is therefore important to identify the lesion at the earliest point possible to avoid morbid or life-threatening consequences. We report a case of isolated laryngeal candidiasis in an immunocompetent Indian male with an unusual presentation mimicking laryngeal carcinoma. The clinical and histological features are highlighted with a review of relevant literature to demonstrate the possibility of such an isolated fungal lesion, even in an immunocompetent individual.

**Keywords:** candidiasis, clinical microbiology, diagnosis, immunocompetent, laryngeal diseases, mycoses

## Introduction

Respiratory fungal infections are common occurrences; however, isolated fungal infections of the larynx are rare, accounting for approximately 40 reported cases in literature. Larynx can be involved primarily by inoculation of sputum, or secondarily to predisposing conditions. Isolated laryngeal candidiasis is infrequently recognised and poorly documented (1). It has been described in patients with predisposing factors, such as underlying chronic diseases, granulocytopenia, broad spectrum antimicrobial therapy, steroid administration, diabetes mellitus, and mechanical, chemical, or thermal injury to the mucosal barrier. Most cases are usually mild and typically show punctuate white patches on the laryngeal mucosa (2–4).

We report a case of isolated laryngeal candidiasis in an immunocompetent individual, with an unusual presentation mimicking laryngeal carcinoma, to highlight the clinical and histological features of this condition and provide a review of the relevant literatures.

## Case Report

A 73-year-old, immunocompetent male patient presented to the Department of Emergency Medicine of a tertiary referral centre in Bangalore, South India, with a 3-day history of fever, odynophagia, and respiratory distress. On examination, he was febrile with tender right-sided cervical lymphadenopathy. Haematological investigations showed elevated white blood cell count with predominance of neutrophils. Absolute neutrophilic count (5000 mm<sup>3</sup>), T4/CD4 count (900 mm<sup>3</sup>), immunoglobulin A (145 mg/dL), immunoglobulin G (1000 mg/dL), and immunoglobulin M (167 mg/dL) were in the normal range. Human immunodeficiency virus infection was ruled out by a negative ELISA. The lateral soft tissue neck X-ray showed a thumb sign suggestive of an acute supraglottitis. An office endoscopy confirmed the presence of oedematous and congested epiglottis, arytenoids, and aryepiglottic folds, along with congested

endolarynx and significant pooling of saliva. The patient was a non-smoker and hypertensive on regular treatment without any other comorbidities. A diagnosis of acute epiglottitis with laryngitis was made.

In view of respiratory distress, a single dose of 100 mg hydrocortisone was administered intravenously. He was admitted and treated conservatively with antibiotics for a week. Repeat video laryngoscopy showed an ulceroproliferative lesion involving the right aryepiglottic fold and arytenoids, extending to the medial wall of the right pyriform sinus with fixation of the right hemilarynx (Figure 1a). Contrast-enhanced computerised tomography (CT) of the neck showed a heterogeneously enhancing lesion measuring approximately  $1.5 \times 1.0$  cm in the right true and false cords with preservation of the paraglottic fat strip and causing medialisation of the cord (Figure 2). The possibility of a malignancy was considered in correlation with the clinical presentation, and the provisional diagnosis was revised to carcinoma supraglottis T3N0M0. Direct laryngoscopy and biopsy of the lesion were carried out to rule out malignancy.

Histopathological examination revealed an acute inflammatory exudate covered by necrotic tissue containing multiple spores and yeast-like organisms with slender pseudohyphae suggestive of mucosal laryngeal candidiasis (Figure 3).

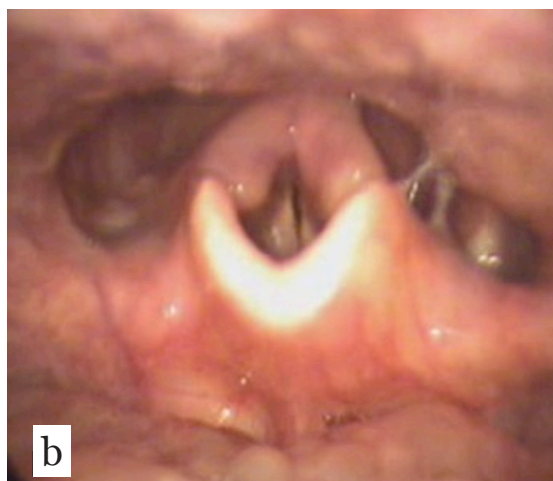
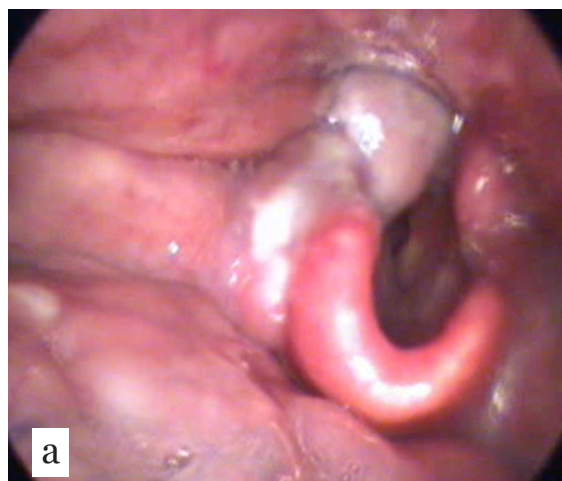
The patient was administered 200 mg of oral fluconazole once daily for 2 weeks. Video laryngoscopy after 1 week showed improvement in movements of the vocal cords on the affected side. One week later, repeat video laryngoscopy revealed a normal endolarynx with bilaterally normal vocal cord movements and absence of the

lesion (Figure 1b). Repeat CT scan also revealed a normal larynx. No sign of recurrence has been observed after 1 year of follow-up.

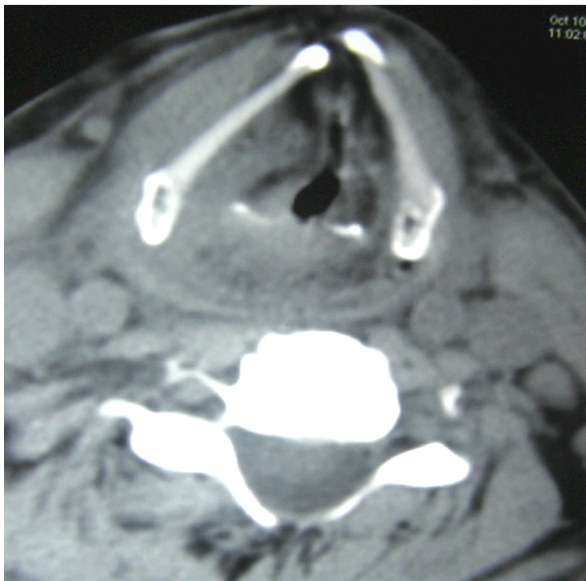
## Discussion

Fungal infections of the larynx can co-occur with bronchopulmonary fungal infections. The condition is infrequently reported as an isolated and primary laryngeal disease (5,6). *Candida* and *Aspergillus* are possible causative agents (1). Laryngeal fungal infections can mimic laryngopharyngeal reflux (LPR) disease, granulomatous diseases, leukoplakia, and carcinoma (7). When the host immune mechanisms and the protective mucosal barrier are impaired, overgrowth can lead to infections of the larynx (8). In a 10-year retrospective analysis of 54 patients, inhaled steroids were the single most common predisposing factor, as seen in 89% of patients. Conditions such as LPR produce mucosal injury through retrograde acid transit via the oesophagus, while prolonged antibiotic therapy can reduce the bacterial burden at the larynx, thereby predisposing the patient to fungal laryngitis (7).

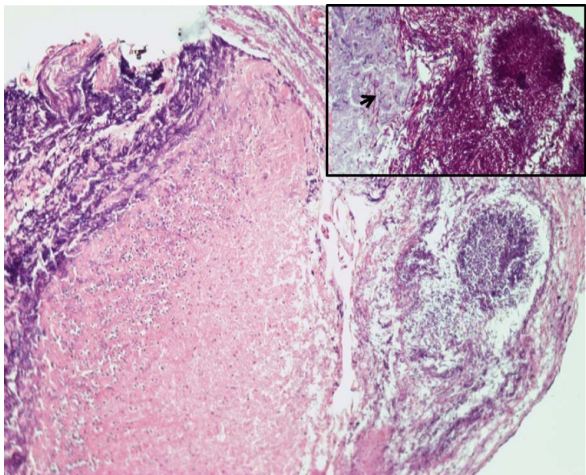
Clinical presentation of fungal laryngitis is variable and can include hoarseness, dysphagia, dysphonia, odynophagia, stridor, and respiratory distress (9). A high index of suspicion is necessary to make a diagnosis of isolated laryngeal candidiasis. *Candida albicans* usually causes superficial infections that are characterised by epithelial hyperplasia as a result of direct mucosal invasion. Most cases of muco-cutaneous candidiasis are superficial, but they can be invasive when they present with systemic manifestations of fever, chills, and malaise (9).



**Figure 1:** Images of 90° rigid optic videolaryngoscopy (a) before treatment and (b) after treatment.



**Figure 2:** Contrast-enhanced computerised tomography of the neck showing a heterogeneously enhancing lesion measuring approximately  $1.5 \times 1$  cm in the right true and false cords with preservation of the paraglottic fat strip and causing medialisation of the cord on axial view.



**Figure 3:** Haematoxylin and eosin staining (400× magnification) revealing acute inflammatory exudate covered by necrotic tissue containing multiple spores and yeast-like organisms with slender pseudohyphae suggestive of mucosal laryngeal candidiasis. Inset: Periodic acid-Schiff stain taken up by fungal colonies, showing fungal hyphae (arrow).

Video laryngoscopy typically reveals oedema, erythema, hyperkeratosis, adherent white plaques, shallow ulcerations, and white or grey pseudomembrane formations (9). Stroboscopy, although non-specific, provides important information on the integration of mucosal waves of the vocal cords. Diffuse mucosal oedema and erythema despite sufficient LPR therapy should prompt consideration of fungal laryngitis (7).

The role of biopsy is controversial, but it is justifiable if there is suspicion of a malignancy, as in this case, or of any other serious systemic disease, or if there is incomplete response to adequate therapy. The confirmation of a fungal infection can be derived from a histological evaluation. In borderline cases, laryngeal cultures and cytology can be obtained by bronchoscope brushings. Brush cytology has an advantage over biopsy in the diagnosis of mild cases because it is a less invasive procedure (8). However, the importance of laryngeal biopsy should not be underestimated, and it can be considered when a suspected fungal or bacterial infection is not responding to treatment. The possibility still remains that the patient might be suffering from a malignancy and an infection at the same time; a biopsy can help rule this out.

Treatment of laryngeal candidiasis has mainly been conservative, involving various anti-fungal drugs from intravenous amphotericin to oral fluconazole or ketoconazole to topical nystatin, based on the severity of the disease (10). The duration of treatment can vary from 10 to 30 days depending on the extent of clinical improvement. Regular videolaryngoscopy is advocated, as it not uncommon for the disease to recur (10).

Early recognition and treatment of this disease are important to prevent the spread of infection and systemic involvement. Misdiagnosis of the condition and inadequate treatment or premature biopsy can lead to impaired functioning of vocal cords and, on many occasions, a permanent disability. Sometimes an invasive infection can mask a concomitant underlying malignant lesion. Failing to perform a biopsy and performing tests for fungal diseases may allow the underlying malignancy to progress. Therefore, if a fungal pathology is ruled out, a biopsy must be considered next to rule out malignancy. Invasive laryngeal candidiasis has been traditionally linked to patients with immune deficiency. Our case demonstrates the possibility of a fungal laryngeal lesion in an immunocompetent individual and the importance of considering it as a diagnosis prior to planning a biopsy to rule out malignancy.



## Authors' Contributions

Drafting of the article: ABN, JC

Critical revision of the article: MBV, MC, NR

Final approval of the article: NR

Administrative, technical, or logistic support: AS

## Correspondence

Dr Jagdish Chaturvedi

MBBS (Rajiv Gandhi University of Health Sciences)

No 15, Type 5

NIMHANS Quarters

Dairy Circle, BRC Campus

Bangalore, 560029

India

Tel: +91-97400 76668

Email: hemoglobin84@yahoo.com

hemoglobin84@gmail.com

## References

1. Vrabec DP. Fungal infections of the larynx. *Otolaryngol Clin North Am.* 1993;**26(6)**:1091–1114.
2. Tashjian LS, Peacock JE Jr. Laryngeal candidiasis. Report of seven cases and review of the literature. *Arch Otolaryngol.* 1984;**110(12)**:806–809.
3. Neuenschwander MC, Cooney A, Speigel JR, Lyons KM, Sataloff RT. Laryngeal candidiasis. *Ear Nose Throat J.* 2001;**80(3)**:138–139.
4. Walsh TJ, Gray WC. Candida epiglottitis in immunocompromised patients. *Chest.* 1987;**91(4)**:482–485.
5. Bolivar R, Gomez LG, Luna M, Hopfer R, Bodey GP. Aspergillus epiglottitis. *Cancer.* 1983;**51(2)**:367–370.
6. Richardson BE, Morrison VA, Gapany M. Invasive aspergillosis of the larynx: Case report and review of the literature. *Otolaryngol Head Neck Surg.* 1996;**114(3)**:471–473.
7. Chandran SK, Lyons KM, Divi V, Geyer M, Sataloff RT. Fungal laryngitis. *Ear Nose Throat J.* 2009;**88(8)**:1026–1027.
8. Neuenschwander MC, Cooney A, Spiegel JR, Lyons KM, Sataloff RT. Laryngeal candidiasis. *Ear Nose Throat J.* 2001;**80(3)**:138–139.
9. Henry LR, Packer MD, Brennan J. Airway-obstructing laryngeal candidiasis in an immunocompetent host. *Otolaryngol Head Neck Surg.* 2005;**133(5)**:808–810.
10. Nunes FP, Bishop T, Prasad ML, Madison JM, Kim DY. Laryngeal candidiasis mimicking malignancy. *Laryngoscope.* 2008;**118(11)**:1957–1959.