

Retrocaval Ureter: The Importance of Intravenous Urography

Radhiana HASSAN, Azian ABD AZIZ, Siti Kamariah CHE MOHAMED

Submitted: 21 Dec 2010

Accepted: 30 Jan 2011

Department of Radiology, Kulliyah of Medicine, International Islamic University Malaysia, Bandar Indera Mahkota, 25200 Kuantan, Pahang, Malaysia

Abstract

Retrocaval ureter is a rare cause of hydronephrosis. Its rarity and non-specific presentation pose a challenge to surgeons and radiologists in making the correct diagnosis. Differentiation from other causes of urinary tract obstruction, especially the more common urolithiasis, is important for successful surgical management. Current practice has seen multislice computed tomography (MSCT) rapidly replaces intravenous urography (IVU) in the assessment of patients with hydronephrosis due to suspected urolithiasis, especially ureterolithiasis. However, MSCT, without adequate opacification of the entire ureter, may allow the physician to overlook a retrocaval ureter as the cause of hydronephrosis. High-resolution IVU images can demonstrate the typical appearance that leads to the accurate diagnosis of a retrocaval ureter. We reported a case that illustrates this scenario and highlights the importance of IVU in the assessment of a complex congenital disorder involving the urinary tract.

Keywords: computed tomography, hydronephrosis, ureteral diseases, urography, urology

Introduction

Retrocaval ureter is a rare condition that results from an anomaly in the development of the inferior vena cava (1). The incidence was reported to be approximately 1 in 1000 people, with male predominance (2). The anomalous vessel compresses the ureter, causing varying degrees of hydronephrosis. The patients are usually 30 to 40 years of age at the time of diagnosis due to the gradual development of hydronephrosis. Imaging studies are usually sufficient for an accurate pre-operative diagnosis, which is important for successful surgical intervention (2).

Case Report

A 62-year-old man was referred to the urology clinic due to incomplete voiding and dribbling of urine for the past 5 years. Clinical examination was unremarkable except for a mildly enlarged prostate gland. Laboratory investigations were normal. Ultrasound (US) of the abdomen and pelvis showed a mildly enlarged prostate. The patient was diagnosed and treated for benign prostatic hypertrophy. During the US examination, right hydronephrosis and proximal hydroureter were incidentally discovered. There was no calculus detected. Because there was evidence of a right obstructed system, abdomen and pelvis multislice computed tomography

(MSCT) was performed to rule out right ureteric calculus, which could be missed on US. MSCT showed a persistent right hydronephrosis and hydroureter but did not demonstrate any calculus. The right ureter was dilated up to its midlevel, but not traceable along the expected course distally, mainly due to poor filling of contrast within the ureter. Correlating with US findings, there is a possibility of a right ureteric stricture from a previous passage of calculus. Based on US and CT findings, cystoscopy was then performed, and kinking of the right ureter at level L3 was noted. The right ureter proximal to the kink was dilated with no intraluminal lesion seen. A right ureteric stent was then inserted. This patient had an intravenous urography (IVU) done after the procedure, and the findings were characteristic of a retrocaval ureter (Figure 1). The right retrocaval ureter could actually be seen when the axial CT images were retrospectively reviewed (Figure 2), but this was not demonstrated on the multiplanar reformatted images or the 3-dimensional reconstructed images because of poor contrast opacification of the distal ureter (Figure 3). A retrograde pyelogram (RPG) performed 2 months later showed no ureteric calculus. The patient recovered well after the removal of the ureteric stent, but he refused further surgical intervention.

Discussion

Changing practice patterns have led to MSCT replacing IVU in the assessment of patients with suspected urolithiasis, especially ureteric calculus (3,4). MSCT is preferred over IVU by physicians because of its high sensitivity (96%), specificity (99%), and accuracy (96%) for the detection of ureteric calculus (5). MSCT is fast, widely available, can be done with or without contrast, depending on clinical indication, and can also show signs of urinary tract obstruction. However, in complex cases of congenital anomaly, the diagnosis may be missed due to its rarity and subtle nature. As illustrated in our patient, MSCT scan was not able to visualise the entire right ureter during the excretory phase due to pooling of contrast in the dilated renal pelvis and proximal ureter. Thus, the multiplanar reformatted and 3-dimensional reconstruction image was not

useful in this instance. A normal size non-opacified ureter can be difficult to trace; therefore, a congenital anomaly, such as a retrocaval ureter, can be missed if it is not considered. One study reported low sensitivity (59%) in the detection of ureteral abnormality (ureteral duplication) on axial non-contrasted CT, even when the images were reviewed by radiologists who specialised in genitourinary imaging (6).

IVU has some advantages; it can provide good image resolution and the examination can be modified according to the clinical needs, for example, obtaining delayed images or changing the patient's position to try to visualise the entire length of the ureter. Although not diagnostic, the appearance of retrocaval ureter on IVU is typical and is highly suggestive of the diagnosis (7). MSCT, however, is performed to confirm the diagnosis and to rule out other causes of ureteral deviation. On a CT scan, the lateral placement

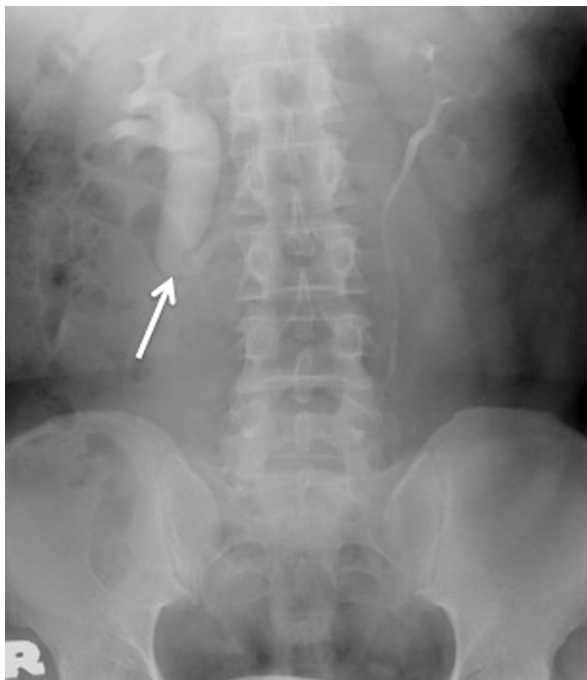

Figure 1: Intravenous urogram showing right-sided hydronephrosis and the dilation of the proximal ureter up to the level of the L3 transverse process. The medial deviation of the ureter at this level (arrow) gives rise to the typical fish hook or reversed S appearance.

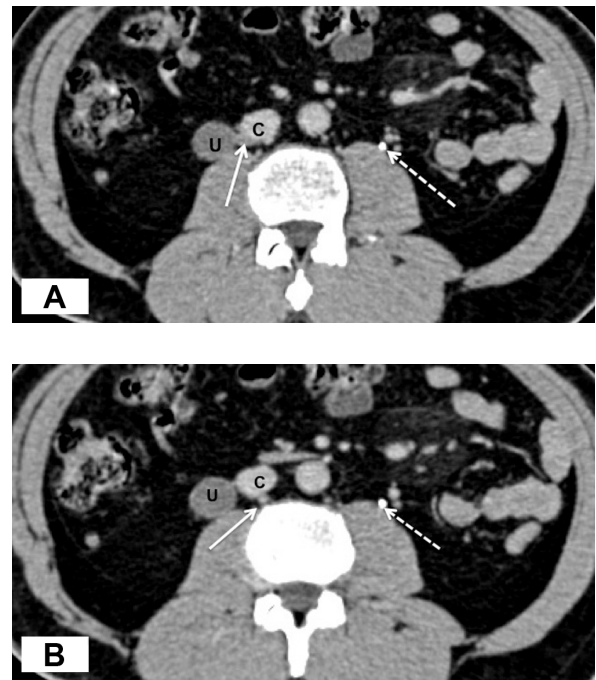


Figure 2: Contrast-enhanced computed tomography scan in the axial view showing (A) the dilated right ureter (U) proximal to its obstruction. The ureter follows a medial course at this level (solid arrow), posterior to the inferior vena cava (C). At a lower scan (B), the retrocaval location of the right ureter is medial compared with the normal location of the left ureter (dashed arrow).

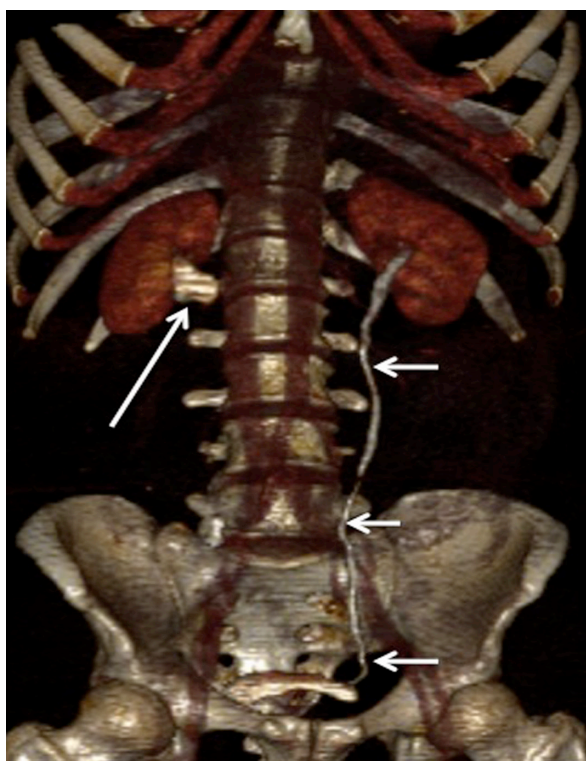


Figure 3: A 3-dimensional reconstruction image from the excretory phase of computed tomography showing the normal course and calibre of the left ureter (short arrows). However, the right ureter was not visualised due to inadequate opacification and contrast filling. The contrast is seen pooling in the dilated right renal pelvis and proximal ureter (long arrow).

of the IVC to the right pedicle is found in all patients with retrocaval ureters but in only 6% of normal patients (1,8). Recently, MRI was also reported to be useful in demonstrating retrocaval ureter and correlated well with IVU (2,9). It has the advantage of being radiation free and of providing multiplanar images. However, it may not be practical in our setting due to its high cost and limited availability in some health centres. In our case, the main focus was to detect possible ureteric calculus that was thought to cause the obstruction; therefore, when US and CT did not show any calculus, invasive procedures, such as cystoscopy and RPG, could be performed.

The radiological features of retrocaval ureter on IVU are divided into 2 types. In Type 1, the ureter crosses behind the IVC at the level of the 3rd lumbar vertebra and has a fish hook-shaped

or S-shaped deformity of the ureter. It is also known as the low loop retrocaval ureter. Marked hydronephrosis is seen in over 50% of patients. In Type 2, the retrocaval segment is at the same level as the renal pelvis; the sickle-shape appearance of the involved ureter can be resolved on IVU. Type 2 generally causes mild hydronephrosis and is less common compared with Type 1 (10).

Treatment depends on the clinical presentation, the severity of hydronephrosis, and the impairment of renal function. Patients with mild hydronephrosis without renal impairment or any associated complication can be managed conservatively with periodic examinations (2). Ureteroureteral reanastomosis anterior to the IVC with resection of the retrocaval segment is the favoured surgical treatment, with good results reported (2).

IVU, which is an old and traditional examination that is considered to be almost obsolete by some, is still valuable for the assessment of genitourinary tract pathology, especially congenital anomaly, as demonstrated in this case.

Authors' Contribution

Conception and design, drafting of the article: RH
Collection, assembly, analysis and interpretation of the data, critical revision and final approval of the article: RH, AAA, SKCM

Correspondence

Dr Radhiana Hassan
MD (USM), MMed Radiology (USM)
Department of Radiology, Kulliyah of Medicine
International Islamic University Malaysia
Bandar Indera Mahkota
25200 Kuantan
Pahang, Malaysia
Tel: +609-557 2056
Fax: +609-514 9396
Email: radhianahassan@gmail.com

References

1. Lautin EM, Haramati N, Frager D, Friedman AC, Gold K, Kurtz A, et al. CT diagnosis of circumcaval ureter. *AJR Am J Roentgenol*. 1988;**150**(3):591-594.
2. Uthappa MC, Anthony D, Allen C. Case report: Retrocaval ureter: MR appearances. *Br J Radiol*. 2002;**75**(890):177-179.
3. Chen MY, Zagoria RJ, Saunders HS, Dyer RB. Trends in the use of unenhanced helical CT for acute urinary colic. *AJR Am J Roentgenol*. 1999;**173**(6):1447-1450.

4. Kambadakone AR, Eisner BH, Catalano OA, Sahani DV. New and evolving concepts in the imaging and management of urolithiasis: Urologists' perspective. *Radiographics*. 2010;**30**(3):603–623.
5. Novelline RA, Rhea JT, Rao PM, Stuk JL. Helical CT in emergency radiology. *Radiology*. 1999;**213**(2):321–339.
6. Eisner BH, Shaikh M, Uppot RN, Sahani DV, Dretler SP. Genitourinary imaging with noncontrast computerized tomography—Are we missing duplex ureters? *J Urol*. 2008;**179**(4):1445–1448.
7. Perimenis P, Gyftopoulos K, Athanasopoulos A, Pastromas V, Barbalias G. Retrocaval ureter and associated abnormalities. *Int Urol Nephrol*. 2002;**33**(1):19–22.
8. Singh DD, Sanjeev P, Sharma RK. Images: Spiral CT evaluation of circumcaval ureter (retrocaval ureter). *Indian J Radiol Imaging*. 2001;**11**(2):83–84.
9. Dillon B, Goodman TR. A periureteric venous ring diagnosed by MRI: An unusual cause of flank pain. *Pediatr Radiol*. 2006;**36**(6):564–565.
10. Bateson EM, Atkinson D. Circumcaval ureter: A new classification. *Clin Radiol*. 1969;**20**(2):173–177.