

Case Report

Necrotizing Fasciitis on the Right Side of the Neck with Internal Jugular Vein Thrombophlebitis and Septic Emboli: A Case of Lemierre's-Like Syndrome

Dang NGUYEN, Yazmin YAACOB, Hamzaini HAMID, Sobri MUDA

Submitted: 3 Jun 2012

Accepted: 16 Mar 2013

Department of Radiology, Faculty of Medicine, Universiti Kebangsaan Malaysia Medical Centre, Jalan Yaacob Latif, Bandar Tun Razak, 56000 Cheras, Kuala Lumpur, Malaysia

Abstract

Lemierre's syndrome (LS) is a rare life-threatening infective condition typically starting with an oropharyngeal infection causing thrombophlebitis and metastatic abscesses. The most common aetiology of LS is *Fusobacterium necrophorum*; however, it can also occur after infection with other organisms. LS mainly affects young healthy adults. The initial infection site can be in the head and neck or in the abdomen. The morbidity rate of this disease is high despite aggressive treatments. In this article, we report a 63-year-old male patient with uncontrolled diabetes mellitus, presenting with *Klebsiella pneumoniae* infection-induced necrotizing fasciitis on the right side of the neck, leading to LS.

Keywords: necrotizing fasciitis, Lemierre syndrome, *Fusobacterium necrophorum*, *Klebsiella pneumoniae*

Introduction

Lemierre's syndrome (LS) or necrobacillosis, is a rare, life-threatening entity defined as infective thrombophlebitis causing metastatic abscesses. It occurs in 0.8–1.5 individuals per million people annually (1,2). In 1900, Courmont and Cade first described post-anginal sepsis associated with multiple pulmonary abscesses (3). Thereafter, in 1936, this syndrome was named after Andre Lemierre, who provided a clear description of the clinical findings in association with the isolation of bacteria in a series of 20 cases. In his reports, Lemierre termed the occurrence of thrombophlebitis and septic emboli secondary to oropharyngeal infection an 'anaerobic post-anginal septicaemia', known as the original LS, because the onset of sepsis occurred shortly after the patient's sore throat (4). LS may also occur after infection in other areas, such as mastoiditis, otitis, oropharyngitis, tonsillitis, infection of teeth and jaw, appendicitis, urinary infection, and purulent endometritis following parturition (5). Besides these initial infections, necrotising fasciitis (NF) is also known to be a rare cause of LS (6,7).

NF is another rare, fatal, soft tissue infection characterised by fast necrosis along the infected areas, including fascia, sub-cutaneous tissue and skin (6). NF was first described by Joseph Jones

during the US civil war (8). However, until 1952, Wilson was the first to use the term necrotizing fasciitis (9). Risk factors of NF include diabetes, arteriosclerosis, alcoholism, chronic renal failure, malignancy, intravenous drug abuse, and post-partum period (10). In NF, patients with factors leading to immunocompromised states (11), or those with diabetes (12) are associated with longer hospitalisation and require aggressive therapy. NF leading to LS is uncommon, especially after *Klebsiella* infection. The patient in our study was a gentleman with uncontrolled diabetic mellitus, who presented with fulminant neck NF secondary to *Klebsiella pneumoniae* infection associated with LS.

Case Report

A 63-year-old Chinese man with a known history of diabetes mellitus, hypertension, and dyslipidaemia presented with a progressive painful swelling that appeared one week back on the right side of the neck. The patient also had spiking fever, chills, and rigours, which did not improve with antibiotics. He also developed generalised weakness, cough, and lethargy.

On presentation, the patient had high grade fever and mild dyspnoea. His vital signs were a blood pressure of 164/85 mmHg, heart rate of 118 beats per minute, temperature of 39.2 °C and respiratory rate of 22 breaths per minute. His

saturated pulse oxygen (SPO₂) was 98% under room air. There was a firm mass at the right posterior triangle extending down to the right supraclavicular region with crepitus. There were grade 1 tonsils (< 25% of the lateral dimension of the oropharynx). The external acoustic canal and tympanic membranes were normal. His nasoscopy was also normal. Biochemical studies revealed increase in the total white blood cell count ($16.6 \times 10^9/L$), C-reactive protein (34.5 mg/dL-particle-enhanced turbidimetric assay) and creatinine level (191 mmol/L). The chest radiograph showed emphysematous changes on the right side of the neck. A few nodules and airspace opacities were present in both lung fields (Figure 1a).

Emergency contrast-enhanced computed tomography (CECT) of the thorax performed after the chest radiograph showed ill-defined heterogeneously enhancing hypodensities underlying the right sternocleidomastoid muscle extending from the right skull base to the anterior right chest wall with air pockets. It comprised necrotic tissues and multiple small compartment collections along the thickened superficial and muscular fascia associated with fat streakiness (Figure 1b,1c). There was involvement of the right sternocleidomastoid muscle with heterogeneous enhancement (Figure 1b). The proximal right internal jugular vein (IJV) was thrombosed (Figure 1d). Multiple lung nodules with varying sizes and sub-pleural wedge-shaped consolidations were demonstrated with the apices directing towards the pulmonary hila (Figure 1e,1f). No focal lesion was identified in the oral cavity, pharynx, and larynx. With a constellation of i) right emphysematous neck lesions, ii) right IJV thrombosis, and iii) multiple consolidated and nodular lung lesions, the patient was diagnosed with LS secondary to NF on the right side of the neck.

The patient was admitted to the intensive care unit (ICU) for stabilization, close monitoring, and nursing support. Broad-spectrum intravenous (IV) antibiotics (ceftriaxone 4 g daily and metronidazole 1 g daily) were initiated. Subsequently, incision and drainage were performed. However, on day two after admission, the patient experienced septic shock with renal impairment (creatinine 180 mmol/L, urea 24.4 mmol/L) and metabolic acidosis (pH 7.19, PCO₂ 33.4 mmHg, PO₂ 137 mmHg, HCO₃ 14.8 mmol/L, potassium 5.4 mmol/L, sodium 134 mmol/L). The patient was then administered IV noradrenaline (0.5 µg/kg/min) for haemodynamic stabilization and kept rehydrated and on sodium bicarbonate (NaHCO₃) infusion for his renal impairment

and acidosis (under observation to keep in view of haemodialysis). Because the patient progressed into septic shock, we decided to add 1.2 g IV ciprofloxacin daily (total anti-microbial medication: ceftriaxone 4 g daily, metronidazole 1 g daily and ciprofloxacin 1.2 g daily). He was intubated, sedated, and ventilated with synchronized intermittent mandatory ventilation (SIMV) mode (rate 10 bpm, pressure support 10 cmH₂O, FiO₂ 40%, PEEP 6 cmH₂O, tidal volume (VT) 470 mL/s). He also needed IV soluble human insulin (4 units/h) for his diabetes.

After four days, his acidosis improved. On the fifth day after admission, he underwent debridement surgery for the lesion on the right side of the neck because the drainage was found to be ineffective. The surgery was closely monitored by the anaesthetic team and resuscitation was performed if required. On exploration, the sub-cutaneous tissue was found to be necrotic and extending from the right base of skull to the right infraclavicular region. The necrosis also involved tail of the right parotid gland, right sternocleidomastoid muscle, part of right strap muscles, and the right pre-vertebral fascia. The carotid sheath was also necrotic, and the overlying skin was unhealthy. During the debridement surgery, all the necrotic tissue and overlying skin was excised. Right sternocleidomastoidectomy and right partial parotidectomy were performed. The right carotid artery and right IJV were exposed; however, they were left undisturbed. The wound was soaked with super-oxidised solution and packed with superoxidised solution gauze and gamgee on top.

Histopathological examination (HPE) of the excised specimens showed areas of haemorrhagic and necrotic tissue with intramuscular microabscesses within the sternocleidomastoid muscle. The lymph nodes showed reactive hyperplasia with haemorrhage and necrosis within. Ziehl-Neelsen stain was negative for acid-fast bacilli. No fungal element was identified, and no granuloma or malignancy was detected.

Two days after the surgery, his Glasgow Coma Scale (GCS) decreased to 12/15. Plain and contrast-enhanced computed tomography (CECT) of the brain showed non-enhancing hypodensity at the genu of the left internal capsule, which may represent an infarct or septic emboli (Figure 2a). Repeated CECT of the neck and thorax showed evolution of lung lesions with cavitation (Figure 2b). Pus and blood culture (the sample was obtained on day two after admission) showed *K. pneumoniae*, which was sensitive to ciprofloxacin, ceftriaxone, cefuroxime, gentamicin, amoxicillin-

clavulanate and cloxacillin, and resistant to ampicillin and metronidazole.

The patient then received 4 g ceftriaxone and 1.2 g IV ciprofloxacin daily for one more week. The metronidazole was discontinued based on the sensitivity results (metronidazole was used in the first week). His blood pressure was stable after one week of admission. He was successfully extubated and the inotrope was weaned off. The blood pH returned to the normal range after the first week (pH 7.35). The patient's renal function also improved (creatinine 191-210-150-138 mmol/L).

However, until day 10 after admission, the patient's temperature was still spiking. Blood culture and sensitivity (blood obtained at this time) showed no bacterial growth, but the wound pus and tracheal aspiration fluid cultures still isolated *K. pneumoniae*, which became resistant

to cefuroxime and gentamicin (we did not use cefuroxime or gentamicin before) and insensitive to ceftriaxone and ciprofloxacin but sensitive to meropenem. The antibiotics were changed to 3 g meropenem daily in four weeks (ceftriaxone and ciprofloxacin were administered for two weeks and then discontinued). The patient's fever had resolved after one week of meropenem. He was also administered sub-cutaneous soluble human insulin (12 units, 3 times a day), and wound dressing was carried out once daily. No anti-coagulation was indicated because the wound was still open and in thick dressing. The second blood culture performed three weeks after admission (one week after meropenem intake) was negative. There was a healing rim on the neck wound six weeks after admission, and the patient underwent split skin grafting at this time.

After completing four weeks of meropenem,

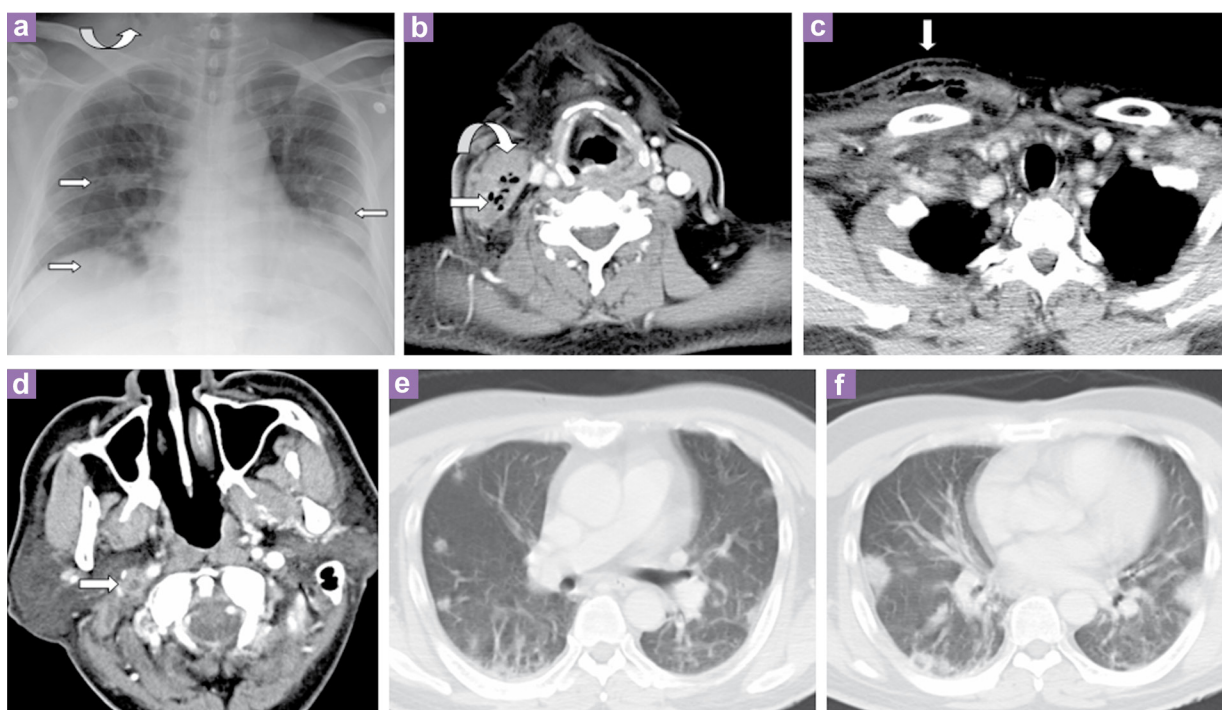


Figure 1: (a) Antero-posterior (AP) supine chest radiograph at presentation: a few airspace opacities and lung nodules was observed in both lung fields (straight arrows). Soft tissue emphysema was noted at the right neck root (curved arrow). (b) Contrast-enhanced computed tomography (CT) images showing an ill-defined heterogeneously enhancing lesion with debris, collections and emphysematous changes on the right side of the neck posteromedial to the right sternocleidomastoid muscle (straight arrow). The right sternocleidomastoid muscle was heterogeneously enhanced (curved arrow). (c) The lesion extending to the right supraclavicular fossa and anterior chest wall. The investing cervical fascia was thickened. There was adjacent fat streakiness with thickened, enhanced overlying skin (arrow). (d) Contrast-enhanced CT image, axial slices showing right internal jugular vein (IJV) thrombosis (arrow). (e,f) CT images showing multiple peripheral lung nodules with varying sizes and consolidation in both lung fields. Some of the consolidations were sub-pleural, wedge-shaped, with apices directing towards the hila.

the patient was asked to continue with four weeks of 1.5 g oral amoxicillin–clavulanate daily. No anti-coagulation was indicated because the right IJV thrombosis caused no symptom. The patient then regained a full GCS score and the wound on the right side of the neck healed after two and a half months. Blood investigation, renal profile and liver enzyme returned to their normal ranges. He subsequently developed hypertension (BP 170/80–188/90 mmHg) and was thus, administered anti-hypertensive drug (enalapril 7.5 mg daily). The chest radiograph after three months showed scattered fibrotic changes with good aeration in both lung fields and no focal active lesion. Blood investigation, renal profile, arterial blood gas, and liver enzyme had also returned to normal ranges. Physiotherapy was indicated for the patient's right lower limb weakness, and he was inquired to continue enalapril for hypertension and sub-cutaneous insulin for diabetes.

Discussion

The pathological mechanism of NF may be the result of a proteolytic enzyme causing rapid infection spread and necrosis along the tissue plane (13). Skin necrosis usually develops later and because of thrombosis of the nutrient vessels (6,13). NF most commonly occurs in the extremities and trunk after skin break, such as being after trauma or surgery (14). NF involving the head and neck is rare and usually associated

with dental infection (15), peritonsillar–pharyngeal abscess (16), neck surgery (17), steroid neck injection (18), and osteoradionecrosis (19).

The most common cause of NF is group A *beta-hemolytic Streptococcus* and is associated with underlying problems such as diabetes (20). In recent decades, its pathogenesis has usually been polymicrobial rather than monomicrobial (21). *K. pneumoniae* is a rare cause of monomicrobial necrotizing fasciitis, which was documented in some case reports (22).

The onset of NF usually occurs 2–4 days after trauma or surgery (14). It is different from other less lethal infection because of its rapid spread, which could be within hours (23). At an early stage, NF can be mistaken for the more common and usually benign neck abscess (6) or cellulitis (12), which is characterised by erythema and oedema. The indicators for NF can be sub-cutaneous emphysema, crepitus, and pain not corresponding to the skin findings (14), with numbness or no pain on palpation of the skin surrounding the lesion due to neural damage (6).

CT can reveal constant features of NF, including thickening and infiltration of cutis and sub-cutis, enhancement of superficial and deep cervical fascia, thickening of platysma, sternocleidomastoid, and strap muscles, gas formation and multicompartiment collection. CT is also helpful in detecting unsuspected lesion extension. Early detection of the condition with CT enables appropriate surgical debridement (24).

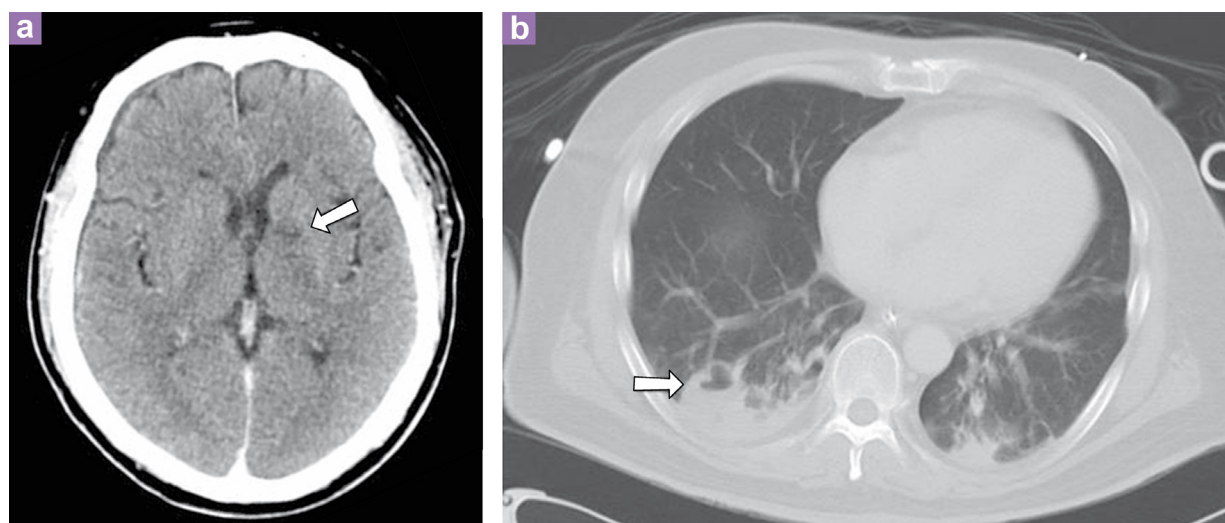


Figure 2: (a) Contrast-enhanced CT brain image showing non-enhancing hypodensity at the genu of the left internal capsule, which could be an infarct or a septic emboli (arrow). (b) Contrast-enhanced CT thorax showing lung nodules and consolidation, which showed cavitation with air–fluid level (arrow).

The patient's neck lesion with emphysematous necrotic tissues along the fascia of the sternocleidomastoid muscle and sub-cutaneous layer with multicompartiment collections were not well capsulated. The neck lesion was without a definite peripheral organised enhancement, therefore, it could not be considered an abscess. Thus, NF was diagnosed.

Another differential diagnosis of the neck lesion in this patient was gas gangrene, a type of myonecrosis in which the necrotic tissue is involved more in the muscle than along the sub-cutaneous layer or fascia. *Clostridium perfringens* is the most common organism in gas gangrene (25), and *Streptococcus beta-hemolytic* group A is the most common organism in NF. Gas gangrene and NF may occur after *Klebsiella* infection, which is considered to be a rare aetiology (26). It is difficult to differentiate between myonecrosis and NF because there are no clear distinctive features when there is extensive infected tissue. However, both entities are fatal emergency conditions with poor prognosis, requiring intensive care, and aggressive treatments (22,27).

When NF progresses further to thrombophlebitis and metastatic abscesses, it is called LS (7), which is typically initiated with an oropharyngeal infection (peritonsillar abscess, pharyngotonsillitis) causing infective thrombophlebitis and leading to septic emboli. LS commonly affects young healthy adults; however, cases of LS in children have also been reported (28). Since the advent of antibiotics, LS has been rarely encountered with only approximately 0.8–1.5 per million persons per year, which makes it a disease that has been frequently overlooked (2,6), because of which it has been termed the 'forgotten disease'.

The most common aetiology of LS is *Fusobacterium necrophorum*, accounting for 81.7% of cases. (29). *F. necrophorum* is a filamentous anaerobic gram-negative bacterium that is kanamycin and metronidazole sensitive (30). It can be found as part of normal flora in human oropharynx, genitourinary, and gastrointestinal tracts (31). The most common sites of primary *F. necrophorum* infection are the oropharyngeal cavity and the female genital tract. Bacteraemia is rare (32). Any patient with *F. necrophorum* isolated from the blood, particularly with metastatic infection, should be evaluated for LS with septic IJV thrombosis (33). Other possible pathological organisms causing LS can be *Eikenella corrodens*, *Beta-hemolytic streptococci* (29), gram-negative aerobic spp, gram-positive anaerobic cocci and *Bacteroides*

spp (34). Some of these organisms were known aetiological agents of NF (6). Occasionally, no organism was grown from clinical specimens (34). *K. pneumoniae* was also reported as one of the causes of LS (35–37).

K. pneumoniae, an enteric gram-negative bacillus, can be a normal flora of the pharynx, gastrointestinal tract and skin; however, it can infect any body organ and can more commonly be the cause of lung, urinary tract, rhinoscleroma, ozena, and nosocomial infections (22). Underlying diabetes mellitus, older age, and penicillin therapy may have shifted the flora to allow the *Klebsiella* organism to colonise and subsequently invade (35). The main reservoirs of infection are the gastrointestinal tract of the patient and the hands of hospital personnel. Extensive use of broad-spectrum antibiotics in hospitalised patients has led to increased carriage and development of multidrug-resistant strains with extended-spectrum beta-lactamase. *Klebsiella* spp have an extraordinary ability to spread and are highly virulent. The suggested antibiotics for this organism include third-generation betalactam (cefotaxime, ceftriaxone), aminoglycoside (gentamicin, amikacin), carbapenem (imipenem/cilastatin), and quinolone (38).

The association between diabetes and *K. pneumoniae* infection was mentioned in the literature. In a study of 112 diabetic patients with pneumonia, *K. pneumoniae* and *Staphylococcus aureus* were the most frequent causes (39). Although LS usually affects healthy patients, LS in patients with diabetes was also reported, and all these cases were *Klebsiella* spp infection (35–37). This is probably because of the association between diabetes and *Klebsiella* spp infection.

Besides the role of diagnostic imaging in NF, CT also plays an integral role in timely diagnosis of LS. It has consistently shown to be more sensitive than plain radiographs to detect lung lesions (40). Manifestation of metastatic lung infection in LS includes septic emboli (nodules, consolidation, cavitation) and pleural effusion. The septic emboli can be present as multiperipheral, round or wedge-shaped area with an identifiable feeding vessel, observed in two-thirds of the cases, leading into the lesions (41). Other possible sites of metastatic infection in LS include abscesses in the joints, muscles, spleen, liver, and brain. Infarction can be present as a result of small-vessel thromboarteritis, metastatic infection, or migrating thrombus secondary to carotid thromboarteritis adjacent to the infected foci. Venous thrombosis can be

detected by CT, magnetic resonance imaging and ultrasonography (31).

Awareness of this syndrome is necessary in patients presenting with upper respiratory tract infection, which rapidly progresses to pulmonary symptoms, respiratory distress, or worsening of sepsis. In our patient, sub-cutaneous emphysema was noted clinically and later confirmed by CT, which also helped characterise the neck lesion, disclose the extension and detect the venous thrombosis as well as lung nodules. Attempts to inspect a primary infective focus were unsuccessful, and no primary infection was clinically and radiologically found before the presence of the neck lesion. No oropharyngeal sepsis or related tooth extraction was identified. The grade 1 tonsils were not satisfactorily appointed as an original infective focus. The possibility of poor dental hygiene was considered; however, there was no clue or documentation to support this possibility. Because of the lack of primary infection at the nasopharyngeal region, the overall findings of the neck lesions plus right IJV thrombosis and metastatic pulmonary abscesses supported the Lemierre's-like syndrome secondary to neck NF. Studies of Moreno et al. and Meesner et al. stated that the symptoms of oropharyngeal infection can be absent or forgotten by the time the signs of jugular vein thrombosis or pulmonary emboli become prominent (29,33). Similarly, the prominent extensive neck lesion may lead to the neglect of the initial oropharyngeal infective focus.

The treatment principle of LS somehow overlaps with the treatment of NF, which includes empiric antibiotics, ICU care and surgical debridement or collection drainage. Early and extensive surgical debridement is crucial for NF, with wide incision and excision of necrotic areas to the healthy bleeding tissue (23,42). This aims to reduce the bacterial and toxin load in patients with aggressive NF (43). The wound should be left open and well irrigated. This regime can be repeated until there is emergence of fresh viable soft tissue (23,42).

For NF, after initial broad-spectrum antibiotics, the anti-microbial therapy should be based on gram stains and cultures (11,42). Antibiotics alone have been successful in treating LS, but suppurative collection may need to be drained (33). Penicillin G was frequently used to treat LS previously (44); however, because of the increasing likelihood of beta-lactamase production by *Fusobacterium* and other anaerobic mouth flora (45), a combination of

metronidazole and betalactam antibiotics may be the initial treatment of choice (35). The duration of antibiotic treatment was suggested from to be 3–6 weeks. Relapse has been documented when treatment was administered for < 2 weeks. IV antibiotics could be switched to oral therapy when the patient is afebrile and can tolerate oral doses (41).

On reviewing the literature, our antibiotics (ceftriaxone and metronidazole) were found to be appropriate to act on the most common gram-negative anaerobic organisms in LS. Ciprofloxacin can work well for gram-negative and gram-positive organisms and it can be combined with ceftriaxone and metronidazole. It is also suggested for patients with weakened immune systems and is an advisable treatment for *Klebsiella* infection (46). In the result of the first pus and blood culture, *K. pneumoniae* was isolated. It was initially sensitive to gentamicin, cefuroxime, ceftriaxone, and ciprofloxacin. However, it then became resistant to cefuroxime and gentamicin and insensitive to ceftriaxone and ciprofloxacin. This raises the possibility of cross antibiotic resistance in this organism. In a study of susceptibility of *K. pneumoniae* to ciprofloxacin and cefuroxime from 1990 to 1998, Helga Schumacher revealed an increase in cross resistance of *K. pneumoniae* to cefuroxime and ciprofloxacin from < 5% to 15% and 7%, respectively (47).

Supportive therapy consisting of fluid and electrolyte balance, blood pressure support with a vasopressor and high energy nutritional supplementation is necessary in NF. Hyperbaric oxygen therapy should be included if the patient is stable and can tolerate it (11,42).

Ligation of IJV and anti-coagulatory medication for IJV thrombosis are still controversial. This patient did not have any ligation of IJV, and no anti-coagulation administration was undertaken because the right IJV thrombosis induced no symptom. Interventional radiology may have a role when there is a need for drainage of abscesses or pleural empyema (48).

Despite the different presentations of the variant in classical LS, the poor prognosis of the disease still persists (36). With early diagnosis, the mortality rate of LS is 5–18%. Because it can be easily missed, the mortality rate would be higher (1,48). The mortality rate of NF is about 16.5–20% in recent reports (49). It becomes higher if NF involves the neck and particularly when it spreads to the mediastinum, chest, and carotid sheath (6). In those with rapid

progression (within hours), the mortality can increase to 75% if there is no early intervention (23). The mortality rate may be 100% in cases of alcoholism with *Klebsiella* bacteraemia (38).

Conclusion

We illustrate a rare case of *K. pneumoniae* infection causing NF leading to LS, a fatal condition that requires awareness during clinical practice because of its high mortality rate but has a trend of being forgotten. Not only *F. necrophorum* but also *K. pneumoniae* should be included as a cause of LS, when suspected, so that antibiotics could be administered carefully after considering the potential risk of antibiotic resistance. Because NF and LS can progress rapidly in hours, we want to emphasise the importance of early recognition, particularly in patients with co-morbidities. immunocompromised states, diabetes and alcoholism). Prompt emergency care with close haemodynamic support, empiric antibiotic administration, and early exploration as well as aggressive debridement are intensely imperative to patient survival.

Acknowledgement

I would like to express my deepest gratefulness to my supervisors who gave me help and instruction to write this article.

I also would like to thank Enago company for the English revision and MJMS Editors for their review and editing this paper.

Conflict of Interest

None.

Funds

My appreciation is extended to Dr Yazmin for her help in funding for the proofread service.

Authors' Contributions

Conception and design and collection and assembly of data: DN
Analysis and interpretation of the data: DN, SM
Drafting of the article: DN, YY
Critical revision of the article for the important intellectual content: YY, SM, HH
Final approval of the article: YY, HH
Administrative, technical or logistic support: SM, HH

Correspondence

Dr Dang Nguyen
MD (CTUMP), MMed Rad (UKM)
Department of Radiology
Universiti Kebangsaan Malaysia Medical Centre
Jalan Ya'acob Latif, Bandar Tun Razak
56000 Cheras
Kuala Lumpur, Malaysia
Tel: +6017-3165 496
Fax : +603-9173 7824
E-mail: dangnguyen094@gmail.com

References

1. Hagelskjær LH, Prag J, Malczynski J, Kristensen JH. Incidence and clinical epidemiology of necrobacillosis, including Lemierre's syndrome in Denmark 1990–1995. *Eur J Clin Microbiol Infect Dis*. 1998;**17**(8):561–565. doi: 10.1007/BF01708619.
2. Dool H, Soetekouw R, van Zanten M, Grooters E. Lemierre's syndrome: three cases and a review. *Eur Arch Otorhinolaryngol*. 2005;**262**(8):651–654. doi: 10.1007/s00405-004-0880-3.
3. Courmont P, Cade A. Sur une septico-pyohémiedé l'homme simulant la peste et causée par un streptobacille anaérobie. *Archives de Méd Exp et d'Anat Pathol*. 1900;**12**:398–418.
4. Wright WF, Shiner CN, Ribes JA. Lemierre syndrome. *South Med J*. 2012;**105**(5):283–288. doi: 10.1097/SMJ.0b013e31825581ef.
5. Lemierre A. On certain septicaemia due to anaerobic organisms. *Lancet*. 1936;**1**:701–703. doi: 10.1016/S0140-6736(00)57035-4.
6. Denganello A, Gallo O, Gitti G, De Campora E. Necrotizing fasciitis of the neck associated with Lemierre syndrome. *Acta Otorhinolaryngol Ital*. 2009;**29**(3):160–163.
7. Vaid N, Kothadiya A, Patki S, Kanhere H. Necrotising fasciitis of the neck. *Indian J Otolaryngol Head Neck Surg*. 2002;**54**(2):143–145. doi: 10.1007/BF02968735.
8. Quirk WF Jr, Sternbach G, Joseph Jones: infection with flesh eating bacteria. *J Emerg Med*. 1996;**4**(6):747–753. doi: 10.1016/S0736-4679(96)00197-7.
9. Wilson B. Necrotising fasciitis. *Am Surg*. 1952;**18**(4):416–431.
10. Kronish JW, McLeish WM. Eyelid necrosis and periorbital necrotizing fasciitis. Report of a case and review of the literature. *Ophthalmology*. 1991;**98**(1):92–98. doi: 10.1016/S0161-6420(91)32334-0.
11. Flanagan CE, Daramola OO, Maisel RH, Adkinson C, Odland RM. Surgical debridement and adjunctive hyperbaric oxygen in cervical necrotizing fasciitis. *Otolaryngol Head Neck Surg*. 2009;**140**(5):730–734. doi: 10.1016/j.otohns.2009.01.014.

12. Danic Hadzibegovic A, Sauerborn D, Grabovac S, Matic I, Danic D. Necrotizing fasciitis of the neck after total laryngectomy. *Eur Arch Otorhinolaryngol*. 2013;**270**(1):277–280. doi: 10.1007/s00405-012-1992-9.
13. Shindo ML, Nalbone VP, Dougherty WR. Necrotizing fasciitis of the face. *Laryngoscope*. 1997;**107**(8):1071–1079. doi: 10.1097/00005537-199708000-00013.
14. Bahu SJ, Shibuya TY, Meleca RJ, Mathog RH, Yoo GH, Stachler RJ, et al. Craniocervical necrotizing fasciitis: an 11-year experience. *Otolaryngol Head Neck Surg*. 2001;**125**(3):245–252. doi: 10.1067/mhn.2001.118182.
15. Moss RM, Kunpittaya S, Sorasuchart A. Cervical necrotizing fasciitis: an uncommon sequela to dental infections. *Ann Otol Rhinol Laryngol*. 1990;**99**(8):643–646.
16. Safak MA, Haberal I, Kiliç D, Göçmen H. Necrotizing fasciitis secondary to peritonsillar abscess: a new case and review of eight earlier cases. *Ear Nose Throat J* [Internet]. 2001 [cited 2012 June 20];**80**(11):824–830. Available from: <http://www.thefreelibrary.com/Necrotizing+fasciitis+secondary+to+peritonsillar+abscess%3A+A+new+case...-a080845988>.
17. Beerens AJ, Strack van Schijndel RJ, Mahieu HF, Leeman CR. Cervical necrotizing fasciitis with thoracic extension after total laryngectomy. *J Laryngol Otol*. 2002;**116**(8):639–641. doi: 10.1258/00222150260171678.
18. Harar RP, Cranston C, Warwick-Brown N. Descending necrotizing mediastinitis: report of a case following steroid neck injection. *J Laryngol Otol*. 2002;**116**(10):862–864. doi: 10.1258/00222150260293745.
19. Maluf FC, William WN Jr, Rigato O, Menon AD, Parise O Jr, Docema MF. Necrotizing fasciitis as a late complication of multimodal treatment for locally advanced head and neck cancer: a case report. *Head Neck*. 2007;**29**(7):700–704. doi: 10.1002/hed.20558.
20. Bahebeck J, Sobgui E, Loic F, Fonfoe L, Nonga BN, Mbanya JC, et al. Limb-threatening and life-threatening diabetic extremities: clinical patterns and outcomes in 56 patients. *J Foot Ankle Surg*. 2010;**49**(1):43–46. doi: 10.1053/j.jfas.2009.08.011.
21. Rouse TM, Malangoni MA, Schulte WJ. Necrotizing fasciitis: a preventable disaster. *Surgery*. 1982;**92**(4):765–770.
22. Kohler JE, Hutchens MP, Sadow PM, Modi BP, Tavakkolizadeh A, Gates JD. Klebsiella pneumoniae necrotizing fasciitis and septic arthritis: an appearance in the Western hemisphere. *Surg Infect*. 2007;**8**(2):227–232. doi: 10.1089/sur.2006.007.
23. Lanisnik B, Cizmarevic B. Necrotizing fasciitis of the head and neck: 34 cases of a single institution experience. *Eur Arch Otorhinolaryngol*. 2010;**267**(3):415–421. doi: 10.1007/s00405-009-1007-7.
24. Becker M, Zbären P, Hermans R, Becker CD, Marchal F, Kurt AM, et al. Necrotizing fasciitis of the head and neck: role of CT in diagnosis and management. *Radiology*. 1997;**202**(2):471–476.
25. Ho H, Cunha BA, Casas JBF, Maxfield D, Aragon LB, Kanlic E. Gas gangrene [Internet]. Medscape; 2011 [cited 2012 June 20]. Available from: <http://emedicine.medscape.com/article/217943-overview#a0104>.
26. DeA, Varaiya A, Mathur M, Bhesania A. Bacteriological studies of gas gangrene and related infections. *Indian J Med Microbiol*. 2003;**21**(3):202–204.
27. Stevens DL, Tanner MH, Winship J, Swarts R, Ries KM, Schlievert PM, et al. Severe group A streptococcal infections associated with a toxic shock-like syndrome and scarlet fever toxin A. *N Engl J Med*. 1989;**321**(1):1–7. doi: 10.1056/NEJM198907063210101.
28. Schmid T, Miskin H, Schlesinger Y, Argaman Z, Kleid D. Respiratory failure and hypercoagulability in a toddler with Lemierre's syndrome. *Pediatrics*. 2005;**115**(5):e620–e622. doi: 10.1542/peds.2004-2505.
29. Moreno S, García Altozano J, Pinilla B, López JC, de Quirós B, Ortega A, et al. Lemierre's disease: postanginal bacteremia and pulmonary involvement caused by *Fusobacterium necrophorum*. *Rev Infect Dis*. 1989;**11**(2):319–324.
30. Langworth BF. *Fusobacterium necrophorum*: its characteristics and role as an animal pathogen. *Bacteriol Rev*. 1977;**41**(2):373–390.
31. Karkos PD, Asrani S, Karkos CD, Leong SC, Theochari EG, Alexopoulou TD, et al. Lemierre's syndrome: a systematic review. *Laryngoscope*. 2009;**119**(8):1552–1559. doi: 10.1002/lary.20756.
32. Bouza E, Reig M, Garcia de la Torre M, Rodríguez-Créixems M, Romero J, Cercenado E, et al. Retrospective analysis of two hundred and twelve cases of bacteremia due to anaerobic microorganisms. *Eur J Clin Microbiol*. 1985;**4**(3):262–267. doi: 10.1007/BF02013649.
33. Weesner CL, Cisek JE. Lemierre's syndrome: the forgotten disease. *Ann Emerg Med*. 1993;**22**(2):256–258. doi: 10.1016/S0196-0644(05)80216-1.
34. Chirinos JA, Lichtstein DM, Garcia J, Tamariz LJ. The evolution of Lemierre's syndrome: Report of 2 cases and review of the literature. *Medicine (Baltimore)*. 2002;**81**(6):458–465.
35. Bhagat B, Ahmed M, Ali SW, Roistacher K. A case of Lemierre syndrome due to *Klebsiella pneumoniae*. *Infect Dis Clin Pract*. 1996;**5**(6):389–391.
36. Singaporewalla RM, Clarke MJ, Krishnan PU, Tan DE. Is this a variant of Lemierre's syndrome? *Singapore Med J*. 2006;**47**(12):1092–1095.
37. Garbati MA, Ahsan AM, Hakawi AM. Lemierre's syndrome due to *Klebsiella pneumoniae* in a 63 year old man with diabetes: a case report. *J Med Case Rep*. 2012;**6**:97. doi: 10.1186/1752-1947-6-97.

38. Umeh O, Berkowitz LB. *Klebsiella* Infection [Internet]. Medscape; 2011 [cited 2012 June 20]. Available from: <http://emedicine.medscape.com/article/219907-overview#a0104>.
39. Khurana RC, Younger D, Ryan JR. Characteristics of pneumonia in diabetics. *Clin Res*. 1973;**21**:629.
40. Kuhlman JE, Fishman EK, Teigen C. Pulmonary septic emboli: diagnosis with CT. *Radiology*. 1990; **174**(1):211–213.
41. Riordan T. Human infection with *Fusobacterium necrophorum* (necrobacillosis), with a focus on Lemierre's syndrome. *Clin Microbiol Rev*. 2007;**20**(4):622–659. doi: 10.1128/CMR.00011-07.
42. Krenk L, Nielsen HU, Christensen ME. Necrotizing fasciitis in the head and neck region: an analysis of standard treatment effectiveness. *Eur Arch Otorhinolaryngol*. 2007;**264**(8):917–922. doi: 10.1007/s00405-007-0275-3.
43. Gunnarsson GL, Brandt PB, Gad D, Struve C, Justesen US. Monomicrobial necrotizing fasciitis in a white male caused by hypermucoviscous *Klebsiella pneumoniae*. *J Med Microbiol*. 2009;**58**(11):1519–1521. doi: 10.1099/jmm.0.011064-0.
44. Sinave CP, Hardy GJ, Fardy PW. The Lemierre's syndrome: thrombophlebitis of the internal jugular vein secondary to oropharyngeal infection. *Medicine (Baltimore)*. 1989;**68**(2):85–94.
45. Appelbaum PC, Spangler SK, Jacobs MR. Beta-lactamase production and susceptibilities to amoxicillin, amoxicillin clavulanate, ticarcillin, ticarcillin clavulanate, ceftiofur, imipenem and metronidazole of 320 non-*Bacteroides fragilis* *Bacteroides* isolates and 129 *fusobacteria* from 28 U.S. Centers. *Antimicrob Agents Chemother*. 1990; **34**(8):1546–1550. doi: 10.1128/AAC.34.8.1546.
46. Ciprofloxacin. MIMS Malaysia [Internet]. UBM Medica; 2008 [cited 2012 June 20]. Available from: <http://www.mims.com/Malaysia/drug/info/Ciproba y/?q=ciprofloxacin&type=full>.
47. Schumacher H, Scheibel J, Moller JK. Cross resistance patterns among isolates of *Klebsiella pneumoniae* with decrease susceptibility to cefuroxime. *J Antimicrob Chemother*. 2000;**46**(2):215–221. doi: 10.1093/jac/46.2.215.
48. McMullan R, McConville C, Clarke JC, Adams DA, Hedderwick S. Lemierre syndrome: remember the forgotten disease. *Ulster Med J*. 2004;**73**(2): 123–125.
49. Marty-Ané CH, Berthet JP, Alric P, Pegis JD, Rouvière P, Mary H. Management of descending necrotizing mediastinitis: an aggressive treatment for an aggressive disease. *Ann Thorac Surg*. 1999; **68**(1):212–217. doi: 10.1016/S0003-4975(99)00453-1.