

# Clinical Determinants of Fluorodeoxyglucose Positron Emission Tomography/Computed Tomography in Differentiated Thyroid Cancer Patients with Elevated Thyroglobulin and Negative <sup>131</sup>Iodine Whole Body Scans after <sup>131</sup>Iodine Therapy

Syed Ejaz SHAMIM<sup>1,3</sup>, Lee Boon NANG<sup>2,5</sup>, Ibrahim Lutfi SHUAIB<sup>3</sup>, Nor Asiah MUHAMAD<sup>4</sup>

Submitted: 12 Mar 2013  
Accepted: 7 Mar 2014

<sup>1</sup> Department of Nuclear Medicine, Radiotherapy and Oncology, Hospital Universiti Sains Malaysia, 16150 Kubang Kerian, Kelantan, Malaysia

<sup>2</sup> Department of Nuclear Medicine, Hospital Kuala Lumpur, Jalan Pahang, 50586 Kuala Lumpur, Malaysia

<sup>3</sup> Advanced Medical and Dental Institute, Universiti Sains Malaysia, No 1-8, Persiaran Seksyen 4/1, Bandar Putra Bertam, 13200 Kepala Batas, Pulau Pinang, Malaysia

<sup>4</sup> Institute for Medical Research, Jalan Pahang, 50586 Kuala Lumpur, Malaysia

<sup>5</sup> Department of Nuclear Medicine, Hospital Putrajaya, Jalan P9, Presint 7, 62250 Putrajaya, Wilayah Persekutuan Putrajaya, Malaysia

## Abstract

**Background:** A cross-sectional prospective study has been conducted on differentiated thyroid cancer (DTC) patients using negative <sup>131</sup>Iodine (<sup>131</sup>I) whole body scans and elevated thyroglobulin (Tg) levels. The main objective of this research was to determine the prevalence of the conversion of differentiated to dedifferentiated thyroid cancer patients during follow up at the Hospital Kuala Lumpur. It has been demonstrated that fluorodeoxyglucose (FDG) uptake is inversely proportional to the iodine concentration and to differentiation of the cells.

**Methodology:** Thirty-five patients with histologically proven DTC that have undergone total or near total thyroidectomy, and post <sup>131</sup>I radioactive iodine ablation therapy, were selected and prospectively analysed. The patients also had to show at least one negative whole body scan and Tg levels of 10 µg/L and above. The results of the FDG-Positron Emission Tomography/Computed Tomography (PET/CT) were then studied to determine the association and the predictors influencing the outcome by using univariable and multivariable analyses.

**Results:** Out of the thirty-five patients, 60% of them (twenty-one) showed positive results and 40% (fourteen) showed negative. Age, gender, and type of histopathology (HPE) showed significant associations with the positive results of the FDG-PET/CT. The results also showed no correlations observed between the Tg levels and standardised uptake value (SUV)max in the DTC patients with positive disease findings in the FDG-PET/CT. The predictor for this study was age.

**Conclusion:** The prevalence of the conversion of differentiated to dedifferentiated thyroid cancer among patients with negative <sup>131</sup>I and elevated Tg was 60%, with age as the predictor. DTC patients aged 45 year-old and older were seven times more likely to have positive results of FDG-PET/CT imaging.

**Keywords:** thyroid cancer, iodine, whole body scan, thyroglobulin, fluorodeoxyglucose F18, positron-emission tomography

## Introduction

Thyroid carcinoma is rare among human malignancies (< 1%) but is the most frequent endocrine cancer, accounting for about 5% of

thyroid nodules. The latter occur frequently in the general population and, according to the method of detection and the age of the patient, their prevalence may approach 20–50% of the population, thus representing a daily issue in

endocrine clinics. Furthermore, the incidence of thyroid cancer (mainly differentiated) is one of the most rapidly increasing of all human cancers, with the papillary histotype being the most frequent (nearly 80%). In Malaysia, in 2006, it was the sixth most frequent of all cancers (1) and will probably move up in the next decade.

In this study, the potential role of fluorodeoxyglucose positron emission tomography/computed tomography (FDG-PET/CT) scanning was investigated in differentiated thyroid cancer. Aggressive forms of thyroid cancer are more likely to metastasize, and at the same time, be more metabolically active, taking up FDG and being visualised on FDG-PET/CT whole body scanning. However, cells of high grade tumours often lose their differentiated functions, such as the uptake of iodine, which is a major therapeutic problem, especially in patients with nonsurgical metastatic foci or local recurrence. Therefore, they are likely to be missed on diagnostic value whole body scan (DxWBS) and therapeutic dose whole body scan (TxWBS) levels (2).

There is ongoing debate over the management of differentiated thyroid cancer (DTC) with respect to the extent of thyroid resection, indications for radioactive iodine treatment, and the extent of thyroid hormone suppression therapy. Progressive dedifferentiation of thyroid cancer cells leads to a loss of iodine concentrating ability, with resultant false negative whole body radioactive iodine scans in approximately 20% of all differentiated metastatic thyroid cancer lesions. Finally, the outcomes of this study (hopefully) will help in understanding the pathophysiology of differentiated thyroid cancer. Overall, the aim of this study is to determine the prevalence of the conversion of differentiated to dedifferentiated lesions among thyroid cancer patients during follow up at Hospital Kuala Lumpur (HKL).

## Materials and Methods

This cross-sectional study was conducted in the Department of Nuclear Medicine at Hospital Kuala Lumpur and Department of Nuclear Medicine, Hospital Putrajaya. The study participants included patients who have DTC and were referred to Hospital Kuala Lumpur, undergoing FDG-PET scanning at Hospital Putrajaya. The study period was 18 months, while the period for the collection of the data was 12 months, beginning in April 2010 and finishing in April 2011.

The inclusion criteria for the  $^{131}\text{I}$  WBS

included all patients diagnosed histopathologically with thyroid cancer, and those who underwent total thyroidectomy or near total thyroidectomy and post  $^{131}\text{I}$  radioactive iodine ablation therapy. Additionally, they had one or more consecutive negative  $^{131}\text{I}$  whole body scans, thyroglobulin (Tg) levels of 10  $\mu\text{g/L}$  and above and thyroid stimulating hormone (TSH) levels  $> 30 \text{ mU/L}$ . The study participants must also have stopped taking L levothyroxine (L4) for at least four weeks and consuming high levels of iodine and seafood for at least two weeks. Patients who were pregnant and who received thyrotropin  $\alpha$  (recombinant human thyroid stimulating hormone) were excluded from the  $^{131}\text{I}$  WBS.

Differentiated thyroid cancer patients with negative  $^{131}\text{I}$  whole body scans were eligible for FDG-PET/CT scans. However, patients with high serum glucose levels ( $> 8 \text{ mmol/L}$ ) and those who were too agitated, uncooperative or claustrophobic were excluded from the FDG-PET/CT scan.

### Sample size

The sample size of this study was calculated using the Open Epi Version 2.3 software with a  $\beta = 80\%$  power of the study, while the 5% precision  $\alpha$  was 95%. The prevalence of differentiated thyroid cancer based on a previous study done by Pacini et al. in 2006 was 20% (3). The minimum sample size required for this study was 26 respondents, with an additional 20% for a final total of 31 respondents.

### Variable definition

#### Differentiated thyroid cancer

Thyroid carcinoma has three main histological types: differentiated (including papillary, follicular, and Hürthle cell), medullary and anaplastic (aggressive undifferentiated tumour).

#### Thyroglobulin

Thyroglobulin (Tg) is the matrix protein within the thyroid gland that provides the physical backbone for thyroid hormone synthesis. In addition, to this important function, Tg also serves as a specific biomarker of papillary and follicular thyroid cancer, and is one of the main antigens in autoimmune thyroid disease. A variety of methods have been used to detect Tg expression, including immunohistochemical, cytological, molecular, and biochemical. The quantitative evaluation of Tg expression is highly

dependent on the detection method, sample type and stage of malignant transformation (4).

### <sup>131</sup>I whole body scans

Although performed to detect areas of uptake following diagnostic or therapeutic <sup>131</sup>I, the WBS is not very useful when there are large amounts of thyroid tissue remaining after surgery, which prevent the TSH from rising above 30 mU/mL. Generally, the two “markers”, Tg and <sup>131</sup>I WBS, when used at the same time, offer the best possibilities in the follow-up of patients with DTC.

### Fluorodeoxyglucose-positron emission tomography (FDG-PET)

Positron emission tomography (PET) is a scintigraphic technique which provides better resolution than conventional scans. Fluorine-18 fluorodeoxyglucose (FDG) is a glucose analogue which is taken up and phosphorylated like glucose, but does not undergo further metabolism. FDG phosphate is trapped in the cell, and an elevated FDG-uptake is known in malignant tissue. Carcinomas of a high malignancy grade usually show a more intense glucose uptake than low-grade tumours. Therefore, FDG-PET is regarded as useful in patients with an elevated Tg and negative results of <sup>131</sup>I-scintigraphy.

### Statistical analysis

Software package used for statistical analysis (SPSS) version 16 was used to analyse the data, and descriptive statistics were applied to all variables, including age, gender, race, occupation, clinical characteristics, and the results of the FDG-PET/CT. The age variable was summarised by the mean and standard deviation (SD) while the categorical variables, such as the type of surgery, histopathological examination, FDG positivity SUV, and level of Tg were summarised as frequencies and percentages (%).

A possible correlation between the levels of Tg and SUV among DTC patients in this study, with positive result of the FDG-PET/CT, were also analysed using the Spearman correlation test. The Pearson chi-square and multivariable binary logistic regression (MLogR) were performed to determine the association between socio-demographic and clinical factors and FDG-PET/CT positivity. All of the independent variables with  $P < 0.25$ , and parsimonious, biologically or clinically important variables that were tested

in the SLogR were then included in the MLogR modelling. The assumptions of the MLogR were checked before proceeding with variable selection, which was done by using forward inclusion and backward elimination methods. The multicollinearity and two-way interactions between the independent variables were checked, and the final model was then tested for goodness-of-fit using the Hosmer-Lemeshow test and area under the receiver operating characteristics (ROC) curve. The findings of the MLogR were presented as the adjusted odds ratio (OR), 95% confidence interval (CI) and  $P$  values, and the level of significance was set at  $P < 0.05$ .

## Results

From a total of thirty-five differentiated thyroid cancer patients who underwent FDG-PET/CT, twenty-one patients had positive results. The prevalence of positive FDG-PET/CTs among differentiated thyroid cancer patients with negative diagnostic <sup>131</sup>I whole body scans was 60%.

A univariable analysis ( $\chi^2$  test) was done on all of the independent variables. Table 1 shows that the variables of age and gender have significant associations with the results of the FDG-PET/CT. Of the study participants, 76.2% (16) of the patients aged 45 and above had positive results of the FDG-PET/CT. Of those aged below 45, 23.8% (5) showed positive results of the FDG-PET/CT. There was a statistically significant difference in that 57.1% of the females (12) had positive results of the FDG-PET/CT when compared to the males (42.8%) (9).

Among the clinical determinants (Table 2), the only type of HPE showing a significant association with the results of the FDG-PET/CT was that 90.5% of the papillary thyroid cases were positive, and 9.5% (2) of the follicular thyroid cases were. The Tg levels also showed no significant differences with the results of the FDG-PET/CT (Table 3). There was no correlation observed (with a Spearman correlation coefficient of 0.257 and  $P = 0.26$ ) between the Tg levels and SUV in patients with DTC and positive disease findings in the FDG-PET/CT (Figure 1).

The multivariable analysis using the multiple logistic regression analysis was done on the three significant variables from the previous  $\chi^2$  test, that is, age, gender, and type of HPE, to determine the predictors among the patients in this study. Table 4 shows that age has a significant  $p$  value in this predictor model ( $P < 0.05$ ).

**Table 1:** Association between socio-demographic factors and result of FDG-PET among DTC patients with elevated Tg and negative whole body scan

Variables	Frequency (%)				$\chi^2$	<i>P</i> value
	Positive <i>n</i> = 21		Negative <i>n</i> = 14			
	<i>n</i>	%	<i>n</i>	%		
Age						
Below 45	5	23.8	11	78.6	10.151	0.001
45 and above	16	76.2	3	21.4		
Gender						
Male	9	42.9	1	7.1	5.250	0.028
Female	12	57.1	13	92.9		
Race						
Malay	18	85.7	10	71.4	1.071	0.401
Non malay	3	14.3	4	28.6		
Occupation						
employed	10	47.6	11	78.6	3.353	0.067
unemployed	11	52.4	3	21.4		

Chi square test: significant when  $P < 0.05$ .**Table 2:** Association between clinical determinants and result of FDG-PET/CT among DTC patients with elevated Tg and negative whole body scan

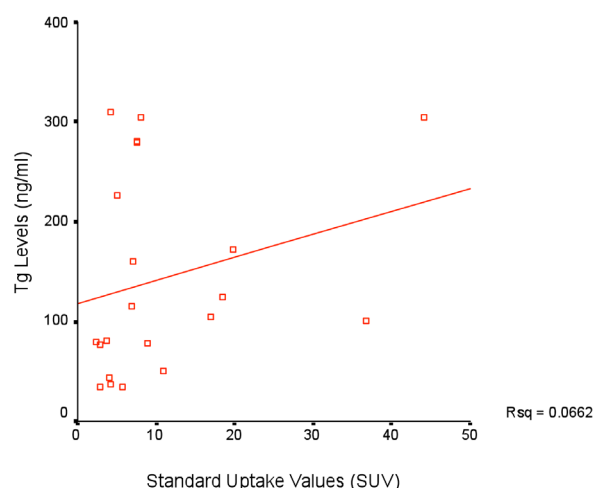
Variables	Frequency (%)				$\chi^2$	P value
	Positive n = 21		Negative n = 14			
	n	%	n	%		
Type of Surgery						
Completion Thyroidectomy	4	19.0	5	35.7	1.222	0.432
Total Thyroidectomy	17	81.0	9	64.3		
Type of histopathology examination						
Follicular	2	9.5	6	42.9	5.293	0.039
Papillary	19	90.5	8	57.1		
Localisation of Positivity						
Thyroid bed	12	57.1	10	71.4	0.734	0.392
Extra thyroidal site	9	42.9	4	28.6		
Standardised Uptake Value (SUVmax)						
Less than 3	3	14.3	2	14.3	0.000	1.000
3 and above	18	85.7	12	85.7		

Chi square test: significant when  $P < 0.05$ .

## Discussion

Based on this study, age, gender, and type of HPE showed a significant association ( $P < 0.05$ ) with the results of the FDG-PET/CT imaging. These findings were similar to previous results (5) where many formal prognostic systems recognized that the age at diagnosis, gender, histological features, tumour size, extrathyroidal extension, and clinical stage are key predictors of survival.

Age is a critical predictor of patient outcome; patients aged  $> 40$  year-old have increased recurrence rates, and the rates become significantly worse after 60 years of age (6). The most important prognostic factors include age and gender for good disease-specific outcomes in the majority of patients (7).



**Figure 1:** Correlation Graph of Tg levels and SUVmax.

**Table 3:** Association between clinical determinants (Tg Levels) and result of FDG-PET/CT among DTC patients with elevated Tg and negative whole body scan

Variables	Frequency (%)						
	Positive <i>n</i> = 21		Negative <i>n</i> = 14		<i>P</i> value	95.0% CI	
	<i>n</i>	%	<i>n</i>	%		Lower	Upper
10–100 µg/L	9	42.9	9	64.3	0.576	0.638	2.244
101–200 µg/L	6	28.6	1	7.1			
201–300 µg/L	3	14.3	2	14.3			
> 300 µg/L	3	14.3	2	14.3			

Simple Logistic Regression,  $P < 0.05$ .

**Table 4:** Results from multiple logistic regression as predictors for FDG-PET/CT results

Variables	Frequency (%)							
	Positive n = 21		Negative n = 14		P value	Adj OR	95.0% CI.for EXP(B)	
	n	%	n	%			Lower	Upper
Age								
Below 45	5	23.8	11	78.6	0.037	6.712	1.125	40.038
45 and above	16	76.2	3	21.4				
Gender								
Male	9	42.9	1	7.1	0.100	0.093	0.006	1.570
Female	12	57.1	13	92.9				
Type of histopathology examination								
Follicular	2	9.5	6	42.9	0.104	0.132	0.011	1.520
Papillary	19	90.5	8	57.1				

A study conducted in Malaysia reported that older age was associated with lower relative survival caused by rapid metastatic progression in patients aged 40 years old and older. The female to male ratio was higher, although the survival probabilities in their study were not significantly different, and they also concluded that age was one of prognostic factors for differentiated thyroid cancer patients in the Hospital Universiti Sains Malaysia (HUSM) (8). Women are 2 to 4 times more likely to develop differentiated thyroid cancer, with a median age at diagnosis between 40 and 50 years (9).

A study done on 22 patients with papillary thyroid cancer evaluated by FDG-PET/CT imaging, in cases of negative  $^{131}\text{I}$  whole body scans, a sensitivity and specificity of 80% and 83% were found. The study also concluded that FDG-PET/CT appears to be effective for detecting recurrent or metastatic differentiated thyroid cancer, particularly in patients with negative radioiodine scans and elevated Tg levels (10).

More recently, it was reported that there was a significant correlation between FDG uptake and the stage of thyroid cancer in both papillary carcinoma and follicular carcinoma, among all of their patients that had elevated Tg levels (11).

The most prevalent mutation identified to date involves an intracellular effector in this mitogen-activated protein kinase (MAPK) cascade known as BRAF. The V600E BRAF mutation has been identified in 33–73% of the cases of papillary thyroid cancer. Several studies have identified this mutation as an independent predictor of tumour recurrence (12).

This study has shown no correlation between the Tg levels and the SUVmax in DTC patients with positive results in the FDG-PET/CT. Consideration should be given that the low degree of malignancy in DTC and its slow growth resulted in lower glucose metabolism than other tumours with a greater degree of malignancy. For this reason, the SUVmax is not as reliable as in other tumours, since malignant lesions with a maximum SUVmax of less than three have been found. High levels of serum Tg have been found more often in patients with follicular thyroid cancer than in patients with papillary thyroid cancer (13).

$^{18}\text{F}$ -FDG PET/CT is useful in the detection of differentiated thyroid cancer residual, recurrent or metastatic disease in patients with elevated Tg and negative  $^{131}\text{I}$  whole body scans (14).

Aggressive forms of thyroid cancer are more likely to metastasize, and at the same time, be more metabolically active, therefore, taking up

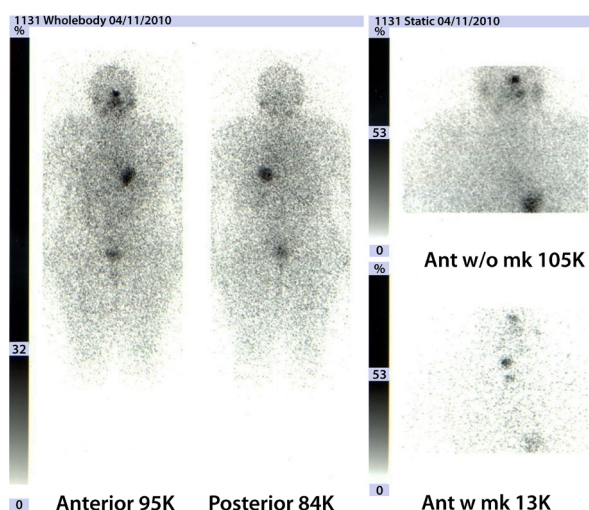
FDG and being seen on FDG-PET/CT whole body scanning. However, cells of high-grade tumours usually lose some of their differentiated functions, such as the uptake of iodine, and therefore, are likely to be missed on DxWBS and TxWBS. They also found that high median SUVs and the correlation between positive FDG-PET/CT scans and the long-term course of the disease suggest further exploration of the potential role of FDG-PET/CT in the initial evaluation of DTC (15).

Long-term surveillance strategies can also be modified according to the risk of recurrence. Low-risk patients are those who do not have nodal or distant metastasis, residual disease, or aggressive histological features. Intermediate risk patients have microscopic extrathyroidal extensions, or aggressive histological features such as lymphovascular invasion or tall cell, insular or columnar cell carcinomas. High-risk patients include those with distant metastases, evidence of extrathyroidal  $^{131}\text{I}$  uptake, incomplete resection, or macroscopic tumour invasion. Surveillance methods include whole-body radioiodine scanning, simultaneous measurements of serum TSH, Tg and anti-thyroglobulin antibodies, physical exam and neck ultrasound.

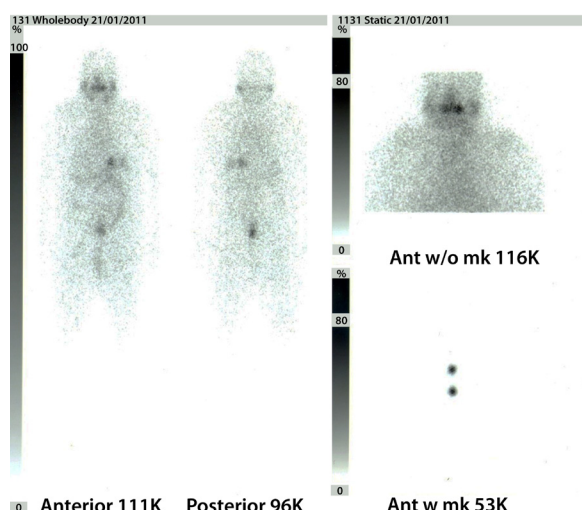
FDG-PET/CT is no substitute for  $^{131}\text{I}$  WBS. However, in patients with elevated Tg levels and negative  $^{131}\text{I}$  WBS, FDG-PET/CT can be used to detect lymph node metastases, while spiral computed tomography is necessary for the detection of small pulmonary metastases. Additionally, the widely accepted 1 cm limit for the lymph node diameter in anatomical imaging does not apply to FDG-PET/CT. In this sense, FDG-PET/CT can be used to complement ultrasonography or MRIs. Finally, FDG-PET/CT may improve the diagnostic information on which surgical strategy is based by revealing further metastases in normal-sized lymph nodes in the same compartment as the enlarged node and/or in additional lymph node compartments (16).

FDG-PET/CT has sensitivity and specificity for the detection of recurrences or distant metastases that range from 45–100% and 42–90%, respectively. Its sensitivity is greater in patients with negative scans since the FDG uptake is inversely proportional to the iodine concentration and to the differentiation of the cells. Therefore, the PET is more effective in poorly differentiated tumours that do not take up iodine (17).

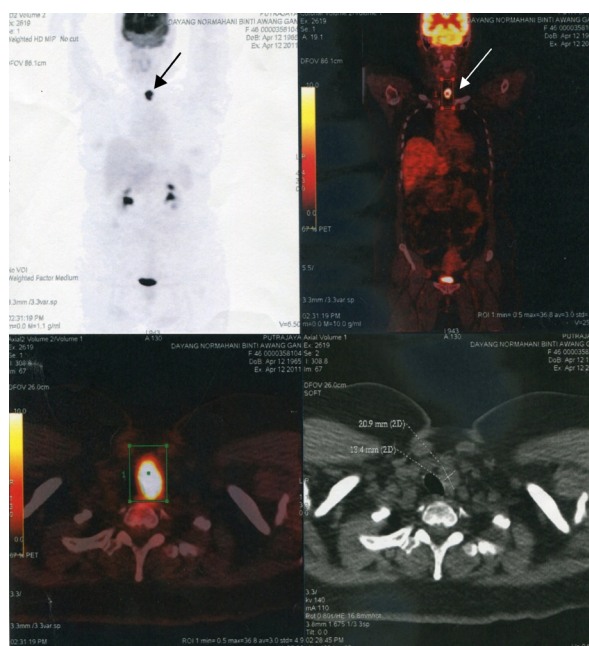
FDG-PET/CT is useful in patients with elevations of Tg due to the inverse relationship between loss of iodine avidity and gain of glucose utilization that occurs with tumour



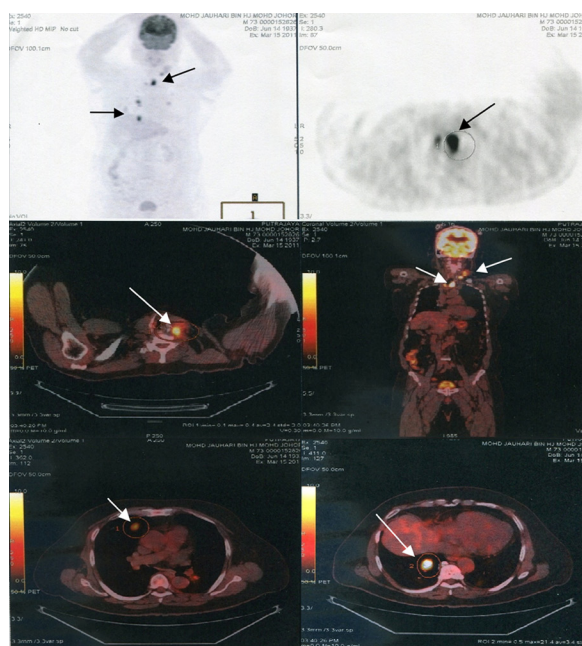
**Figure 2:** A 46-year-old female with history of papillary thyroid cancer who underwent total thyroidectomy followed by radioiodine ablation with two negative  $^{131}\text{I}$  diagnostic whole body scan and elevated thyroglobulin (155  $\mu\text{g/L}$ ).



**Figure 4:** A 73-year-old male with history of papillary thyroid cancer who underwent total thyroidectomy followed by radioiodine ablation with two negative  $^{131}\text{I}$  diagnostic whole body scan and elevated thyroglobulin (78  $\mu\text{g/L}$ ).



**Figure 3:**  $^{18}\text{F}$ FDG-PET/CT showed focus of FDG hypermetabolism at left thyroid bed (arrow), which was diagnosed as FDG avid local recurrence.



**Figure 5:**  $^{18}\text{F}$ FDG-PET/CT showed Foci of FDG hypermetabolism at left thyroid bed, left cervical lymph nodes and multiple lung nodules in the right lung (arrow) which was diagnosed as FDG avid local recurrence and metastases to lymph nodes in the neck and lung.

dedifferentiation (Figure 2–5). PET has a sensitivity of 50–70% with an increase in sensitivity as the Tg level increases. HCC, in particular, has high avidity for FDG and the avidity may also have prognostic significance; metastatic HCC lesions with a higher maximum SUVmax ( $> 10$ ) have been associated with a poorer outcome compared to those with a lower SUVmax (5-year mortality of 64% vs 92%) (18).

Two decades of FDG-PET/CT have introduced molecular imaging into daily clinical practice. The visual assessment of PET-CT/CT currently suffices for various clinical situations, and it has become a standard test for indications in many institutes. So far, the lack of ‘quantitative’ quality control and assurance has slowed the progress of PET into the field of prognostication and qualification as a biomarker of response to therapy. Apparently, the switch from the qualitative into the quantitative domain requires a different mind-set of imaging specialists. Recent standardisation efforts have now introduced generally applicable procedures which will help to move the field into the quantitative domain that is essential for truly personalised medicine. An important lesson from the FDG experience is that the introduction of new technology requires a structured and multidisciplinary approach of technical and biological validation, to avoid endless cycles of ‘trial and error’.

### Study Limitations

Estimates of the association might be biased due to a correlation between unobserved factors associated with treatment selection and outcomes, such as the patient’s preference due to small sample size, financial, and time constraints.

It is worth mentioning that the low degree of malignancy of differentiated thyroid cancer and its slow growth results in lower glucose metabolism than other tumours with greater degrees of malignancy. For this reason the SUVmax is not as reliable as in other tumours, since malignant lesions with a maximum SUVmax of 2.4 have been found, and the resolution limit of the millimetric lesions, especially when they have a low degree of malignancy, should be considered.

### Conclusions

In conclusion, the prevalence of positive results for FDG-PET/CT imaging in this study was 60%, with age as the predictor. Differentiated thyroid cancer patients aged 45 year-old and

older were seven times more likely to have positive results of the FDG-PET/CT imaging. Special consideration and priority should be given in this age group to look for recurrence or occult metastasis. Recent advances in the understanding of differentiated thyroid cancer tumour biology hold promise for improving the ability to predict tumour behaviour and aggressiveness, thereby allowing more appropriate risk stratification, imaging surveillance, and treatment.

### Acknowledgement

The authors would like to thank Dato’ Dr Muhamed Ali Abdul Khader and Prof Madya Wan Ahmad Kamil Wan Abdullah for their valuable guidance, encouragement and never ending support.

### Conflict of Interest

None.

### Funds

Advanced Medical and Dental Institute, USM, funded this research for patients investigation and Honorarium.

### Authors’ Contributions

Conception and design, analysis and interpretation of the data, drafting of the article, provision of study materials or patient, obtaining of funding and collection and assembly of data: SES

Analysis and interpretation of the data and statistical expertise: NAM

Critical revision of the article for the important intellectual content, final approval of the article and administrative, technical or logistic support: LBN, ILS

### Correspondence

Dr Syed Ejaz Shamim  
MBBS (SMC), MMed (USM)  
Department of Nuclear Medicine  
Radiotherapy and Oncology  
Hospital Universiti Sains Malaysia  
16150 Kubang Kerian  
Kelantan, Malaysia  
Tel: +609-767 6684  
Fax: +609-764 4416  
Email: drejaz9@gmail.com

## References

1. Lim GCC, Yahaya H, Lim TO. The first report of the National Cancer Registry Cancer Incidence in Malaysia. Kuala Lumpur (MY): National Cancer Registry; 2002.
2. Al-Zahrani AS, Abouzied MEM, Abdel Salam S, Mohammed G, Rifai A, Al Sugair A, et al. The role of F-18-fluorodeoxyglucose positron emission tomography in the postoperative evaluation of differentiated thyroid cancer. *Eur J Endocrinol*. 2008;**158**(5):683–689. doi: 10.1530/EJE-07-0903.
3. Pacini F, Schlumberger M, Dralle H, Elisei R, Smit JWA, Wiersinga W, et al. European consensus for the management of patients with differentiated thyroid carcinoma of the follicular epithelium. *Eur J Endocrinol*. 2006;**154**(6):787–803. doi: 10.1530/eje.1.02158.
4. Lin JD. Thyroglobulin and human thyroid cancer. *Clin Chimica Acta*. 2008;**388**(1–2):15–21.
5. Wang W, Macapinlac H, Larson SM, Ueh SD, Akhurst T, Finn RD, et al. [18F]-2-Fluoro-2-Deoxy-D-Glucose Positron Emission Tomography Localizes Residual Thyroid Cancer in Patients with Negative Diagnostic 131I Whole Body Scans and Elevated Serum Thyroglobulin Levels. *J Clin Endocrinol Metab*. 1999;**84**(7):2291–2302.
6. Sipos and Mazzaferri. Thyroid Cancer Epidemiology and Prognostic Variables. *Clin Oncol (R Coll Radiol)*. 2010;**22**(6):395–404. doi: 10.1016/j.clon.2010.05.004.
7. Palme CE, Waseem Z, Raza SN, Eski S, Walfish P, Freeman JL. Management and Outcome of Recurrent Well-Differentiated Thyroid Carcinoma. *Arch Otolaryngol Head Neck Surg*. 2004;**130**(7):819–824. doi: 10.1001/archotol.130.7.819.
8. Voralu K, Norsa'adah B, Naing NN, Biswal BM. Prognostic factors of differentiated thyroid cancer patients Hospital Universiti Sains Malaysia. *Singapore Med J*. 2006;**47**(8):688–692.
9. Ries LAG, Melbert D, Krapcho M, Sinchcomb DG, Howlader N, Mariotto A, et al. SEER Cancer Statistics Review, 1975–2005. Bethesda (USA): National Cancer Institute; 2007.
10. Khan N, Oriuchi N, Higuchi T, Zhang H, Endo K. PET in the follow-up of differentiated thyroid cancer. *Br J Radiol*. 2003;**76**(910):690–695.
11. Johnson NA, Tublin ME. Postoperative Surveillance of Differentiated Thyroid Carcinoma: Rationale, Techniques and Controversies. *Radiology*. 2008;**249**(2):429–444. doi: 10.1148/radiol.2492071313.
12. Chao M, Anren K, Jiawei X, Tiekun M. The possible explanations for patients with discordant findings of serum thyroglobulin and 131I whole-body scan. *J Nucl Med*. 2005;**46**(9):1473–1480.
13. Cabrera Martín MN, Pasamontes Pinggarron JA, Carreras Delgado JL, Lapeña Gutiérrez L, Delgado Bolton RC, Bittini Copano A, et al. Diagnostic accuracy of 18F-FDG PET in residual or recurrent differentiated thyroid carcinoma with high thyroglobulin and negative scan. *Rev Esp Med Nucl*. 2007;**26**(5):263–269.
14. Al-Zahrani AS, Abouzied ME, Salam Sa, Mohamed G, Rifai A, Al Sugair A, et al. The role of F-18-fluorodeoxyglucose positron emission tomography in the postoperative evaluation of differentiated thyroid cancer. *Eur J Endocrinol*. 2008;**158**(5):683–689. . doi: 10.1530/EJE-07-0903.
15. Dietlein M, Scheidhauer K, Voth E, Theissen P, Schicha H. Fluorine-18 fluorodeoxyglucose positron emission tomography and iodine-131 whole-body scintigraphy in the follow-up of differentiated thyroid cancer. *Eur J Nucl Med*. 1997;**24**(11):1342–1348.
16. Viedma SS, Borrego Doradol, Rodriguez RJR, Navarro Gonzalez E, Vazquez Albertino R, Hernandez Lopez R, et al. Use of 18FFDG-PET in patients with suspicion of recurrent differentiated thyroid cancer by elevated antithyroglobulin antibodies levels and negative 131I scan. *Rev Esp Med Nucl*. 2011;**30**(2):77–82. doi: 10.1016/j.remna.2010.10.012.
17. Yip. L, Carty SE. Differentiated Thyroid Cancers of Follicular Cell Origin. *Cancer Treat Res*. 2010;**153**:35–56. doi: 10.1007/978-1-4419-0857-5\_3.
18. Rizvi SN, Comans EF, Boellaard R, van Tinteren H, Hoekstra OS. Two decades at the cross-roads of biology, physics and epidemiology: Lessons learned in [18F-] FDG positron emission tomography in oncology. *Eur J Cancer*. 2010;**46**(12):2150–2158. doi: 10.1016/j.ejca.2010.05.018.