

## Original Article

# Low-dose Nicotine Exposure Induced the Oxidative Damage of Reproductive Organs and Altered the Sperm Characteristics of Adolescent Male Rats

Submitted: 4 Aug 2016

Accepted: 21 Sep 2017

Online: 29 Dec 2017

Siti Balkis BUDIN, Jia Hui KHO, Jia Hui LEE, Anand RAMALINGAM, FATIN FARHANA Jubaidi, ELDA SURHAIDA Latif, SATIRAH Zainalabidin, IZATUS SHIMA Taib, JAMALUDIN Mohamed

Programme of Biomedical Science, School of Diagnostic and Applied Health Science, Faculty of Health Science, Universiti Kebangsaan Malaysia, Jalan Raja Muda Abdul Aziz, 50300 Kuala Lumpur, Malaysia

To cite this article: Budin SB, Kho JH, Lee JH, Ramalingam A, Fatin Farhana J, Elda Surhaida L, Satirah Z, Izatus Shima T, Jamaludin M. Low-dose nicotine exposure induced the oxidative damage of reproductive organs and altered the sperm characteristics of adolescent male rats. *Malays J Med Sci.* 2017;**24(6)**:50–57. <https://doi.org/10.21315/mjms2017.24.6.6>

To link to this article: <https://doi.org/10.21315/mjms2017.24.6.6>

## Abstract

**Background:** Nicotine is a major toxic and hazardous component of cigarette smoke, and it has been widely used in nicotine replacement therapy (NRT). This study was aimed to investigate the effects of chronic low-dose nicotine on sperm characteristics and reproductive organ integrity in adolescent male Sprague–Dawley rats.

**Methods:** Twelve rats were equally divided into two groups. Group I received normal saline, and group II received 0.6 mg/kg body weight nicotine intraperitoneally for 28 consecutive days. At the end of the experimental period, sperm was collected for sperm characteristic evaluation, and the testes and prostate were isolated for biochemical and morphological analysis. The effects of nicotine on the body and reproductive organ weights of the animals were evaluated.

**Results:** Chronic nicotine treatment significantly ( $P < 0.05$ ) altered the sperm count, motility, viability, and morphology, and remarkably increased the malondialdehyde ( $P < 0.001$ ) and advanced oxidation protein product ( $P < 0.05$ ) levels in the testes and prostate of nicotine-treated group compared to control group. Moreover, nicotine caused a significant decrease ( $P < 0.05$ ) in the superoxide dismutase activity of the testes. No significant differences were observed in the reduced glutathione level in both of the testes and prostate of nicotine group compared with control group. Nicotine also induced histopathological alteration in the testes.

**Conclusion:** A low-dose nicotine exposure at 0.6 mg/kg caused detrimental effects on sperm characteristics and induced oxidative stress in the testes and prostate.

**Keywords:** infertility, prostate, testes, sperm, male, reproductive

## Introduction

Smoking has been frequently associated with male infertility (1, 2). It reduces sperm density in ardent smokers compared with non-smokers (3). The percentages of motile and normal sperms are also reported to be lower among male smokers because of the increased

generation of reactive oxygen species (ROS) (4). The effect of nicotine on the male reproductive system is a rising concern, as a previous study indicated that nicotine caused a decrease in the number of spermatocytes and spermatids (5).

The testes are sensitive to cigarette smoke, and long-term exposure to it alters the morphology of spermatogenic cells and sperm

production and suppresses spermatogenesis, thus directly leading to male infertility (6). Impaired spermatogenesis is also a result of the degeneration of spermatogenic and Sertoli cells due to nicotine (7). Male accessory sex organs, such as the prostate, are not spared from being a target of nicotine, which impairs the secretory process of this organ (8). Disruption in this secretory process affects semen and sperm qualities to the extent that DNA fragmentation occurs in sperm cells (9).

Nicotine has been widely used in various types of nicotine replacement therapy (NRT) (10). The dose of nicotine used in nicotine transdermal patch and nasal spray (TPN) is comparable with the estimated intake of nicotine by smoking 16 cigarettes (11). Therefore, the dose of nicotine in TPN is almost similar to the intake of nicotine by a light smoker (5).

Thus, the present study aimed to examine the effects of a chronic low dose of nicotine on the sperm characteristics, oxidative stress, and morphological changes in the testes and the prostate of adolescent male Sprague–Dawley rats.

## Materials and Methods

### Nicotine Preparation

Nicotine hydrogen tartrate (95% nicotine) was used in the study (Sigma, USA). It is partially soluble in water and freely soluble in saline.

### Animals and Treatment

Male Sprague–Dawley rats ( $n = 12$ ) weighing 200–250 g were obtained from Synertec Scientific, Malaysia. The rats were divided into two equal groups with *ad libitum* access to rat chow and drinking water. All animals were maintained in polypropylene cages at an ambient temperature of  $27 \pm 2$  °C with a 12 hours/12 hours light/dark condition. The experiment was conducted in accordance with the Guidelines of the Universiti Kebangsaan Malaysia on the care and use of laboratory animals (UKMAEC No.: FSK/BIOMED/2012/SATIRAH/12-DEC./486-DEC.-2012-DEC.-2014). The study design was experimental. Fourteen male rats were randomised into two groups. Group I received normal saline, and group II received 0.6 mg/kg body weight of nicotine by intraperitoneal injection for 28 consecutive days (12) to induce reproductive damage.

At the end of the study, all rats were anaesthetised with sodium thiopental and dissected. The weights of the prostate, seminal vesicle, cauda epididymis, and testes were recorded. Sperm was collected from the left and right cauda epididymis by immediately placing the cauda epididymis in 2 mL of Hank's Buffered Salt Solution enriched with 0.5 % bovine serum albumin (Sigma Chemicals, St. Louis, USA) and pre-warmed at 37 °C. Both cauda epididymis were minced and centrifuged at 1000 rpm at 4 °C for 3 minutes. The testes and the prostate were homogenised in 1.15% potassium chloride solution and centrifuged at 4 °C for 20 minutes. The homogenates were used for further biochemical analysis.

### Biochemical Assays

The levels of lipid malondialdehyde (MDA) were determined by the method of Stocks and Dormandy (13), advanced oxidation protein product (AOPP) by the method by Witko et al. (14), superoxide dismutase (SOD) activity by the method of Beyer and Fridovich (15), and reduced glutathione (GSH) levels by the method of Ellman (16).

### Sperm Characteristic Analysis

Sperm count was calculated by a Makler Counting Chamber. About 10  $\mu$ L of sperm suspension was taken and calculated for all grids under a 10x magnification of a light microscope. Sperm count was expressed as  $\times 10^6$  cells/mL. Sperm motility was evaluated by counting the motile and the non-motile sperms and assessed up to 200 sperms under a 10x magnification of a light microscope. Data are shown as the percentage of sperm motility. Sperm viability was determined by a routine gold standard method suggested by the World Health Organisation (17).

### Morphological Analysis of Male Reproductive Organs

The testes and the prostate were fixed with 10% formalin solution, dehydrated in graded ethanol, and embedded in paraffin wax. Both the testes and the prostate tissues were sectioned at 5  $\mu$ m and stained with hematoxylin and eosin. The slides were evaluated under light microscopy at 10x and 40x magnifications.

### Statistical Analysis

Statistical analysis was performed using the Statistical Package for Social Sciences version 19.0. The differences between the control group

and the treated group were statistically evaluated using independent *t*-test. All of the results were expressed as the mean (SD).

## Results

### Weight of the Body and Reproductive Organs

Table 1 indicates that treatment with nicotine did not cause any significant changes ( $P > 0.05$ ) in the weight of the body and reproductive organs, such as the prostate, seminal vesicle, caudal epididymis, and testes.

### Sperm Characteristics

Table 2 shows the significant decline of the sperm count, sperm motility, and sperm viability ( $P < 0.05$ ) in the nicotine-treated groups compared with the control group. A significant increase in the abnormal sperm morphology was found in the nicotine group ( $P < 0.001$ ).

### Antioxidant Status and Oxidative Damage Markers in the Reproductive Organs

Table 3 shows that treatment with nicotine caused a significant ( $P < 0.05$ ) decrease in the

SOD activity in the testes and an insignificant decrease in the prostate compared with that in the control group. The MDA levels and AOPP in the prostate ( $P < 0.05$ ) and the testes ( $P < 0.001$ ) were augmented in the nicotine-treated rats compared with the non-nicotine treated rats. No significant changes were observed in the GSH levels in the testes and the prostate.

### Histopathology of the Reproductive Organs

#### Testes

Figure 1A and Figure 1B illustrate the normal architecture of the seminiferous tubules and the spermatogenesis process. The seminiferous tubules contain abundant spermatogenic cells, which are surrounded by peritubular myoid cells, and the Leydig cells are located in the interstitial tissue between the seminiferous tubules (1B). Figure 1C and Figure 1D show that the spermatogenesis process is reduced in the lumen of the seminiferous tubules. Some of the seminiferous tubules exhibit a complete absence of spermatogenic cells, acinus, and fibromuscular stroma with normal secretory epithelium. The architecture of the seminiferous tubules is markedly shrunken

**Table 1.** Body and reproductive organ weight in normal and nicotine rats for 28 days of treatment

Organs (g)	Experimental groups		<i>t</i> -statistic (df = 12)	<i>P</i> -value <sup>b</sup>
	Control group <sup>a</sup> (n = 7)	Nicotine group <sup>a</sup> (n = 7)		
Final body weight	270.83 (37.80)	279.20 (19.71)	3.817	0.128
Prostate	0.57 (0.08)	0.49 (0.15)	1.418	0.682
Seminal vesicle	0.74 (0.23)	0.65 (0.15)	2.173	0.368
Cauda epididymis	0.48 (0.07)	0.46 (0.11)	1.307	0.754
Testes	2.58 (0.22)	2.67 (0.49)	1.037	0.996

<sup>a</sup>Mean (SD). <sup>b</sup>Independent *t*-test. *n*: Number of sample. *t*: *t*-statistics. df: Degree of freedom.

**Table 2.** Sperm characteristics in normal and nicotine rats for 28 days of treatment

Sperm characteristics	Experimental groups		<i>t</i> -statistic (df = 12)	<i>P</i> -value <sup>b</sup>
	Control group <sup>a</sup> (n = 7)	Nicotine group <sup>a</sup> (n = 7)		
Sperm count (X10 <sup>6</sup> /ml)	15.28 (0.52)	13.05 (0.35)	3.986	0.002
Sperm motility (%)	58.67 (2.37)	44.13 (1.27)	3.632	0.003
Sperm viability (%)	65.58 (3.14)	34.50 (1.95)	2.273	0.022
Abnormal sperm morphology (%)	3.17 (0.40)	8.92 (0.51)	3.093	<0.001

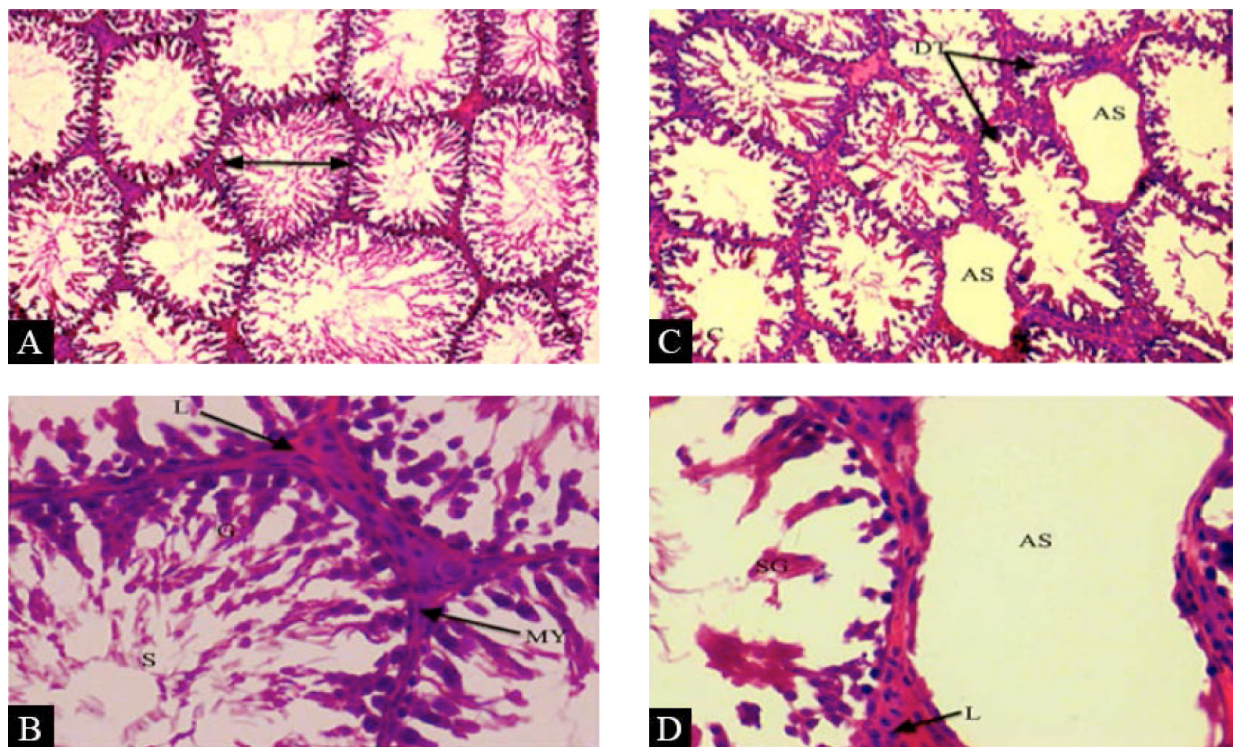
<sup>a</sup>Mean (SD). <sup>b</sup>Independent *t*-test. *n*: Number of sample. *t*: *t*-statistics. df: Degree of freedom.

**Table 3.** Oxidative stress markers in reproductive organs in normal and nicotine rats for 28 days of treatment.

	Testis			Prostate		
	Experimental groups		<i>P</i> -value <sup>b</sup>	Experimental groups		<i>P</i> -value <sup>b</sup>
	Control group ( <i>n</i> = 7)	Nicotine group ( <i>n</i> = 7)		Control group ( <i>n</i> = 7)	Nicotine group ( <i>n</i> = 7)	
SOD (U/min/mg protein)	2.16 (0.44)	1.44 (0.40)	0.017	15.71 (3.34)	18.69 (2.54)	0.054
GSH (nmol/mg protein)	106.52 (13.91)	111.52 (7.41)	0.074	0.16 (0.03)	0.15 (0.06)	0.231
MDA (nmol/g protein)	0.68 (0.11)	1.57 (0.18)	<0.001	2.39 (0.92)	4.22 (1.37)	0.013
AOPP (μmol/g protein)	48.23 (2.23)	57.04 (2.85)	<0.001	265.15 (38.19)	191.47 (21.52)	0.025

SOD: Superoxide dismutase. GSH = Glutathione. MDA = Malondialdehyde. AOPP = Advanced oxidation protein products.

<sup>a</sup>Mean (SD). <sup>b</sup>Independent *t*-test. *n*: Number of sample. *t*: *t*-statistics. df: Degree of freedom.



**Figure 1. Testes:** Histology of the testes of control and nicotine groups (H&E staining) (Magnification A and C ~ 10×; Magnification B and D ~ 40×). Figure 1A shows that normal architecture of the seminiferous tubules and spermatogenesis process. Figure 1B shows that the seminiferous tubules contain of abundant spermatogenic cells (G) and spermatozoa (S), which has surrounded by peritubular myoid cells (MY) and leydig cells (L) were located in the interstitial tissue between the seminiferous tubules. Figure 1C shows that architecture of seminiferous tubules were markedly shrunken and distorted (DT) and spermatozoa production was reduced in the lumen of seminiferous tubules (AS). Figure 1D shows that some of the seminiferous tubules show complete absence of spermatogenic cells and spermatozoa (AS).

and distorted. Some of the seminiferous tubules exhibit a complete absence of spermatogenic cells (Figure 1D).

### Prostate

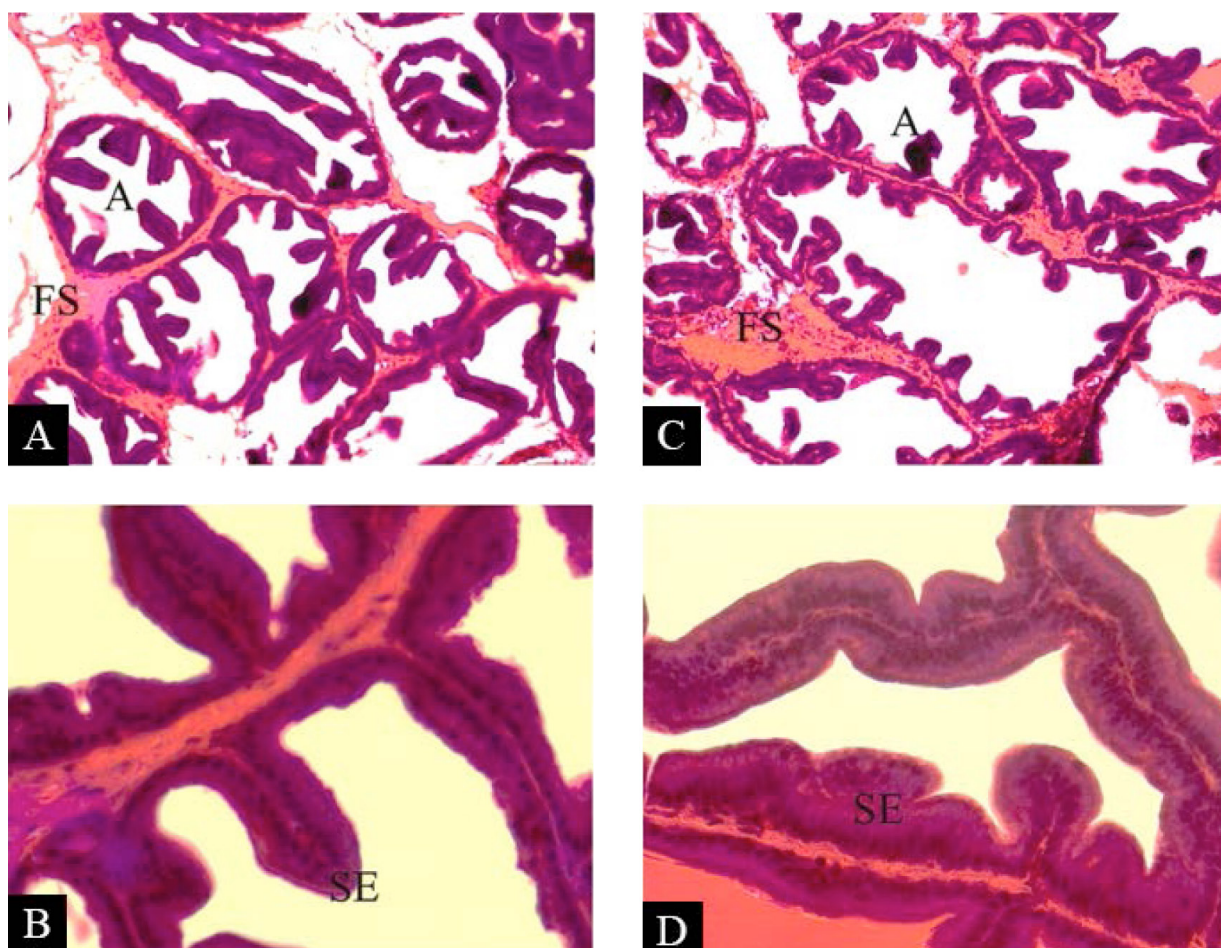
Figure 2A and Figure 2B illustrate the normal prostate gland, which consists of the acinus and fibromuscular stroma with normal secretory epithelium, from control group. The prostate exhibits no change in histology in the nicotine-treated group (Figure 2C and Figure 2D).

## Discussion

Researchers have reported the detrimental effect of cigarette smoking on male fertility (18,

19, 20). Nicotine exposure reduces the weight of the testis and the number of spermatocytes and spermatids. Nicotine also affects the testosterone level, pituitary gonadotropins, and testicular antioxidant status. Moreover, nicotine contributes to ROS generation in the testis (21).

SOD protects tissues against oxygen free radicals by catalysing the deletion of superoxide radical ( $O_2^{\cdot-}$ ), which harms the membrane and biological structures (22). GSH is an important inhibitor of free radical mediated lipid peroxidation. It is involved in several reactions in the body and is one of the most prominent non-enzymatic antioxidant (23). SOD and GSH are important in scavenging the enzyme that eliminates the toxic free radicals in vivo (24). Unlike in the control group, the SOD



**Figure 2.** Prostate: Histology of the prostate of control and nicotine groups (H&E staining) (Magnification A and C ~ 10×; Magnification B and D ~ 40×). Figure 2A and Figure 2B illustrated that normal prostate of the control group. Figure 2B shows that prostate gland consists of acinus (A) and fibromuscular stroma (FS), secretory epithelium (SE). Figure 2C and Figure 2D show that normal acinus, fibromuscular stroma and secretory epithelium from the nicotine treated group. No changes were found in the prostate of nicotine treated group.

enzyme activities significantly decreased in the nicotine-treated group of the testes. This result is consistent with that in a previous study indicating the decreased SOD level upon nicotine exposure in a dose-dependent manner (25). Our finding also shows no significant change in GSH in both groups. This result is interestingly consistent with that in a study reporting no significant changes in blood ROS and GSH levels in a 6 mg/kg body weight nicotine treatment despite a significant decrease in SOD and catalase levels (26).

In the present study, nicotine administration significantly altered the MDA and AOPP levels in the testes and the prostate, and this result indicates that the protein oxidation and lipid peroxidation processes in the testicular tissues were due to the generation of free radicals (27). The findings in this study demonstrate that a chronic low dose of nicotine induces oxidative stress through free radical-mediated lipid peroxidation and protein oxidation in the testes and the prostate.

The chronic administration of nicotine in male Sprague–Dawley rats in this study caused adverse effects on the sperm characteristics. Nicotine significantly decreased sperm count, sperm motility, and sperm viability while increasing the percentage of sperm with abnormal morphology. This study supports a previous study showing that the administration of nicotine lowered sperm motility and decreased live sperm and sperm with normal morphology in a 5 mg/kg body weight nicotine exposure (28).

The histopathological findings showed that chronic low-dose nicotine caused sloughed off and reduced spermatogenic cells and spermatozoa. Testicular damage occurred because of the increased generation of ROS by nicotine, which attacked the polyunsaturated fatty acids (PUFA) in the testes membrane, thus leading to the loss of testicular structure and function. Moreover, the reduction of spermatogenic cells and sperm could be due to the interference in the testosterone hormone by nicotine. Nicotine induced protein oxidation in the androgenic enzymes and disrupted the production of testosterone hormones (19). Therefore, the testicular structural damage and the disruption of the testes function may be due to nicotine-induced oxidative damage. These results agree with those of Mahanem et al. (29), in which the administration of nicotine at a 5 mg/kg body weight induced testicular damage.

Spermatozoa are susceptible to oxidative stress-induced damage because of the presence of large quantities of PUFA in their membrane, especially diPUFA (phospholipids esterified with two PUFAS), which is especially found in the retina and certain parts of the brain aside from the sperm (30). The abnormal morphology of the sperm structure can be linked to the lipid peroxidation damage to the PUFA component caused by free radicals (31). Abnormal sperm production may be due to the disruption of spermatogenesis by nicotine action (19).

The testes and the prostate are closely related to sperm quality and play an important role in male fertility. The oxidative damage and the morphological alterations of the testes are associated with the reduction in sperm quality (32). The prostate secretes fluids that make up the semen and provides nutrient to the sperm. Lipid peroxidation of the prostate may affect the secretion of semen and the sperm characteristics. According to Zhang et al. (3), when the semen volume decreases, sperm density and sperm viability also decrease. Therefore, any alteration in the structure and function of these reproductive organs can lead to male infertility by affecting the sperm quality.

## Conclusion

Chronic nicotine treatment at a dose of 0.6 mg/kg has detrimental effect on sperm characteristics and can cause oxidative damage to the testes and the prostate.

## Acknowledgements

The authors would like to thank the lecturers, researchers and staff of the Biomedical Science Program, School of Diagnostic and Applied Health Sciences, Faculty of Health Sciences, Universiti Kebangsaan Malaysia, and those who directly or indirectly supported this research.

## Authors' Contributions

Conception and design: SBB, SZ, ESL, JM

Analysis and interpretation of the data: KJH, LJH, AR, FFJ

Drafting of the article: FFJ, ESL

Critical revision of the article for important intellectual content: IST, ESL, JM

Final approval of the article: SBB

## Correspondence

Dr Siti Balkis Budin  
MD (UKM), MSc (Ulster University, UK), PhD (UKM)  
Programme of Biomedical Science,  
Faculty of Health Science, Universiti Kebangsaan  
Malaysia,  
Jalan Raja Muda Abdul Aziz,  
50300 Kuala Lumpur, Malaysia  
Tel: +603 9289 7645  
Fax: +603 2691 4304  
E-mail: balkis@ukm.edu.my

## References

- Miranda H. Smoking may harm sperm, male fertility: results seen in small study funded by cigarette company. American Society for Reproductive Medicine Annual Meeting, 2005 October 15–20; Montreal, Quebec, Canada; November 2005.
- Hornstein MD, Gibbons WE. Optimizing natural fertility in couples planning pregnancy—I and II. In: Rose DB, editor. *UpToDate*. Waltham, MA; 2009 (Electronic publishing).
- Zhang JP, Meng QY, Wang Q, Zhang LJ, Mao YL, Sun ZX. Effect of smoking on semen quality of infertile men in Shandong, China. *Asian J Androl*. 2000;**2**(2):143–146.
- Saleh, RA, Agarwal A, Sharma RK, Nelson DR and Thomas AJ. Effect of cigarette smoking on levels of seminal oxidative stress in infertile men: a prospective study. *Fertil Steril*. 2002;**78**(3):491–499. [https://doi.org/10.1016/S0015-0282\(02\)03294-6](https://doi.org/10.1016/S0015-0282(02)03294-6)
- Reddy S, Londonkar R, Reddy S, Patil SB. Testicular changes due to graded doses of nicotine in albino mice. *Indian J Physiol Pharmacol*. 1998;**42**(2):276–280.
- Güven MC, Can B, Ergün A, Saran Y, Aydos K. Ultrastructural effects of cigarette smoke on rat testis. *Eur Urol*. 1999;**36**(6):645–649. <https://doi.org/10.1159/000020061>
- Aydos K, Güven M, Can B, Ergun A. Nicotine toxicity to the ultrastructure of the testis in rats. *BJU Int*. 2001;**88**(6):622–626. <https://doi.org/10.1046/j.1464-4096.2001.02384.x>
- Favaro WJ, Carvalho CA. Morphometric and morphological features of the ventral prostate in rats submitted to chronic nicotine and alcohol treatment. *Tissue Cell*. 2006;**38**(5):311–323. <https://doi.org/10.1111/j.1439-0272.2006.00728.x>
- Lopes S, Sun JG, Jurisicova A, Meriano J, Casper RF. Sperm deoxyribonucleic acid fragmentation is increased in poor-quality semen samples and correlates with failed fertilization in intracytoplasmic sperm injection. *Fertil Steril*. 1998;**69**(3):528–532. [https://doi.org/10.1016/S0015-0282\(97\)00536-0](https://doi.org/10.1016/S0015-0282(97)00536-0)
- West R, Hajek P, Foulds J, Nilsson F, May S, Meadows A. A comparison of the abuse liability and dependence potential of nicotine patch, gum, spray and inhaler. *Psychopharmacology*. 2000;**149**(3):198–202. <https://doi.org/10.1007/s002130000382>
- Benowitz NL, Jacob P. Daily intake of nicotine during cigarette smoking. *Clin Pharmacol Therap*. 1984;**35**(4):499–504. <https://doi.org/10.1038/clpt.1984.67>
- Toklu H, Ozer S, Hulya S, Sule C, Berrak C, Yegen-Goksel S. Resveratrol supplementation protects against chronic nicotine-induced oxidative damage and organ dysfunction in the rat urogenital system. *Marmara Pharm J*. 2010;**14**(1). <https://doi.org/10.1038/clpt.1984.67>
- Stocks J, Dormandy T. The autoxidation of human red cell lipids induced by hydrogen peroxide. *Br J Haematol*. 1971;**20**(1):95–111. <https://doi.org/10.1111/j.1365-2141.1971.tb00790.x>
- Witko V, Nguyen AT, Descamps LB. Microtiter plate assay for phagocyte-derived Taurine-chloramines. *J Clin Lab Anal*. 1992;**6**(1):47–53. PMID: 1542083
- Beyer WF, Fridovich I. Assaying for superoxide dismutase activity: some large consequences of minor changes in conditions. *Anal Biochem*. 1987;**161**(2):559–566. [https://doi.org/10.1016/0003-2697\(87\)90489-1](https://doi.org/10.1016/0003-2697(87)90489-1)
- Ellman GL. Tissue sulfhydryl groups. *Arch Biochem Biophys*. 1959;**82**(1):70–77. [https://doi.org/10.1016/0003-9861\(59\)90090-6](https://doi.org/10.1016/0003-9861(59)90090-6)

17. WHO. *Laboratory manual for the examination of human semen and sperm-cervical mucus interactions*. 4th edition. Cambridge, United Kingdom: Cambridge University Press; 1999.
18. Borgerding M, Klus H. Analysis of complex mixtures—cigarette smoke. *Exp Toxicol Pathol*. 2005;**57**(1):43–73. <https://doi.org/10.1016/j.etp.2005.05.010>
19. Pacifici R, Altieri I, Gandini L, Lenzi A, Pichini S, Rosa M, et al. Nicotine, cotinine, and trans-3-hydroxycotinine levels in seminal plasma of smokers: effects on sperm parameters. *Ther Drug Monit*. 1993;**15**(5):358–363. <https://doi.org/10.1097/00007691-199310000-00002>
20. Jana K, Samanta PK, De DK. Nicotine diminishes testicular gametogenesis, steroidogenesis, and steroidogenic acute regulatory protein expression in adult albino rats: possible influence on pituitary gonadotropins and alteration of testicular antioxidant status. *Toxicol Sci*. 2010;**116**(2):647–659. <https://doi.org/10.1093/toxsci/kfq149>
21. Erat M, Ciftci M, Gumustekin K, Gul M. Effects of nicotine and vitamin E on glutathione reductase activity in some rat tissues *in vivo* and *in vitro*. *Eur J Pharmacol*. 2007;**554**(2–3):92–97. <https://doi.org/10.1016/j.ejphar.2006.10.008>
22. Arivazhagan P, Thilakavathy T, Panneerselvam C. Antioxidant lipoate and tissue antioxidants in aged rats. *J Nutri Biochem*. 2000;**11**(3):122–127. [https://doi.org/10.1016/S0955-2863\(99\)00079-0](https://doi.org/10.1016/S0955-2863(99)00079-0)
23. Griffith OW. Determination of glutathione and glutathione disulfide using glutathione reductase and 2-vinylpyridine. *Anal Biochem*. 1980;**106**(1):207–212. [https://doi.org/10.1016/0003-2697\(80\)90139-6](https://doi.org/10.1016/0003-2697(80)90139-6)
24. Gupta RK, Kesari AN, Diwakar S, Tyagi A, Tandon V, Chandra R, Watal G. *In vivo* evaluation of antioxidant and anti-lipidemic potential of *Annona squamosa* aqueous extract in Type 2 diabetic models. *J Ethnopharmacol*. 2008;**118**(1):21–25. <https://doi.org/10.1016/j.jep.2008.03.008>
25. Gottfredsen RH, Larsen UG, Enghild JJ, Petersen SV. Hydrogen peroxide induce modifications of human extracellular superoxide dismutase that results in enzyme inhibition. *Redox Biol*. 2013;**1**(1):24–31. <https://doi.org/10.1016/j.redox.2012.12.004>
26. Jain A, Flora S. Dose related effects of nicotine on oxidative injury in young, adult and old rats. *J Environ Biol*. 2012;**33**(2):233–238. (PMID: 23033686)
27. Baskol G, Korkmaz S, Erdem F, Caniklioglu A, Kocyigit M, Aksu M. Assessment of nitric oxide, advanced oxidation protein products, malondialdehyde, and thiol levels in patients with restless legs syndrome. *Sleep Med*. 2012;**13**(4):414–418. <https://doi.org/10.1016/j.sleep.2011.11.012>
28. Fairuz A, Hashida N, Mahanem M. Effect of nicotine and goat milk co-administration on rat testis and sperm parameters. *Austral J Basic Appl Sci* 2011;**5**(12):2738–2741.
29. Mahanem M, Nor-Asmaniza A, Phang H. Effects of nicotine and co-administration of nicotine and vitamin E on testis and sperm quality of adult rats. *Malaysian Appl Biol*. 2006;**35**(2):47–52.
30. Sharma RK, Agarwal A. Role of reactive oxygen species in male infertility. *Urol*. 1996;**48**(6):835–850. [https://doi.org/10.1016/S0090-4295\(96\)00313-5](https://doi.org/10.1016/S0090-4295(96)00313-5)
31. Agarwal A, Said TM. Role of sperm chromatin abnormalities and DNA damage in male infertility. *Human Repro Update*. 2003;**9**(4):331–345. <https://doi.org/10.1093/humupd/dmg027>
32. Taib IS, Budin SB, Ghazali AR, Jayusman PA, Louis SR, Mohamed J. Fenitrothion induced oxidative stress and morphological alterations of sperm and testes in male sprague-dawley rats. *Clinics* 2013;**68**(1):93–100. [https://doi.org/10.606/clinics/2013\(01\)OA15](https://doi.org/10.606/clinics/2013(01)OA15)