

# A case of late recurrence of Burkitt's Lymphoma presenting with abdominal masses and haematemesis

Chin-Nam Bong<sup>1</sup>, Solomon C.C Chen<sup>2</sup>, Alexander David Barr<sup>1</sup>, Kwongleung Yu<sup>1</sup>, Tsung-Che Hsieh<sup>1</sup>, Teck-Siong Tok<sup>2</sup>, John A. Phillips<sup>3</sup>

1. Mzuzu Central Hospital, Taiwan Medical Mission to Malawi
2. Department of Paediatrics, Pingtung Christian Hospital, Taiwan
3. Burkitt's Lymphoma Programme, Kamuzu Central Hospital, Malawi

Correspondence: Dr. Chin-Nam Bong, Department of Paediatrics, Mzuzu Central Hospital, Malawi.  
Tel: 265-(0)9313221, Fax: 265-(0)1333152, E-mail: paed\_mch@yahoo.com

## Clinical course

In August, 2005, a 10 year old boy was admitted to a district hospital with marked haematemesis and a huge abdominal mass. Initially, he was treated for ruptured oesophageal varices, but in vain. Then he was transferred to Mzuzu Central Hospital. The history revealed a previous clinical diagnosis of Burkitt's lymphoma (BL) in 2002, without pathological confirmation, when he had bilateral jaw masses and an epigastric mass. He had received four doses of cyclophosphamide (CPM) chemotherapy, 40mg/kg/dose fortnightly and responded partially with shrinkage of abdominal mass. One dose of intravenous combined chemotherapy of CPM, vincristine (1.5mg/sq.m/dose) and methotrexate (20mg/sq.m/dose) (COM) was then administered before he was lost to follow up. Examination showed pale conjunctivae and a palpable rounded epigastric mass, with low grade fever. Abdominal ultrasound demonstrated a mass 4.2 × 5.0 cm behind the stomach and just above the pancreatic tail. Emergency endoscopy revealed active bleeding from the posterior wall of the upper stomach, without evidence of oesophageal varices. A thick blood film was positive for Plasmodium falciparum with ++s. Abnormally high lactate dehydrogenase (LDH) of 1036 U/L (reference value: 120-330 U/L) was also noted. His haemoglobin decreased from 9.6 to 4.6 g/dl. Several blood transfusions, intravenous cimetidine, vitamin K, tranexamic acid and quinine were given and his condition stabilized gradually. Follow up endoscopy a week later showed a healing ulcer with convergent folds on the posterior wall of the stomach. Presuming recurrent BL, we gave him intravenous CPM, 40 mg/kg/dose at 14 day intervals, but abdominal ultrasound after four doses showed no tumour regression. Since the tumour was not accessible to fine needle aspiration (FNA), an exploratory laparotomy was done in September 2005 and two tumours were found. One, of 10 cm greatest diameter, occupied the lesser sac and the other of 7 cm was located retroperitoneally on the left, below the transverse mesocolon. The margin of the stomach was smooth without any infiltration by the tumour. The retroperitoneal tumor was partially resected and submitted for pathological examination. Because of the poor response to initial treatment, we changed to six doses of COM and two doses of CNS prophylaxis with intrathecal hydrocortisone (25mg/dose) and methotrexate (12.5mg/dose). Follow up abdominal ultrasound after six courses of COM chemotherapy showed the abdominal tumor had shrunk in size but not resolved completely. He responded well and was symptom free though some residual tumour

remained on ultrasound, and was discharged. His weight increased from 20 to 24kg and LDH levels became normal at 310 U/L. Currently, he is being followed up regularly at our outpatient clinic.

## Histological study

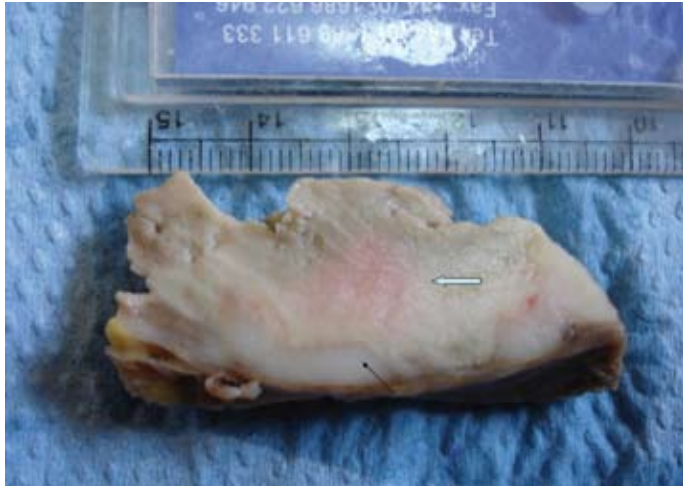Macroscopic examination showed a piece of tissue 6 x 4 x 3 cm which had a partly circumscribed peripheral edge. There was a thin peripheral rim of firm white viable tumor tissue and a large central area of soft homogeneous grey necrosis (fig.1). Microscopically on Haematoxylin-Eosin staining, the tumor consisted of monotonous sheets of lymphoid cells with high nuclear to cytoplasmic ratio, granular chromatin, two or more small nucleoli and apoptotic cells (fig.2). Morphological features were consistent with BL. Unfortunately, confirmatory immunohistochemistry and polymerase chain reaction examinations were unavailable in Malawi.

## Discussion

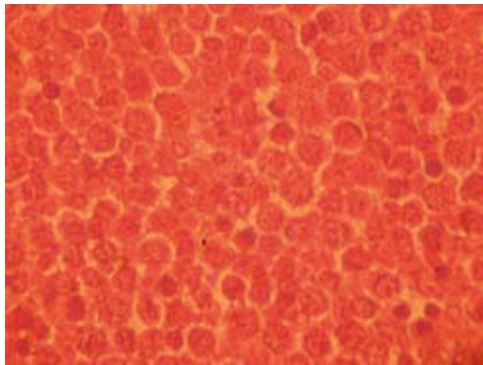
BL is an aggressively proliferating malignancy of B lymphocyte origin. Plasmodium falciparum malaria and Epstein-Barr virus infection early in life have been recognized as two risk factors of endemic BL.<sup>1</sup> Malawi is a malaria endemic country and BL accounts for 50% of childhood cancer.<sup>2</sup> Due to limited medical resources, only two treatment regimens are used for children with BL in the central and northern regions of Malawi. One is six intravenous fortnightly doses of CPM (40mg/kg/dose), the other a similar number of doses of combined COM (CPM:40mg/kg/dose; Vincristine:1.5mg/sq.m./dose; Methotrexate:20mg/sq.m./dose) for those resistant to CPM monotherapy.<sup>3</sup> Intrathecal hydrocortisone (25mg/dose) and methotrexate (12.5mg/dose) are given twice during chemotherapy for patients without CNS involvement. Preferably the same dosage of intrathecal drugs would be given with every intravenous therapy. In Blantyre a protocol using weekly CPM (40mg/kg orally) x 3 followed by 3 fortnightly would be given to such a child. Intrathecal methotrexate and steroids would accompany the first 3 courses of treatment. Most relapses of BL occur within the first year after treatment.<sup>4</sup> FNA biopsy is less invasive, quicker and preferable way of confirming the diagnosis if it is possible. This case had an unusual recurrence of BL three years after his first treatment in 2002. It may have been a new tumour or a relapse of the original one. Exploratory laparotomy was preferred to FNA because of the difficulty in approaching the tumour. Identification of the immunoglobulin gene rearrangement patterns would have helped identify whether this was the original tumour or not. Unfortunately, no cytology or biopsy was done in 2002, so pathological comparison was not possible.

His presenting problem of severe haematemesis due to gastric ulcer bleeding was proved at endoscopy, though laparotomy showed no direct involvement of the stomach

*Figure 1: Macroscopic appearance of the tumour biopsy. A thin peripheral rim of viable white tumor (closed arrow) with extensive central homogeneous grey necrosis (open arrow).*



*Figure 2: Microscopic findings ( $\times 800$ ). Sheets of monotonous lymphoid cells with granular chromatin and multiple nucleoli. There are a few scattered apoptotic cells.*



by the tumour. His mother denied any traditional medicine or treatment before his admission to the hospital. The neurology examination was normal and intracranial pressure was not high at lumbar puncture. The gastric bleeding may have been due to the *Plasmodium falciparum* infection shown by the thick blood film, or *Helicobacter pylori* infection, though this is unusual in a 10 year old boy. Malaria parasitaemia may initiate the coagulation cascade with the formation and deposition of fibrin in blood vessels, resulting in changes of the gastric mucosa with superficial bleeding, particularly when the agent is *Plasmodium falciparum*.<sup>5</sup>

Follow up abdominal ultrasound after ten courses of chemotherapy showed that the tumour had shrunk but not resolved completely. However, the LDH level, which highly correlates with tumour load<sup>1</sup>, had returned to normal limits. This was compatible with the biopsy findings of extensive central necrosis of the tumour. In conclusion, this is an unusual presentation of late recurrent BL three years after partial treatment. Fortunately, the recurrent BL still showed a good partial response to combined chemotherapy.

## References

1. van den Bosch CA. Is endemic Burkitt's lymphoma an alliance between three infections and a tumour promoter? *Lancet Oncol* 2004; 5:738-46.
2. Hesselting PB, Broadhead R, Molyneux E, et al. Malawi pilot study of Burkitt lymphoma treatment. *Med Pediatr Oncol* 2003;41:532-40.
3. Kazembe P, Hesselting PB, Griffin BE, Lampert I, Wessels G. Long term survival of children with Burkitt lymphoma in Malawi after cyclophosphamide monotherapy. *Med Pediatr Oncol* 2003;40:23-5.
4. Hesselting P, Broadhead R, Mansvelt E, et al. The 2000 Burkitt lymphoma trial in Malawi. *Pediatr Blood Cancer* 2005;44:245-50.
5. Romero A, Matos C, Gonzalez MM, Nunez N, Bermudez L, de Castro G. Changes in gastric mucosa in acute malaria. *GEN* 1993;47:123-8.