

'Teaching corner': Management of Diabetic Retinopathy

D Ellis¹, P I. Burgess², P Kayange³

1. Sheffield Medical School, UK

2. Malawi-Liverpool-Wellcome Trust Clinical Research Programme
Queen Elizabeth Central Hospital

3. Ophthalmology unit, Department of Surgery, College of Medicine,
University of Malawi, Queen Elizabeth Central Hospital, Blantyre, Malawi

Abstract

Sub-Saharan Africa faces an epidemic of diabetes. Visual loss from diabetic retinopathy (DR) is both preventable and treatable. This article reviews the epidemiology and clinical features of DR and current evidence-based interventions in three areas: primary prevention of retinopathy by optimum medical management, early detection of pre-symptomatic disease and management of established retinopathy to prevent or mitigate visual loss. There are significant challenges to DR care in resource poor environments. Appropriate provision of effective interventions by health services can reduce social and economic costs associated with patient care.

Introduction

International Diabetes Federation has estimated that the number of adults with diabetes in Africa will expand by 98%, from 12.1 million in 2010 to 23.9 million in 2030¹. Diabetes causes visual impairment through early-onset cataract and diabetic retinopathy (DR), a progressive disease of the retinal microvasculature. Cataract and DR are the second and sixth leading causes of global visual impairment, respectively². Both are included in the list of nine target diseases of Vision 2020, a joint programme of WHO and the International Agency for the Prevention of Blindness.

The 2009 WHO Malawi national STEPwise approach to surveillance (STEPS) survey estimated a prevalence of diabetes of 5.6% in adults aged 25 to 64 years. 90% of these have type II diabetes³. Without intervention visual impairment as a result of diabetes will increasingly impose social and economic burdens on communities in Malawi. Visual loss from diabetic retinopathy is both preventable and treatable. Medical management of diabetes, early detection of retinopathy and timely treatment all diminish the risk of visual loss.

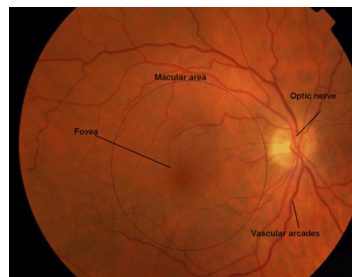
Who is at risk of diabetic retinopathy?

Large cohort studies in Europe⁴ and the US^{5, 6} have demonstrated that the greatest risk factor for development of DR is duration of diabetes. The Wisconsin Epidemiologic Study of Diabetic Retinopathy (WESDR) showed an increase in the prevalence of DR from 17% in those having had diabetes for less than 5 years to 97.5% in those 15 years and over. Proliferative retinopathy affected 1.2% in those having diabetes for less than 10 years, against 67% in those having it for 35 years or more⁶. Two key studies, the Diabetes Control and Complications Trial (DCCT) (type I diabetes study)⁷ and the United Kingdom Prospective Diabetes Study (UKPDS) (type II diabetes study)^{8,9,10} demonstrated additional risk factors for the development and progression of DR: glycaemic control (measured by HbA1c level) and hypertension. The more recent Action to Control Cardiovascular Risk in Diabetes (ACCORD)¹¹ and Fenofibrate Intervention and Event Lowering in Diabetes (FIELD)¹² studies have highlighted the role of blood lipid levels. The effect of variables which are important in the Southern African context such as HIV and a high burden of infection with malaria are, at present, unknown.

What retinal changes occur?

The retina is supplied by two circulatory systems: the uveal (choroidal) circulation and the retinal vasculature (Figure 1). Diabetes damages retinal capillaries through prolonged exposure to hyperglycaemia. This leads to loss of supporting pericyte cells and tight junctions between endothelial cells. Leakage from capillaries results in retinal oedema and capillary closure leads to ischaemia.

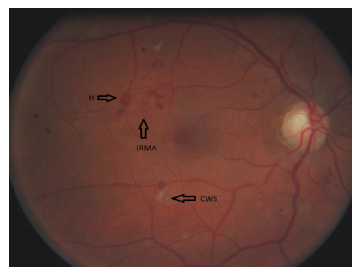Figure 1. Normal retinal anatomy. The retinal vasculature radiates from the optic disc. The macula is bordered by the vascular arcades. Light is focused on the fovea which is responsible for sharp, central, colour vision.



Non-proliferative diabetic retinopathy

DR can be classified either non-proliferative (NPDR) or proliferative (PDR). Non-proliferative DR is characterised by microaneurysms, intraretinal haemorrhages, venous beading and intraretinal microvascular abnormalities (IRMA). (Figure 2). NPDR is usually asymptomatic but may progress to PDR.

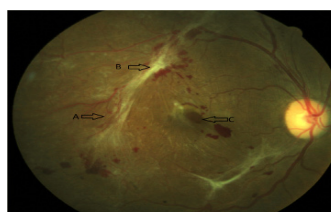
Figure 2. Non-proliferative diabetic retinopathy. Colour fundus photograph showing haemorrhages (H), Cotton wool spots (CWS) and intraretinal microvascular abnormalities (IRMA).



Proliferative diabetic retinopathy

Ischaemic retina produces growth factors including vascular endothelial growth factor (VEGF). The growth of abnormal new vessels is stimulated from the optic disc or retina. New vessels are prone to bleeding (vitreous haemorrhage) and the accompanying fibrosis leads to tractional retinal detachment; both sight-threatening manifestations of PDR. (Figure 3.)

Figure 3. Proliferative diabetic retinopathy. Colour fundus photograph showing (A) new vessels, (B) fibrovascular tissue and (C) a central retinal hole secondary to traction from fibrovascular tissue.



Diabetic Maculopathy

Retina which is oedematous or ischaemic loses function and this will reduce vision if the central retina or macula is involved. Diabetic maculopathy can be divided into two types: macular oedema and macular ischaemia which may co-exist. Macular oedema occurs due to breakdown of the inner blood-retina barrier. Fluid which accumulates within the retina distorts its architecture. Deposition of serum lipids, usually around the edges of areas of microvascular leakage, are seen as 'exudates' (Figure 4). Exudates act as surrogate markers of retinal thickening and oedema which can only be seen when the retina is viewed stereoscopically. Oedema is assessed clinically and using imaging technology (Figures 5 and 6). Ischaemic maculopathy occurs due to capillary loss within the macula, is diagnosed by fluorescein angiography and is, at present, untreatable.

Figure 4. Colour fundus photograph showing extensive exudates, some of which are grouped in 'circinates' surrounding clusters of microaneurysms (labelled 'C' in image).

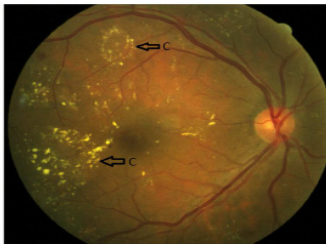


Figure 5. Imaging of diabetic macular oedema. Mid (a) and late (b) phase fluorescein angiogram images showing leaking microaneurysms and pooling of dye in intraretinal spaces.

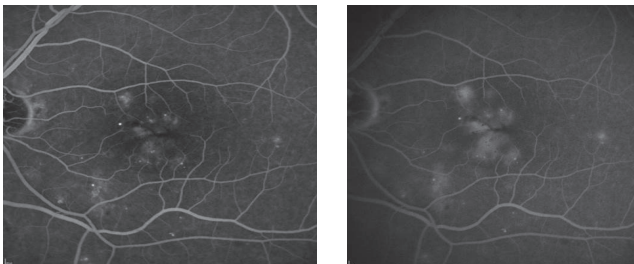
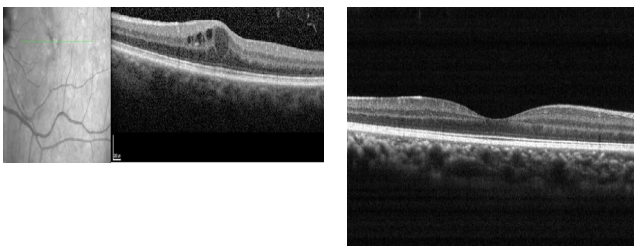


Figure 6. (a) Red free image (left) showing location of scan on optical coherence tomography (OCT). OCT (right) shows intraretinal fluid cysts with thickening of the retina and a detached hyaloid face.



(b) Normal OCT image of the central macula for comparison

How can diabetic retinopathy be assessed?

DR remains asymptomatic until vision is affected but by this time the condition may be irreversible. Treatment is most likely to be effective when performed before progression to advanced disease. Slit-lamp examination by a trained ophthalmologist and retinal photography with grading of retinopathy by accredited graders can be considered the reference standards for disease detection. Examination with the direct ophthalmoscope is less sensitive and specific for DR¹³.

Fluorescein angiography can also be used clinically to examine the circulation of the retina and choroid. This method involves injecting a fluorescent dye and photographing the posterior section of the eye using a specialised camera to obtain an angiogram. Hyperfluorescence angiograms are usually caused by leaking capillaries and abnormal vasculatures, including neovascularisation, with blocked capillaries being the main cause of hypofluorescence.

How is diabetic retinopathy managed?

Risk of visual loss from DR is reduced by interventions which fall into 3 categories: primary prevention of microvascular complications, early detection of retinopathy and effective treatment of established disease.

Primary prevention

Glycaemic control

Risk of microvascular complications of diabetes are reduced by optimum glycaemic control. After mean duration of follow-up 6.5 years the DCCT achieved a reduction in mean HbA1c from 9.1% to 7.3% with reduction in progression of retinopathy of 76%¹⁴. After a mean duration of follow-up of 10 years in the UKPDS reduction of HbA1c 7.9% to 7.0% was associated with a 25% risk reduction of microvascular complications⁸. Both DCCT and UKPDS demonstrated legacy effects. In the DCCT after ten years follow-up where the glycosylated haemoglobin levels had converged completely, the former intensive treatment group still had 24% reduction in progression of retinopathy and 59% reduction in proliferative retinopathy¹⁵. However, very tight glycaemic control was associated with increased mortality in the ACCORD study [11]. Current guidelines suggest target HbA1c between 6.5 – 7.0 %¹⁶, however a target HbA1c of < 7.0% for type I diabetics and < 7.5% for type II diabetics is more suitable. This is because lower blood glucose targets are associated with increased mortality due to some patients' inability to tolerate hypoglycaemia as well as there being limited access to treatment for hypoglycaemic, diabetic patients in Malawi. Control of hypertension

Blood pressure control plays an important role in prevention and management of diabetic retinopathy. The UKPDS compared the control of hypertension in type II diabetic patients. A 'tightly controlled' group were treated with either a beta blocker or ACE inhibitor aiming for a BP below 150/85 mmHg. A less tight BP control group aimed for a BP below 180/105 mmHg. Following 7 years the tight control group showed a 34% reduction in the rate of progression in DR, a 47% reduction in visual loss and had 35% less need of laser photocoagulation compared to the less tight group¹⁰. Specific therapies blocking the renin-angiotensin system may have additional benefits, particularly for mild retinopathy, but should be discontinued during pregnancy¹⁶.

Lipid lowering agents

Observational data from the Early Treatment of Diabetic Retinopathy Study (ETDRS) suggest that elevated total serum cholesterol levels are associated with an increased risk of visual loss in patients with diabetic retinopathy¹⁷. The possibility of an effect of statins was investigated in the Collaborative Atorvastatin Diabetes Study (CARDS) [18]. Results were encouraging but the effect appears to be small. The FIELD study assessed the effects of long term lipid-lowering therapy with fenofibrate on reducing the progression of DR and the need for laser treatment. It

found that fewer patients receiving fenofibrate required laser treatment (3.4%) than those in the control group (4.9%). Interestingly benefits were not related to changes in lipid levels so the mechanism of drug action remains unclear.

The ACCORD randomised trial, investigated whether intensive glycaemic control, combination therapy for dyslipidaemia and intensive blood-pressure control, would limit DR progression in type II diabetes. The rate of DR at 4 years being 6.5% for the fenofibrate group and 10.2% for the placebo. Moderate vision loss was seen in 23.7% and 24.5% of participants in the fenofibrate and placebo groups respectively [11]. Currently, the recommended serum lipid levels for diabetic patients are: an optimal LDL cholesterol concentration of <100 mg/dl, optimal HDL cholesterol level of >45 mg/dl and desirable triglycerides levels of <150 mg/dl¹⁹.

Other medical interventions

Glitazones are effective at lowering glycosylated haemoglobin but their use is limited due to adverse effects. These agents were associated in a large case series with 2.6 fold in macular oedema²⁰. Current advice is to withdraw pioglitazone when macula oedema has developed¹⁶. The effects of protein kinase C activation and its inhibition on treating DR and diabetic macular oedema are currently being investigated. Two studies, using the protein kinase C β -inhibitor, Ruboxistaurin, have compared visual loss in diabetic macular oedema and DR with moderately encouraging results^{21,22}. Although smoking contributes to other complications of diabetes no clear association of smoking and retinopathy has been demonstrated. Counselling and treatment for smoking is cost effective in diabetes management²³ and a lack of benefit for DR should not alter advice to patients to stop smoking.

Screening for diabetic retinopathy

Diabetic retinopathy meets the WHO criteria for a screening programme: an important public health issue; a recognised pre-symptomatic stage; an acceptable screening procedure and an effective treatment. At present persons with diabetes are advised to attend for retinal examination every 12 months¹⁶. Systematic screening is shown to be cost-effective for sight years preserved compared with no screening in developed countries²⁴. Variation in age of onset of diabetes, glycaemic control, sensitivity of the screening test and compliance rates influence the cost-effectiveness of screening programmes. Optimum screening intervals have yet to be defined and research on targeted screening based on disease risk factors is on-going.

Currently there is no systematic screening programme for DR in Malawi. There have been scattered reports of successful attempts to screen patients attending diabetes clinics for DR in Africa^{25,26} including the 'LEOPARD' programme in Ethiopia (Paul Dodson personal communication). Mumba et al²⁶ in Tanzania attempted to develop a register of known patients with diabetes. Defining an eligible population is an essential component of a screening programme but is a challenge in resource poor settings. Digital photography with telemedicine links, as used by the English national screening programme²⁷, has the potential to deliver cost effective, accessible screening to rural and remote populations. Unfortunately fundus cameras remain prohibitively expensive. Development of lower cost solutions could radically alter the landscape for DR care in Africa; research

into appropriate technologies is needed. Automated fundus photograph analysis is an exciting innovation which has the potential to reduce the cost of screening programmes.

Treatments for sight threatening retinopathy

Despite the fact that the majority of patients with retinopathy do not require treatment, regular eye checks are required to assess whether or not intervention is required to prevent sight deterioration. The development of sight threatening maculopathy, severe non-proliferative retinopathy or proliferative retinopathy necessitates referral to an ophthalmologist.

Laser photocoagulation

The effectiveness of laser photocoagulation at reducing the likelihood of visual impairment and blindness in patients with proliferative diabetic retinopathy (PDR) and macular edema is well established. Laser for PDR involves ablation of peripheral retina with 1 to 5 thousand spaced burns to reduce the amount of ischaemic retina and VEGF it produces. The Diabetic Retinopathy Study was a multi-centre randomised trial evaluating the use of scatter photocoagulation in reducing visual loss in PDR. PRP reduced visual loss by 50% compared to no treatment²⁸. Laser for diabetic macular oedema involves treatment directly to leaking microaneurysms, and gentle laser (up to 300 burns) to the macula, thought to stimulate cellular fluid pumps. Laser cannot treat vision lost due to ischemic maculopathy. The ETDRS compared laser photocoagulation with observation for diabetic macular oedema. After a 3 year period, there was a reduction from 24% to 12% in moderate visual loss for the laser group. Following treatment, visual acuity improved in only 3% of those treated²⁹.

In Malawi laser treatment is now available in the public sector at Lions Sight First Eye Units at both Kamuzu Central Hospital, Lilongwe and Queen Elizabeth Central Hospital, Blantyre. In Blantyre dedicated referral clinics can be accessed by doctors and ophthalmic clinical officers. Annual training for ophthalmic clinical officers in recognition and referral of DR is run in conjunction with the QECH Department of Medicine.

Intravitreal steroids

Laser photocoagulation is insufficient alone to prevent visual loss in all cases of diabetic macular oedema. Intravitreal triamcinolone acetonide (IVTA) has been investigated as a monotherapy and as an adjunct to laser. There is good evidence that IVTA monotherapy is inferior to laser treatment at 3 year follow-up³⁰. The Diabetic Retinopathy Clinical Research Network (DRCR.net) demonstrated that IVTA combined with laser is inferior to ranibizumab with immediate or deferred laser, except in patients who are pseudophakic³¹. Flucinolone slow release intravitreal implant is effective in macular oedema³². Intravitreal steroid preparations are associated with a high incidence of raised intra-ocular pressure and cataract.

Intravitreal anti-VEGF agents

Levels of vascular endothelial growth factor (VEGF) are elevated in the vitreous and retina in patients with DR and diabetic macular oedema³³. Recent evidence demonstrates better short-term outcomes than laser alone for intra-vitreous monoclonal antibody therapies targeting the VEGF molecule in diabetic maculopathy which has already reduced vision. The 2010 landmark DRCR.net study³⁴ compared intravitreal

ranibizumab with prompt macular laser photocoagulation, ranibizumab with deferred laser photocoagulation, IVTA with prompt laser, or a sham injection with prompt laser. At 2 years, intravitreal ranibizumab combined with either prompt or deferred laser, showed superior improvements in best corrected visual acuity compared with laser treatment alone. There was a gain of at least 15 ETDRS letters in around 30% of patients in each of the ranibizumab arms, 15% for the laser monotherapy group, and 21% for the triamcinolone group.

Anti-VEGF agents, which require multiple repeat injections, will be increasingly used in resource-rich countries although with a continued role for laser. At present these agents are prohibitively expensive for widespread use in resource-poor countries (approximately US\$800 per injection for the drug alone). However off-label use of the systemic anti-VEGF, bevacizumab (US\$~70 per injection), is used in some African tertiary centres on a paying patient basis, an approach supported by the 'BOLT' study³⁵.

Surgical management of diabetic retinopathy

Vitreoretinal surgery has an important role in managing advanced disease to mitigate visual loss. The objectives of surgical removal of the vitreous (vitrectomy) include removal of vitreous opacity (commonly blood) and/or fibrovascular proliferation, relieving retinal traction, achieving retinal reattachment, and allowing completion of scatter laser photocoagulation. A large case series showed that sight threatening complications are rare and in approximately 90% of cases, vision is improved or stabilised³⁶. Vitrectomy may also be beneficial in maculopathy in cases where traction from the vitreous contributes to fluid accumulation. Currently vitreoretinal surgery is not available in Malawi.

What are the specific challenges for Malawi?

The best evidence currently available suggests that, of patients attending diabetes clinics in Malawi, approximately 20% have sight threatening diabetic retinopathy (STDR) and 5% proliferative diabetic retinopathy³⁷ (approximately 3 times and 5 times levels reported in recent European and American studies, respectively). The burden of diabetes and its complications is borne predominantly by the working age population³⁸. A disease which reduces the economic activity of this group affects individual, household and national economies. Diabetes care must compete in the political spectrum with other financial and health care initiatives. It does not lend itself to vertical programmes favoured by donors. However political attention is turning to non communicable disease (NCD) as witnessed by the UN high level meeting on NCD prevention and control, Sept 2011³⁹. The challenges for effective management of diabetes in sub-Saharan Africa have been recently reviewed by our group⁴⁰. Policy makers require evidence based guidance on resource allocation.

Conclusion

Visual loss from diabetic retinopathy is both preventable and treatable. Effective and consistent medical management reduces incidence and progression of retinopathy. Detection of early, pre-symptomatic disease allows timely treatment with laser photocoagulation to prevent visual loss. If vision is lost, treatment with vitreoretinal surgery or agents injected intra-ocularly may stabilise or improve vision. There are significant challenges to DR care in resource poor environments. However, the improved provision

of effective, evidence-based interventions by health professionals involved with diabetes care can reduce the social and economic impact on patients.

References

1. IDF (2009). Diabetes atlas (4th edn). International Diabetes Federation, Brussels.
2. Pascolini D, Mariotti SP. Global estimates of visual impairment: 2010. *BJO* 2012; 96(5) :614-8.
3. Malawi National STEPS Survey for Chronic Non-Communicable Diseases and their Risk Factors. World Health Organisation, 2010. http://www.who.int/chp/steps/Malawi_2009_STEPS_Report.pdf (accessed 4th August 2013)
4. Younis N, Broadbent D, Vora J and Harding S. Incidence of sight-threatening retinopathy in patients with type 2 diabetes in the Liverpool Diabetic Eye Study: a cohort study. *Lancet* 2003; 361: 195-200.
5. Klein R, Klein BEK, Moss SE, Davis MD, DeMets DL. The Wisconsin Epidemiologic Study of Diabetic Retinopathy. III. Prevalence and risk of diabetic retinopathy when age at diagnosis is 30 or more years. *Arch Ophthalmol* 1984; 102: 527-532.
6. Klein R et al. The Wisconsin Epidemiological Study of Diabetic Retinopathy: II. Prevalence and Risk of Diabetic Retinopathy when Age at Diagnosis is Less than 30 Years. *Archives of Ophthalmology* 1984; 102 (4): 520-526.
7. The Diabetes Control and Complications Trial Research Group: The effect of intensive treatment of diabetes on the development and progression of long-term complications in insulin-dependent diabetes mellitus. *N Engl J Med* 1993, 329: 977-986
8. UK Prospective Diabetes Study (UKPDS) Group. Intensive blood-glucose control with sulphonylureas or insulin compared with conventional treatment and risk of complications in patients with type 2 diabetes (UKPDS 33). *Lancet* 1998; 352: 837-853.
9. Stratton IM, Kohner EM, Aldington SJ, Turner RC, Holman RR, Manley SE, Matthews DR: UKPDS 50: risk factors for incidence and progression of retinopathy in Type II diabetes over 6 years from diagnosis. *Diabetologia* 2001, 44:156-163.
10. UK Prospective Diabetes Study Group: Tight blood pressure control and risk of macrovascular and microvascular complications in type 2 diabetes: UKPDS 38. *BMJ* 1998, 317:703-713.
11. The ACCORD Study Group and ACCORD Eye Study Group. Effects of Medical Therapies on Retinopathy Progression in Type 2 Diabetes. *N Engl J Med* 2010;363:233-44.
12. Keech A, Simes RJ, Barter P, Best J, Scott R, Taskinen MR, Forder P, Pillai A, Davis T, Glasziou P, et al: Effects of long-term fenofibrate therapy on cardiovascular events in 9795 people with type 2 diabetes mellitus (the FIELD study): randomised controlled trial. *Lancet* 2005, 366:1849-1861.
13. Harding SP, Broadbent DM, Neoh C et al. Sensitivity and specificity of photography and direct ophthalmoscopy in screening for sight threatening eye disease: the Liverpool diabetic eye study. *BMJ* 1995; 311: 1131-5.
14. Diabetes control and complications trial. The relationship of glycemic exposure (HbA1c) to the risk of development and progression of retinopathy in the diabetes control and complications trial. *Diabetes* 1995 Aug;44(8):968-83.
15. White NH, Sun W, Cleary PA, Danis RP, Davis MD, Hainsworth DP, Hubbard LD, Lachin JM, Nathan DM. Prolonged effect of intensive therapy on the risk of retinopathy complications in patients with type 1 diabetes mellitus: 10 years after the Diabetes Control and Complications Trial. *Arch Ophthalmol* 2008; 126 (12): 1707-1715.
16. Royal college of Ophthalmologists. Diabetic retinopathy guidelines 2012 <http://www.rcophth.ac.uk/page.asp?section=451§ionTitle=Clinical+Guidelines> (Accessed 4th August 2013)

17. Chew EY, Klein ML, Ferris FL III, Remaley NA, Murphy RP, Chantry K, et al. Association of elevated serum lipid levels with retinal hard exudate in diabetic retinopathy. Early Treatment Diabetic Retinopathy Study (ETDRS) Report 22. *Arch Ophthalmol* 1996;114:1079-84.
18. Colhoun HM, Betteridge DJ, Durrington PN, Hitman GA, Neil HA, Livingstone SJ, Thomason MJ, Mackness MI, Charlton-Menys V, Fuller JH; CARDS investigators. Primary prevention of cardiovascular disease with atorvastatin in type 2 diabetes in the Collaborative Atorvastatin Diabetes Study (CARDS): multicentre randomised placebo-controlled trial. *Lancet*. 2004 Aug 21-27;364(9435):685-96.
19. American Diabetes Association. Management of Dyslipidemia in Adults in Diabetes. *Diabetes Care* 2007; 25 (1): S74-S77.
20. Merante D, Menchini F, Truitt KE, Bandello FM. Diabetic macular edema: correlations with available diabetes therapies--evidence across a qualitative review of published literature from MEDLINE and EMBASE. *Drug Saf*. 2010 Aug 1;33(8):643-52.
21. Davis MD et al. Effect of Ruboxistaurin on the Visual Acuity Decline Associated with Long-standing Diabetic Macular Edema. *Investigative Ophthalmology and Visual Science* 2009; 50 (1): 1-4.
22. Aiello LP et al. Oral Protein Kinase C β Inhibition using Ruboxistaurin: Efficacy, Safety and Causes of Vision Loss Among 813 Patients (1392 eyes) with Diabetic Retinopathy in the Protein Kinase C β Inhibitor-Diabetic Retinopathy Study and the Protein Kinase C β Inhibitor-Diabetic Retinopathy Study 2. *Retina* 2011; 31 (10): 2084-2094.
23. Li R, Zhang P, Barker LE, Chowdhury FM, Zhang X. Cost-effectiveness of interventions to prevent and control diabetes mellitus: a systematic review. *Diabetes Care* 2010; 33(8):1872-94.
24. Jones S, Edwards RT. Diabetic retinopathy screening: a systematic review of the economic evidence. *Diabetic Medicine*. 2010; 27: 249-256.
25. Mash B, Powell D, du Plessis F, van Vuuren U, Michalowska M, Levitt N. Screening for diabetic retinopathy in primary care with a mobile fundal camera--evaluation of a South African pilot project. *S Afr Med J*. 2007 Dec;97(12):1284-8.
26. Mumba M, Hall A, Lewallen S. Compliance with eye screening examinations among diabetic patients at a Tanzanian referral hospital. *Ophthalmic Epidemiol*. 2007 Sep-Oct;14(5):306-10.
27. NHS Diabetic eye screening programme. <http://diabeticeye.screening.nhs.uk> Accessed 8th February 2013
28. The Diabetic Retinopathy Study Research Group. Photocoagulation treatment of proliferative diabetic retinopathy. Clinical application of Diabetic Retinopathy Study (DRS) findings, DRS Report Number 8. *Ophthalmology* 1981; 88: 583-600.
29. Early Treatment Diabetic Retinopathy Study research group. Photocoagulation for diabetic macular edema. Early Treatment Diabetic Retinopathy Study report number 1. *Arch Ophthal* 1985; 103: 1796-1806
30. DRCR Network. Beck RW, Edwards AR, Aiello LP et al. Three-year follow-up of a randomized trial comparing focal/grid photocoagulation and intravitreal triamcinolone for diabetic macular edema. *Arch Ophthalmol* 2009; 127(3):245-251.
31. DRCR Network. Elman MJ, Aiello LP, Beck RW et al. Randomized Trial Evaluating Ranibizumab Plus Prompt or Deferred Laser or Triamcinolone Plus Prompt Laser for Diabetic Macular Edema. *Ophthalmology*; 117(6): 1064-1077.
32. Campochiaro PA, Brown DM, Pearson A, Chen S, Boyer D, Ruiz-Moreno J, Garretson B, Gupta A, Hariprasad SM, Bailey C, Reichel E, Soubrane G, Kapik B, Billman K, Kane FE, Green K; FAME Study Group Sustained Delivery Fluocinolone Acetonide Vitreous Inserts Provide Benefit for at Least 3 Years in Patients with Diabetic Macular Edema. *Ophthalmology*. 2012 Jun 21. [Epub ahead of print]
33. Boulton M. VEGF localisation in diabetic retinopathy. *British Journal of Ophthalmology* 1998; 82: 561-568.
34. DRCR network. Randomized Trial Evaluating Ranibizumab Plus Prompt or Deferred Laser or Triamcinolone Plus Prompt Laser for Diabetic Macular Edema. *Ophthalmology*. 2010; 117:1064-1077.
35. Rajendram R, Fraser-Bell S, Kaines A, Michaelides M, Hamilton RD, Esposti SD et al. A 2-Year Prospective Randomized Controlled Trial of Intravitreal Bevacizumab or Laser Therapy (BOLT) in the Management of Diabetic Macular Edema: 24-Month Data: Report 3. *Arch.Ophthalmol*. 2012; 130: 972-979
36. Tao Y, Jiang YR, Li XX, Gao L, Jonas JB. Long-term results of vitrectomy without endotamponade in proliferative diabetic retinopathy with tractional retinal detachment. *Retina*. 2010 Mar;30(3):447-51.
37. Glover SJ et al. Prevalence of diabetic retinopathy, cataract and visual impairment in patients with diabetes in sub-Saharan Africa. *British Journal of Ophthalmology* 2012; 96 (2): 156-161.
38. Bradshaw D, et al: Estimating the burden of disease attributable to diabetes in South Africa in 2000. *S Afr Med J* 2007, 97(8 Pt 2):700-6.
39. Report on the United Nations high level meeting on non-communicable disease prevention and control. http://www.who.int/nmh/events/un_ncd_summit2011/en/. Accessed 4th February 2013
40. Burgess PI, Msukwa G, Beare NAV. Diabetic retinopathy in Sub-Saharan Africa: meeting the challenges of an emerging epidemic. *BMC Medicine*. 2013 Jul 2;11:157