

# Case Report - A 6 year-old boy was referred from a district hospital with congestive cardiac failure

A Selman, E Molyneux, N Kennedy

1. Dept Paediatrics Queen Elizabeth Central Hospital,

## Presentantion of the case

A 6 year-old boy was referred from a district hospital with congestive cardiac failure.

His mother reported that he had become progressively short of breath over the previous two months and in the last month he had developed swelling of his feet and abdomen. He had orthopnoea and a marked decrease in exercise tolerance over the two weeks prior to attending hospital.

He had been given several courses of oral antibiotics from a local health centre since the beginning of his symptoms and had been admitted at the district hospital for eleven days prior to transfer. There he had received a course of intravenous antibiotics and frusemide and intramuscular quinine. Apart from a slight improvement in his oedema, there was little change clinically.

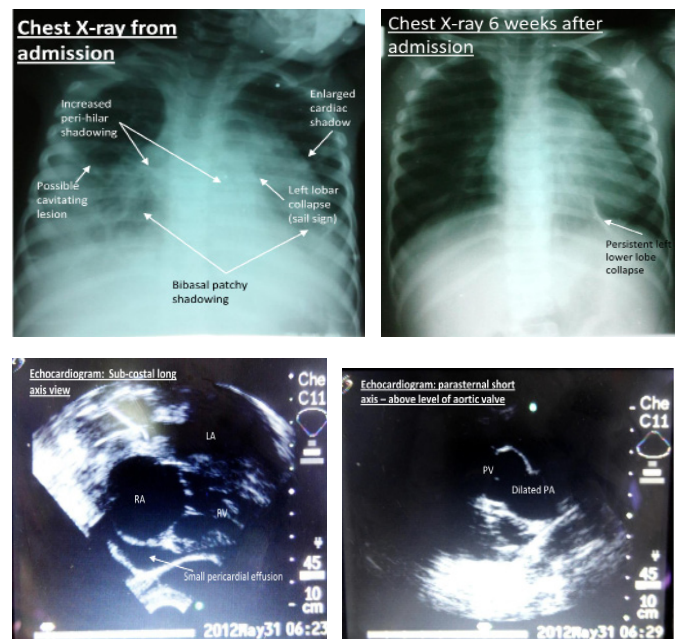
On admission he was tachypnoeic, lethargic and miserable looking. He was grossly oedematous with pitting oedema to his sacrum and abdominal ascites. On auscultation breath sounds were decreased bibasally with crepitations throughout both lungs. His liver was soft but palpable 6cm below the costal margin. His pulse was 128/min, respiratory rate 80/min, and blood pressure 94/45mmHg. Oxygen saturation measurement was 90% in 3l/min oxygen via nasal cannulae and 60% in air.

His chest x-ray showed an enlarged cardiac shadow with peri-hilar shadowing, patchy shadowing of both bases and evidence of lobar collapse in the left lower zone.

An echocardiogram showed a dilated right atrium and ventricle with a normal pulmonary valve and dilated pulmonary artery. There were no abnormalities on the left side of the heart other than some compression of the left ventricle by the enlarged right ventricle. There was a small, clinically insignificant pericardial effusion. Marked tricuspid regurgitation was noted, measuring around 4m/s on continuous wave Doppler.

With the initial findings a diagnosis of cor pulmonale was made secondary to an unknown lung pathology, possibly chronic lung disease but most likely pulmonary tuberculosis. In view of this he was treated for right sided heart failure with an increased dose of frusemide and with oxygen, as well as for atypical pneumonia and TB. His HIV test was negative. After seven days as an inpatient his symptoms improved and he was well enough to be discharged home on TB treatment, oral frusemide and enalapril.

Six weeks after discharge, when he was seen in the cardiac clinic, all of his symptoms had resolved and his mother reported a normal exercise tolerance. His oedema and hepatomegaly had resolved. His chest x-ray showed resolution of many of the initial changes with some continuing evidence of left lower lobe collapse.



## Discussion

Generalised oedema is seen relatively frequently in children presenting to the emergency department in Malawi and a careful history will give important clues as to the appropriate investigations needed to aid in identifying the underlying cause. Important causes are:

- Nutritional – kwashiorkor
- Cardiac failure – e.g. congestive cardiac failure associated with rheumatic heart disease or right heart failure (many causes for both right and left heart failure)
- Renal – nephrotic and nephritic syndromes
- Hepatic failure (many causes)

Cor pulmonale is right ventricular failure as a consequence of pulmonary arterial hypertension related to either underlying lung disease, idiopathic pulmonary hypertension, upper airways disease (e.g. obstructive sleep apnoea) or chest wall disease (e.g. kyphoscoliosis). In all of these disease processes, chronic hypoxia causes pulmonary vasoconstriction and the rise in pulmonary vascular resistance eventually causes the right ventricle to become hypertrophied and/or dilated and right ventricular failure follows.<sup>1</sup>

Cor pulmonale and chronic lung disease are relatively uncommon in children, but there are a number of possible causes. In wealthier nations the most common cause of chronic lung disease in infancy is broncho-pulmonary dysplasia.<sup>2, 3</sup> It occurs in children who had a very low or low birth weight and received mechanical ventilation as a neonate for neonatal respiratory distress syndrome. Other causes of chronic lung disease are those due to a primary underlying cause (e.g. cystic fibrosis or ciliary dyskinesias) or a secondary process such as infection (e.g. TB, bronchiectasis). In Malawi, pulmonary TB is an important cause of paediatric lung disease.<sup>4</sup>

If cor pulmonale is suspected in a Malawian child, investigation and treatment of pulmonary TB with a Mantoux test, chest

x-ray and TB medication should be considered after careful history taking and examination to exclude other causes.

It is important to note that the district hospital were able to make the correct diagnosis of cardiac failure using history, clinical examination and a chest x-ray alone and without an echocardiogram. The child was treated appropriately with antibiotics at the health centre and then frusemide when his symptoms did not improve. The interventions at QECH that probably made a difference in this case were twofold. Firstly the use of oxygen therapy which would have improved the child's pulmonary hypertension by reducing pulmonary artery vasoconstriction as a direct effect and secondly the use of anti-TB medications for a prolonged period.

In the case of giving oxygen, it is important for healthcare workers in district hospitals to identify the need of oxygen therapy in these children by measuring their oxygen saturations and monitoring the child's response to initial management with antibiotics and frusemide. They could also include a Mantoux test and TB treatment at this stage. If

oxygen therapy is not available the healthcare worker should consider if it is appropriate to transfer the child to a centre that has oxygen available early in the course of treatment.

## References

1. Budev MM, Arroliga AC, Wiedemann HP, Matthay RA. Cor pulmonale: an overview. *Seminars in respiratory and critical care medicine*. 2003;24(3):233-44.
2. Eber E, Zach MS. Long term sequelae of bronchopulmonary dysplasia (chronic lung disease of infancy). *Thorax*. 2001;56(4):317-23.
3. Ivy D. Advances in pediatric pulmonary arterial hypertension. *Current opinion in cardiology*. 2012;27(2):70-81.
4. Gordon S, Graham S. Epidemiology of respiratory disease in Malawi. *Malawi Medical Journal*. 2007;18:134-46.

