

SURVEY OF TEN CASES OF EARLY INFANTILE EPILEPTIC ENCEPHALOPATHY (OHTAHARA SYNDROME)

A. NASIRIAN, M.D.

*From the Department of Pediatric Neurology, Children's Medical Center, Tehran University of Medical
Sciences, Tehran, I.R. Iran.*

ABSTRACT

Early infantile epileptic encephalopathy or EIEE (Ohtahara syndrome; OS) is a kind of intractable seizure that begins in neonatal age with sudden onset of tonic spasms in series or single suppression-burst S-B in EEG.¹ Imaging shows anatomic defects such as migration disorders and generalized atrophy² with essentially normal metabolic tests. The seizures often change to West's syndrome (WS) or Lennox Gaustaut syndrome (LGS) pattern.³ Ohtahara et al. first described this syndrome in 1976.³ We observed ten cases of this syndrome during a period of 12 months. 70% of the patients were male. The mean age at the time of onset of seizures was 8 days; the mean age at the time of admission was 6.8 months. In 20% of cases the first seizures were generalized, in 80% tonic. EEG at the time of referring showed suppression-burst S-B in 50%, hypsarrhythmia in another and in 60% of them there were scattered sharp, spike or spike and wave in one or both sides. The drugs that have been used in multiple therapy were clonazepam 50%, prednisone 60%, sodium valproate 30%, nitrazepam 20%, vigabatrin 30% and acetazolamide in 10%. Response to treatment was good in 70% and moderate in 30%. At the end of the course all patients showed severe mental and motor retardation. Prognosis was shown to be poor in these patients.

MJIRI, Vol. 18, No. 2, 135-139, 2004.

Keywords: Early infantile epilepsy with suppression-bursts; EIEE; Intractable infantile seizure; Ohtahara syndrome; OS; Early myoclonic encephalopathy.

INTRODUCTION

Early infantile epileptic encephalopathy (EIEE) with suppression-burst (SB) was first described by Ohtahara et al. in 1976 as the earliest form of age-dependent epileptic encephalopathy.¹ The clinical signs and symptoms of OS syndrome are characterized by frequent tonic spasms with very early onset within the first few months of life.² The attacks have displacing nature that is mostly intractable.⁴ Tonic spasms occur not only when awake but also in sleeping state in most cases.⁴

EEG shows SB pattern that is persistently observed regardless of circadian cycle-bursts of 1-3/s duration alternating with a nearly flat suppression phase of 2-5/s at approximately regular rates; 5-10/s burst-burst interval. Some asymmetry in SB is noted in about two-thirds of

cases.⁵ Ictal EEG of tonic spasms shows principally desynchronization with or without initial rapid activity.⁶ Tonic spasms appear concomitant with bursts. EIEE is an age-dependent epileptic encephalopathy representing as OS, West syndrome (WS) and Lennox-Gastaut syndrome (LGS).⁷

Transitional I-S is often observed with age among these syndromes. Seventy-five percent of OS cases evolve into WS and they consist of 2.6% of WS, 5.9% of WS evolves to LGS. Such mutual transition with age supports the inclusive term age-dependent epileptic encephalopathy; there may be other forms of epilepsy such as partial and partial complex epilepsy.¹

The etiology of OS is heterogeneous, including organic and static brain lesions as well as brain malformations such as hemi-megalencephaly, porencephaly,

Aicardi syndrome, olivary-dentate dysplasia, agenesis of mamillary bodies, linear sebaceous nevus syndrome and focal cortical dysplasia.⁴ Even cytochrome oxidase deficiency and Leigh encephalopathy have been reported. Cryptogenic cases that have no detectable cause are highly suspicious to have undetectable migration disorder or microdysgenesis. No familial occurrence has been reported.⁸

In all of our cases CT-scan and MRI revealed structural abnormalities. All of them had cortical atrophy, 3 cases had dysgenesis of corpus callosum, 4 migration disorder, 4 hydrocephalus and one lissencephaly and porencephaly.

Pathophysiology

This syndrome is one of the age-dependent epileptic reactions to various non-specific exogenous brain insults acting at the specific developmental stages.⁵ The pathophysiological mechanism of S-B is not clarified.⁹ Spreafico et al. suspected that retention of early-generated neurons, which are necessary during neocortical histogenesis but programmed to apoptosis before or soon after birth, in the white matter may cause sub-cortico-cortical disconnection, presenting the suppression-burst of OS.¹⁰ Asymmetric S-B pattern dominantly appearing in the malformed hemisphere in hemimegalencephaly apparently suggests the indispensable role of brain lesion extending diffusely sub-cortical to cortical.¹¹

Treatment

Seizures in OS are resistant to treatment.⁹ Benzodiazepines, valproate, ACTH, and steroids have been often tried, but their efficacy is limited. Thyrotropin releasing hormone (TRH) and a ketogenic diet have a partial effect in some cases. Gamma-globulin treatment is reported to have considerable efficacy, and recently vigabatrine has been suggested to be the first choice drug.⁹

Successful resection is reported in those with focal cortical dysplasia, in whom relatively better development was achieved postoperatively.⁸

Prognosis

OS has a poor prognosis. Seizures are very intractable. Although seizures are possibly suppressed by school age in about half of the patients, developmental delay is very severe and the children are severely handicapped both mentally and physically. Mortality is high especially in infancy.

Grades of response to the drugs:

1. Excellent (patient is free of seizures).
2. Good (75% relief).
3. Moderate (50% relief).
4. Poor (below 25% relief).

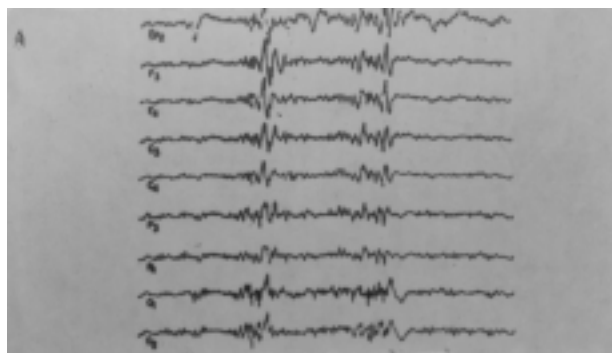


Fig. 1. Suppression-burst at beginning.

MATERIAL AND METHODS

In the period between September 2000 through August 2001, ten patients with early infantile epileptic encephalopathy were admitted in the pediatric neurology ward of Children's Medical Center, and their chief complaint was early onset of intractable seizures. The history, clinical examination, laboratory study, EEG and imaging were suggestive of OS syndrome. We conducted a survey of their ward records regarding age, sex, age of onset, characteristics of the first seizures, primary treatment, type of late seizures, kind of delivery, head circumference, developmental milestones, EEG pattern, imaging (CT, MRI), liver and metabolic tests, drugs used, response to treatment, and final outcome.

RESULTS

Survey of the ward records revealed that 70% of the patients were male.

80% experienced the first seizure in the first week of life, 100% in the first month.

80% of the seizures were tonic spasms at the beginning and 20% were of the tonic and tonic-clonic, generalized type.

The age at admission was under three months in three cases, between 3-6 in three cases, between 6-9 months in 3 cases and one year in 1 case.

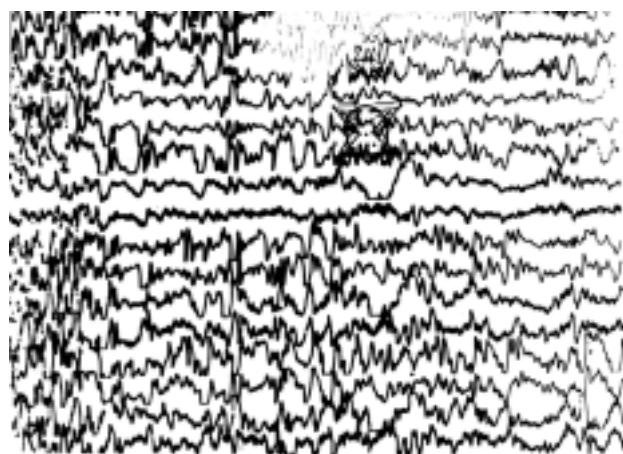
During the hospital stay 50% had infantile spasms (WS) and others had infantile myoclonic epilepsy, in 60% of whom there was a mixed type of epilepsy with partial, partial complex or generalized epilepsy and Lennox-Gastaut syndrome.

All patients had severe developmental delay and microcephaly.

The EEG in six cases showed suppression-burst and in four cases hypersarhythmia. In five of them additional

Table I. The special data of the patients.

No.	Name	Sex	Age at the beginning	Age of referral	Chief complaint
1	Amir M	male	1 day	9 months	tonic spasms, in series, single
2	Hadi R	male	3 days	9 months	tonic spasms in series, apnea.
3	Rayan A	male	2 days	45 days	tonic spasms, myoclonic seizures
4	Hosein A	male	4 days	20 days	tonic spasms in series, opisthotonus
5	Hashem T	male	1 week	2 months	tonic spasms in series, eye fixation
6	Zahra J	female	1 day	4 months	intractable generalized seizures
7	Hasan E	male	5 days	8 months	tonic spasms in series, opisthotonus
8	Fateme R	female	15 days	6 months	tonic series, generalized seizures
9	Shiva K	female	1 month	7/5 months	tonic spasms in series, single
10	Ali L	male	1 day	12 months	tonic series, partial complex epilepsy

**Fig. 2.** Hypsarrhythmia after 6 months.

scattered slow, sharp, spike waves were observed.

All of the patients had negative metabolic tests (ammonia-lactate-T4, T3, PKU, urine amino acids chromatography).

In the MRI all had brain atrophy. 5 cases had migration, 3 cases Aicardi syndrome, 4 cases hydrocephalus and one case porencephaly with lissencephaly.

The first drugs in the beginning were phenobarbital and phenytoin in 4 cases, and only phenobarbital in 6 cases. All of them responded poorly to treatment.

Drugs administered in hospital were prednisone in 7 cases, valproate in 5 cases, clonazepam in 4 cases, nitrazepam in 3 cases, vigabatrin in 2 cases, and acetazolamide in one case.

All of them had poly-therapy with 2 or 3 drugs. Seven cases had good and three cases moderate response to therapy. Cases that received clonazepam responded

much better than the others.

DISCUSSION

The diagnosis of the Ohtahara syndrome (EIEE) is based on the existence of the clinical, EEG and imaging signs and symptoms with early intractable seizures beginning from the neonatal period and EEG pattern of burst-suppression in the awake and sleep state,¹² severe developmental delay and clinically tonic spasms.⁶

Additional symptoms consist of structural defects such as atrophy, ventricular enlargement, migration and corpus callosum dysgenesis.¹³

In 11 out of 12 cases reported by Miller et al. in McGill Hospital, Canada, there were severe cortical deficits, two cases of encephalopathy, and two cases of Aicardi syndrome. Another study reported Aicardi syndrome and hemimegalencephaly being predominant malformations with burst-suppression EEG pattern.¹¹ In a series of 16 cases reported by Yamatogi and Ohtahara at October 2001, 9 cases were male and 7 female, the age of OS (the first seizures) was 1-63 days. All of them had tonic spasms in series at the beginning that changed in the following months to complex epilepsy, and all of them had severe mental and motor retardation.¹ In our ten cases all had brain atrophy, 3 cases Aicardi syndrome, 5 cases migrational defects, 1 case mixed porencephaly and lissencephaly. All of them were severely retarded and immobile.

Pathophysiology

Postmortem pathology was significant for a cerebral maturation disorder with diffuse subtle microdysgenesis of the cerebral cortex,¹³ abnormal formation with granular cell loss and cellular dispersion with accompanying astrogliosis and abnormal clusters of immature neurons

Early Infantile Epileptic Encephalopathy

Table II. Types of epilepsy, clinical signs and symptoms and EEG patterns.

Seizures at hospitalization time	Developmental state	EEG pattern	Metabolic tests
1. Infantile spasms partial epilepsy	no head control quadriparesis	suppression-burst scattered slow, sharp	negative
2. infantile spasms and partial complex epilepsy	severely retarded microcephaly	paroxysmal slow, sharp hypsarrhythmia	—
3. infantile myoclonic, Partial epilepsy	developmental delay microcephaly	suppression-burst slow, sharp in left side	—
4-myoclonic-jerky movements opistotonus postures	severe retardation spastic quadriplegia	suppression-burst	—
5. myoclonic and Partial complex epilepsy	microcephaly, poor cognition, hypotonia	generalized slowing suppression-burst	—
6. infantile spasms	severe developmental delay and spasticity	cortical dysfunction, hypsarrhythmia	—
7. Infantile spasms, Generalized tonic- clonic	microcephaly, severe retardation	hypsarrhythmia	—
8. Partial complex and myoclonic epilepsy	microcephaly, poor cognition, spastic quadriplegia	suppression-burst slow, sharp in right	—
9. infantile spasms, Generalized seizures	developmental delay, microcephaly	hypsarrhythmia	—
10. Infantile myoclonic Partial seizures	spasticity, poor cognition, microcephaly	suppression-burst scattered slow, sharp	—

Table III. MRI findings, first and second drugs used and response to drugs.

MRI findings	First drugs	Response	Second drugs	Response
1. Brain atrophy, hydrocephaly Corpus calosum hypoplegia	phenobarb phenytoin	poor	clonazepam prednisone	good
2. Migration, Brain atrophy hydrocephaly	phenobarb	poor	prednisone clonazepam acetazolamide	good
3. Brain atrophy, migrational lesions	phenobarb	poor	prednisone sodium valproate nitrazepam	moderate
4. Brain atrophy Migration	phenobarb	poor	prednisone clonazepam sodium valproate	good
5. Loss of corpus calosum Brain atrophy	phenobarb	moderate	clonazepam prednisone	good
6. Cortical atrophy Hydrocephaly	phenytoin phenobarb	moderate	prednisone sodium valproate	good
7. Brain atrophy migration	phenobarb phenitoin	poor	nitrazepam sodium valproate	good
8. Thin corpus calosum brain atrophy	phenytoin phenobarb	poor	clonazepam vigabatrine	moderate
9. Lissencephaly, atrophy hydrancephaly	phenobarb	poor	prednisone clonazepam	good
10. Migration, atrophy	phenobarb	poor	prednisone nitrazepam	moderate

in both amygdale nuclei. In addition, there was bilateral enlargement of the dentate nucleus with loss of the normal ribbon undulation and thick multinodal appearance.¹¹ Similar changes were seen in both olivary nuclei. These changes may not be disclosable on neuroimaging. Other pathology reports also reflect late malformations of cortical development.¹⁰

The underlying neuronal mechanisms of seizures in EIEE exist as neurocortical GABAergic synaptic abnormalities.¹³ Decrease in GABAergic inhibition is likely in part responsible for the epileptogenicity of malformations of cortical development.¹³ Reduction of GABA in the CSF of these patients is predominant. Virtually all cases of the EIEE are secondary to congenital or acquired structural malformation of cortical development.¹⁰

The etiology remains obscure.⁴ The role of GABA in EIEE and epileptogenicity of malformations of cortical development requires further investigation to elucidate possible causal mechanisms.¹³

Differential diagnosis

From the neonatal to early-infantile period, seizures are relatively rarely observable compared with other periods of childhood because of the structural and functional immaturity of the brain. Only a few epileptic syndromes begin to occur in this period and most of them are severe epilepsies.¹⁴ Peculiar representatives are OS and early myoclonic epilepsy (EME).¹⁵ Both syndromes are classified into symptomatic generalized epilepsies with non-specific etiology and could be inclusively called early-infantile epileptic syndrome with SB because of shared common characteristics, very early onset with frequent minor seizures and a SB pattern on EEG.¹¹

WS of very early onset, and neonatal hypoxic encephalopathy with burst-suppression pattern are also to be differentiated.¹⁴

Early myoclonic epilepsy (EME), first described by Aicardi and Goutieres in 1978, is a rare epileptic syndrome of very early onset with frequent myoclonus and partial seizures and S-B in EEG. As EME and OS have common clinico-electrical characteristics, such as early onset within a few months of life, and the S-B pattern in EEG, differentiation is important.

Etiologically, OS is usually based on static organic brain lesions including brain malformations which neuroimaging demonstrate, namely static encephalopathy. In contrast, reported cases with various metabolic disorders and the frequent incidence of familial cases suggest determined or undetermined inborn metabolic disorders as the etiology in EME, namely metabolic en-

cephalopathy.

REFERENCES

1. Yyamatogi Y, Ohtahara S: Early-infantile epileptic encephalopathy with suppression-bursts, Ohtahara syndrome; its overview referring to our 16 cases. *Brain & Development* 24: 13-23, 2002.
2. Watanabe K, Miura K, Natsumi J, Hayakawa F, Furune S, Okumura A: Epilepsies of neonatal onset: seizure type and evolution. *Dev Med Child Neurol* 41: 318-322, 1999.
3. Miller SP, Dilenge E, Meagher K, et al: Infantile epileptic encephalopathy (Ohtahara syndrome) and emigrational disorder. *Pediatric Neurology* 19 (1): 35-39, 1998.
4. Trika E, Rauscher C, Nagler M, Moroder T, Ladurner G, Irnberger E, et al: A case of Ohtahara syndrome with olivary-dentate dysplasia and agenesis of mamillary bodies. *Epilepsia* 42: 950-953, 2001.
5. Clake M, Gill J, Noronha M, Mckilay L: Early infantile epileptic encephalopathy with suppression-burst: Ohtahara syndrome. *Dev Med Child Neurol* 29: 520-528, 1987.
6. Ohtahara S: Clinico-electrical delineation of epileptic encephalopathies in childhood. *Asian Med J* 21: 499-509, 1978.
7. Keneth F: *Swaiman Pediatric Neurology. Principles and Practice*. Mosby, p. 187, 1999.
8. Pedespan JM, Loiseau H, Vital A, Marchal C, Fontan D, Rougier A: Surgical treatment an early epileptic encephalopathy with suppression-bursts and focal cortical dysplasia. *Epilepsia* 36: 37-40, 1995.
9. Ishii Mtamai K, Sugita K, Tanabe Y: Effectiveness of TRH analog in a case of early infantile epileptic encephalopathy (in Japanese). *No to Hattatsu (Tokyo)* 22: 507-511, 1990.
10. Avoli M, Mattia D, Oliver A, Villemure JG: Microphysiology of human neocortex in vitro. In: Guerrini R, Anderman F, Canapicchi R, Roger J, Zikin BG, Pfanne P, (eds.), *Dysplasias of cerebral cortex and epilepsy*. Philadelphia: Lippincott-Raven, pp. 35-42, 1996.
11. Dalla Bernadina B, Dulac O, Fjerman N, et al: Early myoclonic epileptic encephalopathy. *Eur J Pediatr* 140: 248-52, 1983.
12. Aicardi J: Goutieres encephalopathy myclonic neonatal. *Rev EEG Neurophysiology* 32: 99-101, 1978.
13. Rabin O, Dulac O: Early epileptic encephalopathy with suppression-burst and olivary dentate dysplasia. *Neuropediatrics* 23: 16-40, 1992.
14. Volp J: *Neurology of the newborn*. Third edition, W.B. Saunders Company, pp. 172-177, 1995.
15. Ohtahara S: The early infantile epileptic encephalopathy with suppression-burst: developmental aspects. *Brain Dev* 9: 37-6, 1987.