

**BENIGN CLINICAL PICTURE
AFTER INGESTION OF 780
MILLIGRAMS OF ARIPIPRAZOLE
AND 1050 MILLIGRAMS OF
AMITRIPTYLINE**

Sir,

Intentional psychotropic overdose is a common cause of fatal complications in psychiatric patients. In addition to the much discussed antidepressant overdoses, antipsychotic

medication abuse has also become fairly common as revealed by recent studies.^[1,2] In such a scenario, safety of psychotropic medications in overdose becomes an important issue in the management of suicide-prone patients. Aripiprazole is a novel second-generation antipsychotic which received FDA approval in 2002 for adults. Its overdose has been occasionally reported in literature. We report a case of intentional poisoning by very high doses of Aripiprazole (780mg) and Amitryptiline (1050 mg) with minimal complications, with a brief review.

A 26-year-old male presented to the emergency department of our institution at around 9:20 PM with the complaints of having ingested 26 tablets of 30 mg of Aripiprazole (= 780 mg) and 42 tablets of 25 mg of Amitryptiline (= 1050 mg). This event occurred 6 hours previously. After a quarrel with his family, the patient decided to end his life. Subsequently, he went to his room and ingested all the abovementioned medications so that he emptied the whole box. Immediately, he had a sudden dizziness and fall. Family rushed to the scene where they counted the medication. They also searched if the patient had used any other chemical but there was no trace of any other medication/ chemical on the patient's mouth, his clothes, in the room, which was a closed one, or outside the window. The patient was conscious all the time and accepted having ingested these medications in exactly the same amount as counted. The problems of dizziness and unstable gait improved in a couple of hours. The patient was completely oriented to time, place and person. A rapidly conducted neurological examination did not reveal any abnormality in his higher mental

functions (calculations, recent memory, frontal lobe functions), cranial nerves, gait, cerebellar functions or other extrapyramidal functions. His pulse rate was raised at 124 /min and the blood pressure was high (148/94 mm Hg). His respiratory rate was 16/min. He had passed urine twice since the act. He was eating on his own. The mental status examination revealed slowing of psychomotor activity, dysphoric effect and no other psychopathology. Questioned on his reasons for acting thus, he replied that he was fine but the quarrel with family triggered the thought that his life was worthless. He had ingested all the medications present at home with the purpose of ending his life. The patient was immediately referred to a nearby medical setup for a complete systemic examination and further management. A 12 lead electrocardiogram and ultrasonographic examination of abdomen were performed. Both the investigations revealed normal findings [Figure 1]. Subsequently a gastric lavage was performed and he was given injection Pancef (1 ampoule). After 8 hours of the procedure, he was discharged and was referred back to our institute. Retrieval of his file in our institute revealed that he was

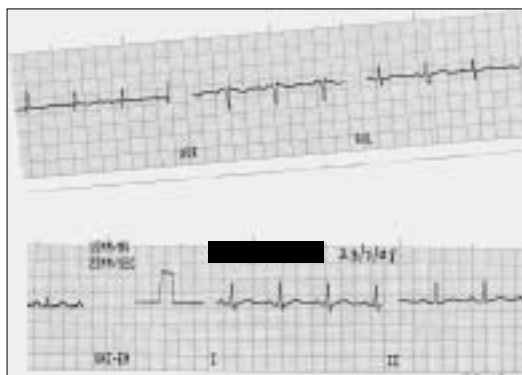


Figure 1: 12 lead electrocardiogram of the patient before the gastric lavage showing normal recording

a patient of recurrent depressive disorder, stabilized on the abovementioned medications. Subsequently, Amytriptyline was replaced by Escitalopram and Aripiprazole was maintained in the same dose. A phone call after 10 days of the intervention revealed that he was showing improvement in his condition and did not make any similar attempts.

Among the antidepressants, Amitriptyline has been one of those most commonly associated with death when used in overdose.^[3] Symptoms usually appear within 4 hours of an overdose and recovery can be expected within 24 hours provided the poisoning is not severe. Common clinical features are its anticholinergic, and CNS symptoms. The most frequent findings on the ECG are prolongation of the PR and QT intervals.^[4,10] In our patient, in spite of the apparently high dose intake of this much feared agent, only the transiently elevated blood pressure and heart rate were observed. Such high dose intake in the range 13.6/kg- 17.7mg/kg was associated with severe complications in children as per a recent study.^[5] A speculative proposition could be that the long-term use (>4 yrs) of Amitriptyline created tolerance for the dose. This hypothetical situation is worth consideration as there are reports where daily doses as high as 800 mg/day have been tolerated when used for a long time for abuse.^[6,7]

Aripiprazole acts by exhibiting high-affinity partial agonist activity at D2-dopamine receptors.^[8] In a few years after its FDA approval, it has earned the reputation of having a benign side effect profile. Its overdose has been occasionally reported. Our literature search revealed 8 cases of Aripiprazole

overdose till date, most of them being in children. Clinical presentation ranged from no symptoms to extreme lethargy, central nervous system (CNS) depression, intentional tremor, and Parkinsonian gait.^[2] In adults fewer cases have been reported. The maximum dose reported till date is 330 mg, where the effects were limited to mild sedation.^[9] Our patient apparently tolerated more than double this dose (780 mg). The excessive sedation, dizziness and instability of gait for a few hours could have been due to this overdose, however these can be equally attributed to Amytriptyline. This adds to the literature of this new molecule in terms of its safety in high doses.

**RAVI PRAKASH, SANJAY MUNDA,
AMRIT PATTOJOSHI,
PRANAV PRAKASH CHOUDHARY**
Central Institute of Psychiatry, Kanke,
Ranchi- 834006, Jharkhand, India

Correspondence:

Dr. Ravi Prakash,
Central Institute of Psychiatry, Boys Hostel No.1; Room No.10,
Kanke, Ranchi- 834 006, Jharkhand, India.
E-mail: drravi2121@gmail.com

REFERENCES

1. Watson WA, Litovitz TL, Klein-Schwartz W, Rodgers GC Jr, Youniss J, Reid N, *et al.* 2003 annual report of the American association of poison control centers toxic exposure surveillance system. *Am J Emerg Med* 2004;22:335-404.
2. Antia SX, Sholevar EH, Baron DA. Overdoses and ingestions of second-generation antipsychotics in children and adolescents. *J Chil Adol Psychophar* 2005;15:970-85.
3. Henry JA, Alexander CA, Sener EK. Relative mortality from overdose of antidepressants. *BMJ* 1995;310:221-4.
4. Lieberman J. Aripiprazole. In: Textbook of psychopharmacology. Schatzberg A, Nemeroff C, editors. Washington (DC): American Psychiatric

Publishing; 2004. p. 473-86.

5. Caksen H, Akbayram S, Odabaş D, Ozbek H, Erol M, Akgün C, *et al.* Acute amitriptyline intoxication: An analysis of 44 children. *Hum Exp Toxicol* 2006;25:107-10.
6. Wohleisch MM, Welch W. Amitriptyline abuse presenting as acute toxicity. *Psychosomatics* 1993;34:191-3.
7. Prahlow JA, Landrum JE. Amitriptyline abuse and misuse. *Am J Forensic Med Pathol* 2005;26:86-8.
8. Burris KD, Molski TF, Xu C. Aripiprazole: A novel antipsychotic, is a high-affinity partial agonist at human dopamine D2 receptors. *J Pharmacol Exp Ther* 2002;302:381-9.
9. Carstairs SD, Williams SR. Overdose of aripiprazole: A new type of antipsychotic. 2005;28:311-3.

DOI: 10.4103/0019-5359.49244