

Case Report

Does increased ^{18}F FDG uptake reflect malignant transformation of a low-grade glioma? A diagnostic dilemma

Laszlo Novak, Peter Molnar*, Zsolt Lengyel**, Lajos Tron**

Departments of Neurosurgery and *Pathology, **PET Study Group of the Hungarian Academy of Sciences. University of Debrecen, Health and Life Sciences Center, Hungary

Benign gliomas of the brain show decreased uptake of ^{18}F fluorodeoxyglucose (FDG) on positron emission tomography (PET). Malignant transformation is usually manifested by an increase of ^{18}F FDG uptake. A 45-year-old female has been followed up since 1987 by means of ^{18}F FDG-PET for a right hemispheric World Health Organization Grade II oligoastrocytoma. In 1996, increased epileptic activity was accompanied by increased ^{18}F FDG uptake within the temporal part of the tumor. After surgery, the epileptic seizures diminished. Histological examination of the resected tumor showed no change in the pathology when compared with the first biopsy. Localized temporal increase of ^{18}F FDG uptake was not associated with malignant progression. The decrease of seizure frequency might shed light on a putative connection of hyperglycolysis and epileptic discharges.

Key Words: ^{18}F FDG-PET, malignant transformation, ictal scan, low-grade glioma.

Introduction

Benign gliomas of the brain appear as hypometabolic areas on ^{18}F fluorodeoxyglucose positron emission tomography (^{18}F FDG-PET).^[1-3] Malignant transformation and tumor progression results in an increased ^{18}F FDG uptake.^[2-3] We present a case of a World Health Organization (WHO) Grade II oligoastrocytoma with a total present length of 17 years' survival time, despite indication – based on elevated ^{18}F FDG uptake – of malignant progression eight years previously (Table 1).

Case Report

A right frontal WHO Grade II oligoastrocytoma in a 28-year-old female was operated on in 1987. The patient stayed seizure-free un-

Table 1: The tumor-to-white matter (T/WM) and tumor-to-frontal cortex (T/C) uptake ratios in consecutive ^{18}F FDG-PET scans*

	1994	1996	1997	2000	2003
T/WM (highest)		2.36			
T/WM (85% cut-off)	0,96	0.98	0.86	1.17	1.82
T/C (highest)		1.25			
T/C (85% cut-off)	0,48	0.52	0.5	0.63	0.83

*The second resection was performed after the 1996 scan. Afterwards, no such heterogeneity of tracer uptake has been observed.

til 1994, when an infiltrating recurrence was detected. ^{18}F FDG uptake was not elevated (Figure 1a). Partial temporal seizure activity became uncontrollable in 1996 with tumor extension towards the temporal lobe and the midline structures. The ^{18}F FDG-PET showed increased tracer uptake in the temporal region suggesting the possibility of malignant transformation (Figure 1b). The tumor then was repeatedly resected with evidence of residual parts in surgically inaccessible ganglionic structures. After surgery, the patient became seizure-free again. Histology of the second partial resection from the region of highest ^{18}F FDG uptake turned out to be the same WHO Grade II. oligoastrocytoma (GFAP positive gemistocytes and tumor cells with fried egg appearance, no necrosis, no atypia, slight endothelial proliferation and infrequent mitosis). The repeated post-operative ^{18}F FDG-PET revealed no elevated tracer uptake within the residual parts. Following recovery from surgery, conventional irradiation and PCV chemotherapy were administered. Eight years later, to date, the patient is in clinical remission. The follow-up ^{18}F FDG-PET scans have revealed gradual elevation of tracer uptake in the residual tumor; and thus a new cycle of PCV chemotherapy has been indicated (Figure 1c).

PET investigations

All static cerebral PET scans were performed using a GE 4096 Plus PET scanner (GE Medical Systems AB, Uppsala). The patient received $104 \pm 44 \mu\text{Ci/kg}$ (mean \pm SD) ^{18}F FDG as an intravenous bolus injection in a dark, silent room 30 minutes prior to scanning. Axial scans with spatial resolution of 6.5 mm full width at half-maximum were obtained. Corrections for tissue attenuation were allowed by transmission measurements (25 min) performed before emission scans using a ^{68}Ge source of 8 mCi activity. The tumor-to-white mat-

Novak Laszlo

University of Debrecen, Health and Life Sciences Center, Department of Neurosurgery, Nagyerdei krt. 98, P. O. Box. 31, 4012 Debrecen, Hungary.
E-mail: lnovak@jaguar.dote.hu

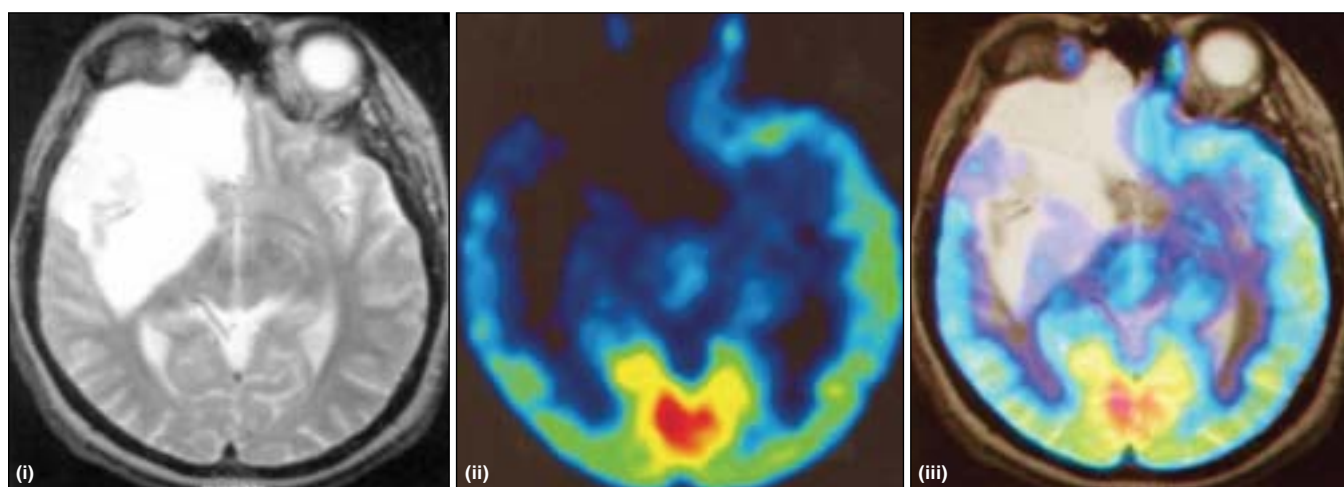


Figure 1a: Neuroradiological features in 1994. The corresponding axial slice of MRT (i), ^{18}F FDG-PET (ii) and the merged co-registered scans (iii) made after a diagnosis of the recurrent tumor. The ^{18}F FDG uptake of the whole tumor is less than the normal brain tissue's

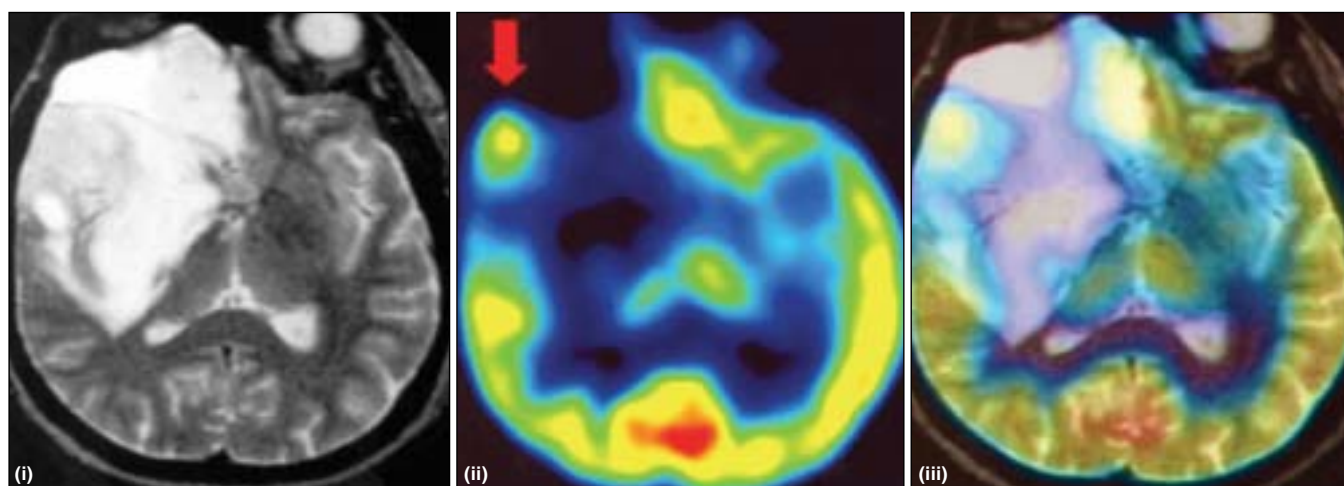


Figure 1b: Neuroradiological features in 1996. The corresponding axial slice of MRT (i) ^{18}F FDG-PET (ii) and the merged co-registered scans (iii) made before second operation in 1996 after nine years from discovery. The red arrow points out the right temporal region of elevated ^{18}F FDG uptake. The surrounding part of the tumor is hypometabolic

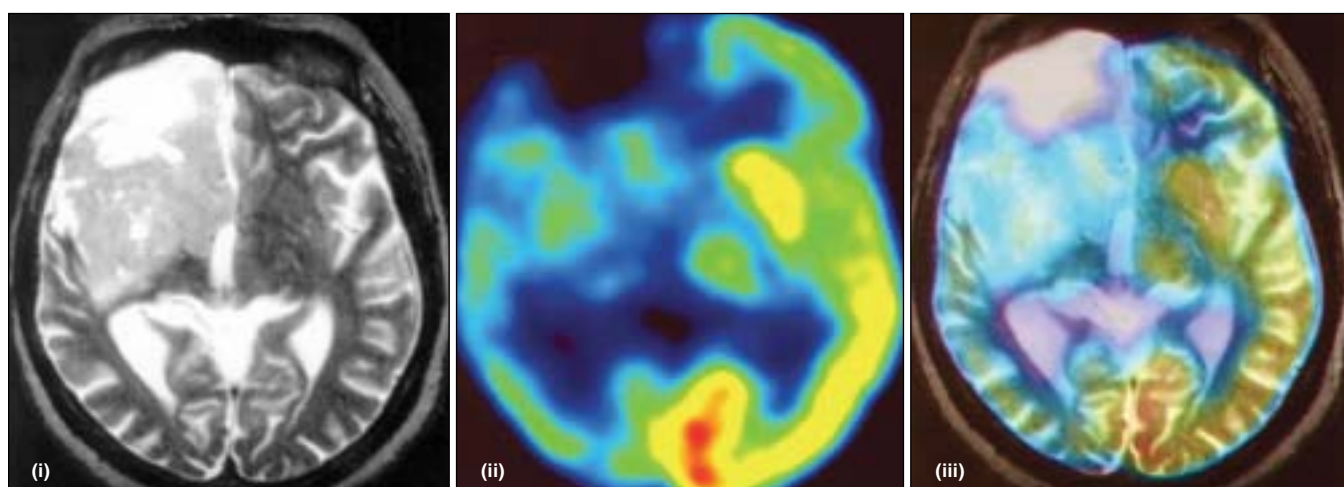


Figure 1c: Neuroradiological features in 2003. The corresponding axial slice of MRT (i) ^{18}F FDG-PET (ii) and the merged co-registered scans (iii) made after 16 years of medical history. The tracer uptake of infiltrating right hemispheric tumor is elevated but does not approach the extent that was detected in 1996

ter (T/WM) and tumor-to-cortex (T/C) uptake ratios were used to substitute true ¹⁸F-FDG utilization (Table 1). The most accepted cut-off level in the differentiation of high-grade from low-grade tumors is 1.5 for T/WM and 0.6 for T/C ratios.^[2] The co-registered MRT (Shimadzu SM 100X, 1 Tesla) and PET images were merged (Register, McConnell Brain Imaging Center, Montreal Neurological Institute). The region of highest ¹⁸F-FDG uptake was defined within tumor limits (10 pixels, 2x2 mm/pixel), and isocontour ROI was drawn with an 85% cut-off value. Contralateral centrum semiovale served as an area of white matter (10 pixels). Contralateral frontal cortex was defined at the plane of the isocontour ROI (average uptake of 5 ROIs, each contains 5 pixels).

Discussion

¹⁸F-FDG-PET studies have shown good correlation between histological grade and tracer uptake that is intrinsically heterogeneous in gliomas.^[1-3] Regionally elevated tracer uptake is considered to be related to the presence of anaplasia, higher proliferation rate and cell density, hypervascularization, and inflammation.^[2-3] The temporal hypermetabolic region had been assumed to be a sign of malignant transformation but histology proved WHO Grade II. oligoastrocytoma. It occurred after a nine year long follow-up. In most cases of intracerebral tumors, resection results in decrease of seizure frequency and the regrowth often result in increase or in recurrence of previously eliminated and temporarily absent foci, suggesting that the pacemaker area is mainly represented in the tumor and/or within a close vicinity.^[4-5] There was no preserved gray matter in the removed specimen, but the overlying cerebral cortex might have acted as a pacemaker since in case of epi-

leptic activity the uptake rises because of excessive number of action potentials generated. The patient was not having seizures during the PET scans. EEG monitoring could help, but in focal seizure activity conventional scalp electrodes might not reveal spikes when the underlying tumor is expansive. In our case, after temporal resection, the seizures subsided, a fact that possibly implies that the elevated temporal ¹⁸F-FDG uptake might have been a result of continuous epileptic activity.^[6]

Acknowledgement

This work has been supported by the Mee 17/96 Grant of the University of Debrecen (Laszlo Novak) and ETT 04/605-00 and OTKA T34918 Grants (Peter Molnar).

References

1. Derlon JM, Chapon F, Noel MH, Khouri S, Benali K, Petit-Taboue MC. Non-invasive grading of oligodendrogliomas: Correlation between in vivo metabolic pattern and histopathology. *Eur J Nucl Med* 2000;7:778-87.
2. Meyer PT, Schreckenberger M, Spetzger U, Meyer GF, Sabri O, Setani KS, et al. Comparison of visual and ROI-based brain tumour grading using ¹⁸F-FDG PET: ROC analyses. *Eur J Nucl Med* 2001;2:165-74.
3. Padma MV, Said S, Jacobs M, Hwang DR, Dunigan K, Satter M, et al. Prediction of pathology and survival by FDG PET in gliomas. *J Neurooncol* 2003;64:227-37.
4. Luyken C, Blumecke I, Fimmers R, Urbach H, Elger CE, Wiestler OD, et al. The spectrum of long-term epilepsy-associated tumors: long-term seizure and tumor outcome and neurosurgical aspects. *Epilepsia* 2003;44:822-30.
5. Tandon PN, Mahapatra AK, Khosla A. Epileptic seizures in supratentorial gliomas. *Neurol India* 2001;49:55-9.
6. Meltzer CC, Adelson PD, Brenner RP, Crumrine PK, Van Cott A, Schiff DP, et al. Planned ictal FDG PET imaging for localization of extratemporal epileptic foci. *Epilepsia* 2000;2:193-200.

Accepted on 20.04.2004.