

# Spontaneous intracranial extradural hematoma: Case report and literature review

Fan Xue Zheng, You Chao

Department of Neurosurgery, West China Hospital, Sichuan University, Chengdu Sichuan, 610041, P.R. China

## Address for correspondence:

Dr. You Chao,  
Department of Neurosurgery,  
West China Hospital of Sichuan  
University, 37 Guo Xue Xiang,  
Wu Hou District,  
Chengdu - 610 041 China.  
E-mail: fxz109@sina.com

DOI: 10.4103/0028-3886.53288

## Abstract

Spontaneous extradural hematoma (EDH) is an uncommon form of intracranial hematoma and is caused by the adjacent sinus and otic infections, dural vascular malformations and disorders of blood coagulation. We report spontaneous EDH in a 54-year old women with chronic kidney disease (CKD) on intermittent hemodialysis. She was successfully managed by conservative treatment. The EDH in her was probably related to the coagulation abnormalities associated with CKD, hemodialysis or heparin use during the dialysis.

**Key words:** Extradural, hematoma, intracranial, spontaneous

## Introduction

Spontaneous extradural hematoma (EDH) is a very uncommon intracranial hematoma and is caused by adjacent infections, dural vascular malformations, tumors, disorders of blood coagulation. Till date there are 18 such documented cases in the literature.<sup>[1-16]</sup> The first documentation of spontaneous EDH was by Schneider and Hegarty in 1951.<sup>[1]</sup> We report spontaneous EDH in patient with chronic kidney disease (CKD) on intermittent hemodialysis.

## Case Report

A 54-year-old woman a known case of CKD (chronic glomerulonephritis) on intermittent haemodialysis between 2000 and 2007 was admitted for sudden onset headache associated with vomiting. Her medical history was otherwise unremarkable. There was no history any head trauma or trivial injury. On neurological examination she had mild clouding of consciousness and right side weakness (grade 3/5). Glasgow coma scale score was 12/15 (E3 V4 M5). Pupils were bilaterally reactive. Her vitals were normal. She was markedly anaemic, hemoglobin 7g/dl. Coagulation profile was: Partial thromboplastin time 32.4 s (reference range 21.8-31.5 s), a prothrombin time of 1.20 (reference range 0.75-1.19), and platelet count 100,000/mm<sup>3</sup>

(reference range 130-400,000/mm<sup>3</sup>). Blood urea nitrogen was 36mg/dl (reference range 8-22mg/dl) and serum creatinine 8.3 mg/dl (reference range 0.5-1.3 mg/dl). An urgent non-contrast CT scan showed left-sided temporoparietal EDH [Figures 1a and b].

A diagnosis of spontaneous EDH and CKD was made. The patient received a conservative management including mannitol and etamsylate. At the same time she also received transfusion of fresh frozen plasma 800 mL, cryoprecipitate 5.0 units, fibrinogen 3.0 grams and lyophilized prothombin complex concentrate (LPCC) 1400 units. A repeat CT done after 20 days showed resolving hematoma [Figure 1c] Digital

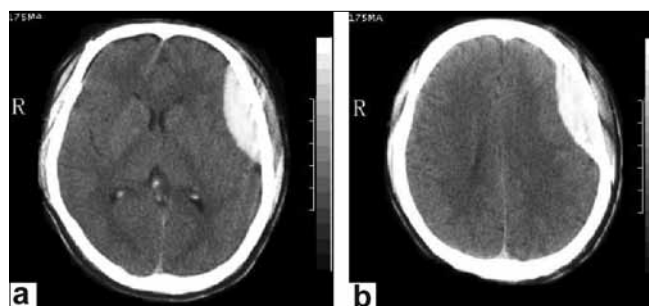


Figure 1: (a, b) Non-contrast axial head CT revealing left temporo-parietal hyperdensity. No soft-tissue swelling, fractures, or other radiographic signs of trauma are present (volume of hematoma is approximately 30 ml)

subtraction angiography (DSA) done after 25 days of the ictus to ascertain the reasons of hematoma was normal. [Figures 1e and f].

A month later, she was asymptomatic and CT scan demonstrated complete resolution of haematoma [Figure 1d]. During a 6-month follow-up, she remained well with no neurological deficit and she was being treated for CKD with intermittent haemodialysis.

## Discussion

Spontaneous EDH is an uncommon neurological emergency and requires urgent investigation and treatment. Till date including our case only 19 cases [Table 1] were documented in the literature.<sup>[1-16]</sup> Of the 18 patients documented in the literature, adjacent cranio-facial infections were the causes in 14 patients: Paranasal infection in nine (3,5,8-13), chronic otitis in four (1,2,4,6), and furuncle on the ala nasi in one (1). The proposed mechanism was intracranial spread of

the infection from the craniofacial site and the vasculitis associated with the infection, bleeding from the rupture of vasculitic vessel and subsequent expansion.<sup>[8-11]</sup> In all these, except the patients who died, hematoma was evacuated by surgery and the patients were subsequently exposed to antibiotics. In one of the patients the EDH was due to rupture of the aneurysm of middle meningeal artery proven by pre-operative cerebral angiogram. The hematoma was surgically evacuated.<sup>[6]</sup> In the patient reported by Wani *et al.*,<sup>[16]</sup> there was erosion of the vessels by the intradiploic epidermoid tumor.

Intracranial hemorrhages, intracerebral,<sup>[17]</sup> subdural,<sup>[18]</sup> and EDH<sup>[14,16]</sup> have been documented in patients with CKD and uremia. However the exact mechanism for this complication is uncertain, the possible mechanisms may be more than one. In our patient underlying vascular malformation was excluded by cerebral angiogram. Probably the coagulation abnormalities associated with uremia, heparin use during the hemodialysis or hemodialysis per se may be the factors for the EDH. In her

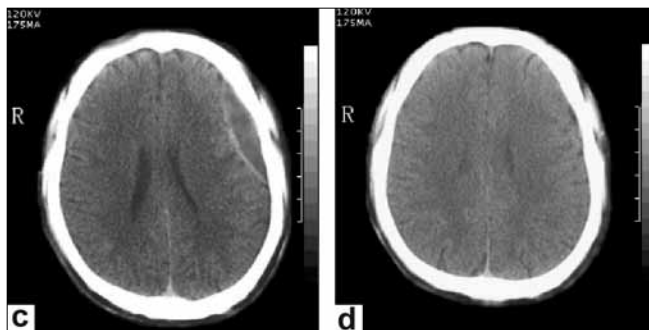


Figure 1: (c, d) Non-contrast head CT obtained after 20 days, revealing hematoma begin liquefaction and resolution and minimal decrease. Head CT after one month, revealing complete absorption of hematoma

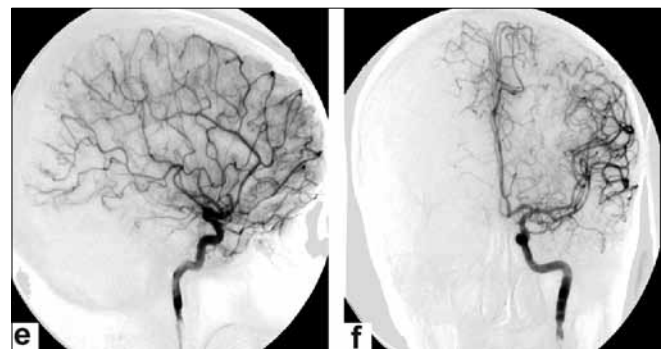


Figure 1: (e, f) An orthophoric and lateral view of left carotid angiography obtained 25 days after being admitted to hospital revealing normal extra- and intracranial vascular anatomy

Table 1: Summary of reported cases of spontaneous intracranial extradural hematoma

Author	Age/sex	Probably cause	Hematoma site	Surgery
Kelly <i>et al.</i> <sup>[3]</sup>	11/ M	Pansinusitis	Frontal	Yes
Raiput <i>et al.</i> <sup>[5]</sup>	18/ M	Maxillary sinusitis	Frontal	Yes
Marks <i>et al.</i> <sup>[7]</sup>	31/M	Pansinusitis	Frontal	Yes
Sanchis <i>et al.</i> <sup>[6]</sup>	13/M	Otitis media	Right temporal	Yes
	59/F	Aneurysm of the middle meningeal artery	Right temporal	Yes
Papadopoulos <i>et al.</i> <sup>[10]</sup>	17/M	Right frontal sinusitis	Right frontal	Yes
Ataya <sup>[8]</sup>	31/ F	Pansinusitis	Frontal	Yes
Sakamoto <i>et al.</i> <sup>[9]</sup>	16/M	Maxillary sinusitis	Frontal	Yes
Griffiths <i>et al.</i> <sup>[11]</sup>	16/M	Cleft palate with frontal sinusitis	Frontal	Yes
Moonis <i>et al.</i> <sup>[12]</sup>	21/M	Sphenoiditis	Temporal	Yes
Saisawat <i>et al.</i> <sup>[13]</sup>	14/F	Pansinusitis	Frontal	Yes
Kiarash <i>et al.</i> <sup>[14]</sup>	16/M	Uremia	Frontotemporo-parietal	Yes
Schneider <i>et al.</i> <sup>[11]</sup>	21/M	Otitis media*	Middle fossa	No
	21/M	Furuncle of ala nasi	Anterior fossa	Yes
Novaes <i>et al.</i> <sup>[2]</sup>	26/M	Otitis media	Temporal	Yes
Clein LJ <sup>[4]</sup>	18/ M	Otitis media <sup>[8]</sup>	Fronto-parietal	No
Wani AA <sup>[15]</sup>	60/M	Intradiploic epidermoid tumor	Calvarium	Yes
Shimokawa S <sup>[16]</sup>	54/M	Uraemia	Right frontoparietotemporal	Yes
Our case	54/F	CKD, uremia	Right temporal	No

\*These two patients died and hematoma was confirmed at autopsy

both the partial thromboplastin time and prothrombin time were in the upper limit of normal and platelet count was on the lower limit of the normal. However we have not done the platelet function tests. Platelet dysfunction has been documented in patients with uremia.<sup>[19]</sup> In uremia nitric oxide may inhibit platelet activation, adhesion and aggregation by activating the platelet guanylate cyclase.<sup>[20]</sup> During hemodialysis there can be changes in the serum and cerebrospinal fluid osmolality which can result in intracranial pressure fluctuations.<sup>[21]</sup> It is possible that such changes may cause vascular damage and bleeding. In uremic patients with spontaneous EDH surgery can be avoided as the mechanism of bleeding is multifactorial and the coagulation abnormality should be corrected. However surgery may be indicated if the patient has midline shifts, elevated intracranial pressure, and progressive clinical deterioration. We managed our patient conservatively as she had no evidence of midline shifts.

## References

- Schneider RC, Hegarty WM. Extradural hemorrhage as a complication of otological and rhinological infections. *Ann Otol Rhinol Laryngol* 1951;60:197-206.
- Novaes V, Gorbitz C. Extradural hematoma complicating middle ear infection: Report of a case. *J Neurosurg* 1965;23:352-3.
- Kelly DL Jr, Smith JM. Epidural hematoma secondary to frontal sinusitis: Case report. *J Neurosurg* 1968;28:67-9.
- Clein LJ. Extradural haematoma associated with middle ear infection. *Can Med Assoc J* 1970;102:1183-4.
- Rajput AJ, Rozdilsky B. Extradural hematoma following frontal sinusitis: Report of a case and review of the literature. *Arch Otolaryngol* 1971;94:83-6.
- Sanchis JF, Orozco M, Cabanes J. Spontaneous extradural haematomas. *J Neurol Neurosurg Psychiatry* 1975;38:577-80.
- Marks SM, Shaw MD. Spontaneous intracranial extradural hematoma. *J Neurosurg* 1982;57:708-9.
- Ataya NL. Extradural haematoma secondary to chronic sinusitis: A case report. *J Laryngol Otol* 1986;100:951-3.
- Sakamoto T, Harimoto K, Inoue S, Konishi A. Extradural hematoma following maxillary sinusitis: Case illustration. *J Neurosurg* 1997;87:132.
- Papadopoulos MC, Dyer A, Hardwidge C. Spontaneous extradural haematoma with sinusitis. *J R Soc Med* 2001;94:588-9.
- Griffiths SJ, Jatavallabhula NS, Mitchell RD. Spontaneous extradural haematoma associated with craniofacial infections: Case report and review of the literature. *Br J Neurosurg* 2002;16:188-91.
- Moonis G, Granados A, Simon SL. Epidural hematoma as a complication of sphenoid sinusitis and epidural abscess: A case report and literature review. *Clin Imaging* 2002;26:382-5.
- Chaiyasate S, Halewyek S, Van Rompaey K, Clement P. Spontaneous extradural hematoma as a presentation of sinusitis: Case report and literature review. *Int J Pediatr Otorhinolaryngol* 2007;71:827-30.
- Shahlaie K, Fox A, Butani L, Boggan JE. Spontaneous epidural hemorrhage in chronic renal failure: A case report and review. *Pediatr Nephrol* 2004;19:1168-72.
- Wani AA, Ramzan AU, Kirmani AR, Bhatt AR, Hamdani N, Zargar J. Intradiploic epidermoid causing spontaneous extradural hematoma: Case report. *Neurosurgery* 2008;62:971.
- Shimokawa S, Hayashi T, Anegawa S, Nakashima S, Tsutsumi K, Nakagawa S, *et al.* Spontaneous epidural hematoma in a patient undergoing hemodialysis: A case report. *No To Shinkei* 2003;55:163-6.
- Aguilar MI, Hart RG, Kase CS, Freeman WD, Hoebe BJ, Garcia RC, *et al.* Treatment of warfarin-associated intracerebral hemorrhage: Literature review and expert opinion. *Mayo Clin Proc* 2007;82:82-92.
- Leonard A, Shapiro FL. Subdural hematoma in regularly hemodialyzed patients. *Ann Intern Med* 1975;82:650-8.
- Sung J, Hsieh CC, Yu CY, Huang JJ. Acute spontaneous spinal epidural hematoma in a hemodialysis patient with a bleeding tendency. *Nephron* 2002;91:358-60.
- Boecardo P, Remuzzi G, Galbusera M. Platelet dysfunction in renal failure. *Semin Thromb Hemost* 2004;30:579-89.
- Kurokawa Y, Suzuki S, Hashi K, Ueda T, Matsumura S, Kawahara T, *et al.* Elevation of intracranial pressure during hemodialysis-continuous measurement of cerebrospinal fluid pressure in a patient with acoustic neurinoma. *No To Shinkei* 1990;42:569-73.

Accepted on 24-01-2009

Source of Support: Nil, Conflict of Interest: None declared.