

Simultaneous posterior and middle cerebral artery infarct

Sir,

Willis polygon supplies blood to the brain by combining the circulation of the two hemispheres through the anterior communicating artery (ACoA) and by combining the anterior and posterior circulations through posterior communicating artery (PCoA). This system is of "normal" configuration in 25-52% of the population, in the rest there are several variations.^[1] Among the common variations are fetal posterior cerebral arteries (fPCA), hypoplastic anterior cerebral artery (ACA) or absent A1 segment and hypoplastic PCoA. These variations may present an increased stroke risk or may cause infarctions in an unexpected arterial tertiary.^[2] In this report we present a patient with left-sided hemiplegia with infarctions in the arterial tertiary of right middle and posterior cerebral arteries.

A 77-year-old right-handed female patient was referred to our department for left-sided weakness. She had been using warfarin for atrial fibrillation (AF) until a planned operation for right humerus fracture when her anticoagulation treatment was stopped. At the initial neurological examination she was obtunded and was not much co-operative. She tried to open her eyes to verbal stimuli. The eyes were deviated to the right side and she had a left-sided hemiparesis.

Complete blood count, liver and renal function tests were unremarkable except for hyperglycemia. Atrial fibrillation could be seen in the electrocardiogram. The initial cranial computed tomography (CT) was normal [Figure 1a]. CT done two days later, showed simultaneous infarcts in the right middle cerebral artery (MCA) and right posterior cerebral artery (PCA) territories [Figure 1b]. Digital subtraction angiography did not reveal any occluded or stenosed segments but a fetal PCA [Figure 1c]. Anticoagulation with warfarin was restarted and she was

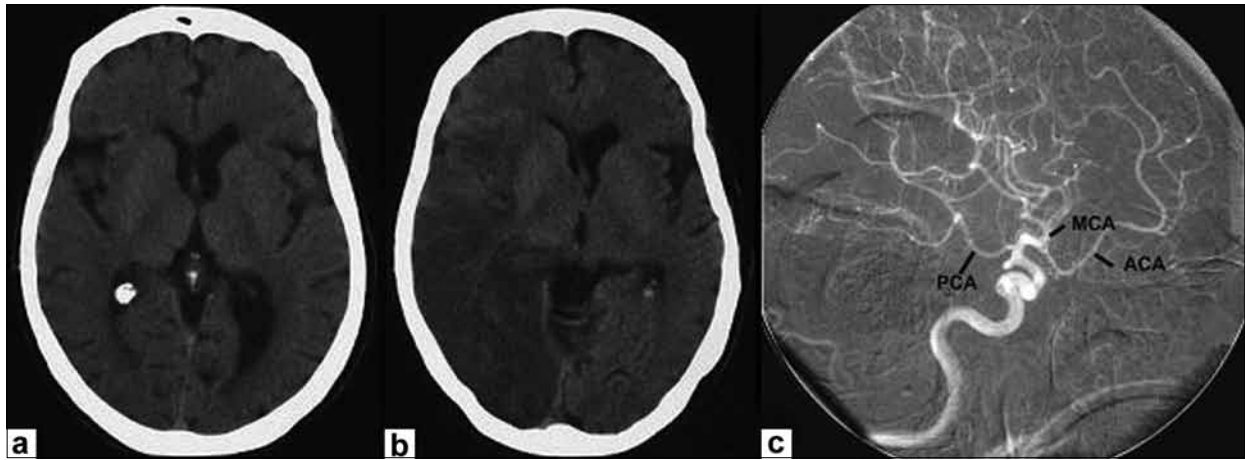


Figure 1: (a) Normal initial CT of the patient; (b) The cranial CT two days after the incident shows signal changes consistent with simultaneous infarcts in the right MCA and PCA areas; (c) In the digital subtraction angiography of the right ICA, PCA is seen to originate from the right ICA through PCoA i.e. fetal type PCA

followed with in-patient rehabilitation.

Fetal PCA, when present, originates from the internal carotid artery (ICA) and it is supplied by the carotid system rather than the vertebro-basillary system. Fetal type posterior (FTP) circulation variation has been reported in 3-36% in the literature. Three types have been described: Transitional configuration, partial FTP and full FTP. In FTP, leptomeningeal collaterals cannot provide the PCA-MCA connection, as the tentorium prevents the connection of cerebellar vessels with the PCA.^[2]

Simultaneous occurrence of MCA and PCA infarction is rarely reported in the literature. Yang *et al.*,^[3] found 21 patients with infarction in the ipsilateral PCA and ICA territories in 1388 stroke patients (1.5%). Sixteen of those 21 patients (76%) demonstrated steno-occlusive lesions of the relevant ICA. Cardioembolic sources were rarely found. All but one patient with fetal PCA or the PCoA demonstrated significant ICA stenosis.^[3] In the two cases reported by Raamt, the PCA and MCA territories were affected, similar to our patient.^[2] In patients with simultaneous infarction of the MCA and PCA, the occlusion of ICA may explain this concomitance. Furthermore, when the ICA is occluded, fetal PCA may cause greater than expected infarcts. Probably due to recanalization, no ICA occlusion could be shown in our patient.

To conclude, although rare, concurrent MCA and PCA infarcts can be seen in clinical practice. In such cases, the eventual condition is usually due to an underlying ICA occlusion. Lastly, if fetal PCA also accompanies, the infarction area may be much more wide spread.

**Mehmet Güney Şenol, Murat Velioğlu¹,
Erdem Toğrol, Fatih Özdağ, Mehmet Saraçoğlu**

Department of Neurology, ¹Radiology, Gülhane Military Medical
Academy, Haydarpaşa Training Hospital, İstanbul, Turkey.
E-mail: mgsenol@yahoo.com

PMID: 19934576

DOI: 10.4103/0028-3886.57793

References

1. Sandhu JS, Wakhloo AK. Neuroangiographic anatomy and common cerebrovascular diseases. In: Bradley WG, Daroff RB, Fenichel GM, Jankovic J, editors. Neurology in clinical practice. Principles of diagnosis and management. 4th ed. Philadelphia PA: Butterworth Heinemann; 2004. p. 625-43.
2. van Raamt AF, Mali WP, van Laar PJ, van der Graaf Y. The fetal variant of the circle of Willis and its influence on the cerebral collateral circulation. Cerebrovasc Dis 2006;22:217-24.
3. Yang JH, Choi HY, Nam HS, Kim SH, Han SW, Heo JH. Mechanism of infarction involving ipsilateral carotid and posterior cerebral artery territories. Cerebrovasc Dis 2007;24:445-51.

Accepted on 10-01-2009