

Pericardial Effusion and Atrial Thrombosis: A Rare Complication of Childhood Leukemia

Soheila Zareifar¹, MD; Sirous Cheriki², MD; Maral Namdari¹, MD;
Mohammadreza Farahmandfar¹, MD, and Ahmad Jannati³, MD

1. Hematology Research Center, Shiraz University of Medical Sciences, Shiraz, Iran
2. Department of Pediatrics, Shiraz University of Medical Sciences, Shiraz, Iran
3. Cardiac Department, Shiraz University of Medical Sciences, Shiraz, Iran

Received: Sep 15, 2010; Final Revision: May 17, 2011; Accepted: Jul 19, 2011

Abstract

Background: Acute lymphoblastic leukemia (ALL) is the most common malignancy diagnosed in children. Extramedullary leukemia including hepatosplenomegaly, lymphadenopathy, and mediastinal mass are the clinical presentations of T-cell ALL. Pericardial effusion and atrial mass are rare presentations of pediatric leukemia.

Case Presentation: We report a 15-year-old girl with T-cell ALL, who presented initially with pericardial effusion and cardiac tamponade and subsequently developed right atrial mass. The mediastinal and right atrial masses were excised by surgical procedure as a treatment strategy for prevention of arrhythmia and sudden death.

Conclusion: T-cell ALL can present with pericardial and mediastinal involvement as an initial manifestation. Pericardiocentesis and systemic anticancer chemotherapy without local chemotherapy should be considered in these cases.

Iranian Journal of Pediatrics, Volume 22 (Number 1), March 2012, Pages: 117-120

Key Words: Acute Lymphoblastic Leukemia; Extramedullary Leukemia; Pericardial Effusion; Atrial Mass

Introduction

T-cell acute lymphoblastic leukemia (T-ALL) accounts for ~10%-15% of the newly diagnosed cases of childhood ALL. This subtype is associated with high initial WBC count, older age at presentation, and presence of extramedullary disease. Historically, T-cell ALL patients have had a worse prognosis than other ALL patients^[1].

Childhood T-cell leukemia/lymphoma has a wide variety of clinical presentations including extramedullary leukemia. The most common signs of extramedullary leukemia in children with T-cell ALL are hepatosplenomegaly, lymphadenopathy, and skin lesions. Although a common finding at autopsy, clinically evident pericardial effusion is rare complication in pediatric leukemia. Pleural and pericardial effusions, cardiac tamponade as an

* Corresponding Author;

Address: Hematology Research Center, Shiraz University of Medical Sciences, Shiraz, Iran

E-mail: zareifars@sums.ac.ir

initial manifestation in T-cell ALL and antedate hematological evidence of leukemia are extremely rare and it may be a severe complication of leukemia^[2]. This complication often develops during the radiation therapy, chemotherapy, or infections in the course of leukemia. However, some cases may present initially with pericardial effusion and tamponade and physician's awareness is important to make a correct diagnosis and undertake appropriate treatment strategies^[3,4]. In this case report we present a young girl with initially pericardial effusion and cardiac tamponade and subsequently developed right atrial mass.

Case Presentation

A 15-year-old girl was admitted to the hospital with one month history of cough, sputum, pleuritic chest pain and progressive dyspnea. She received antibiotics without improvement and after 2 weeks her symptoms aggravated; she developed chest pain and difficulty in respiration. In her past medical history, there was no significant history of recurrent infection. On admission, the patient was well developed and nourished, afebrile (36.5°C axillary), tachycardic with a pulse rate of 120 beats/min and tachypneic with respiratory rate of 30 breaths/min. She was hypotensive with blood pressure 80/60 mmHg and orthostatic changes. Cardiovascular examination was significant for jugular venous pulsations (JVP) at 6 cm, pulsus paradoxus, pericardial friction rub, and diminished heart sounds. Pulmonary examination revealed decreased breathing sounds bilaterally with dullness to percussion at the lung base. There was moderate hepatomegaly (liver was palpable 3 cm below the costal margin) with trace bipedal pitting edema.

Hematological data showed: hemoglobin 14.5 gr/dl, platelet count $202 \times 10^3/\mu\text{L}$ and WBC $19.1 \times 10^3/\mu\text{L}$ with lymphocyte dominance (77% lymphocyte, 20% neutrophil, 3% monocyte). In the peripheral blood smear, 40% lymphoblast was seen. Biochemistry showed albumin 3.5 g/dl, globulin 1.8 g/dl, and lactic acid dehydrogenase

877 U/L (normal range= 90 to 310 U/L). Liver and renal functions, coagulation screen tests and blood sugar were all within normal limits. Tests for HBsAg, anti-HCV Ab, anti-HIV Ab, and EBV antiscapid IgM were negative.

Bone marrow aspiration and trephine biopsy was hypercellular with 90% blasts, erythroid and myeloid maturation arrest and no evidence of megakaryopoiesis which were sudan black and myeloperoxidase negative. Bone marrow immunophenotypic examination was positive for CD3 and CD7, but negative for CD10, CD19, CD20, and HLA DR, in favor of T-cell type of ALL-L2.

The electrocardiogram revealed diffuse low voltage QRS complexes with sinus tachycardia at 120/min. Chest radiograph revealed bilateral pleural effusions and an enlarged cardiac silhouette, suspicious to wide mediastinum. Echocardiogram showed a large pericardial effusion with diastolic collapse of the right atrium and ventricle consistent with pericardial tamponade. Pig tail catheter was inserted in the pericardium and pericardial fluid was drained and 15 ml of serosanguineous pericardial fluid was sent for cytology which was negative for malignancy. Due to persistent pericardial effusion, pericardial window was opened and biopsy was taken from the pericardium, revealing mild chronic inflammation and fibrosis.

Diagnostic plurocentesis was done and a transudate fluid was aspirated that was negative for malignancy in cytology report. The patient was treated as a case of T-cell ALL according to Lanzkowsky protocol (4th edition, 2005). One week after starting chemotherapy, when she had taken one dose of vincristin, daunomycin, methotrexate, and corticosteroid, the patient developed severe chest pain and excessive sweating. New chest radiography showed a wide mediastinum. In spiral computed tomography (CT) of chest an anterior mediastinal mass with some enhancing area and pressure effect on the superior vena cava was detected (Fig. 1). Trans-thoracic echocardiography showed two large masses in the right atrium and moderate tricuspid regurgitation (Fig. 2). Right bundle branch block and non-specific ST segment elevation in electrocardiogram were detected.

Mediastinotomy was done. A huge mass in the anterior mediastinum ($10 \times 8 \times 5$ cm), with severe

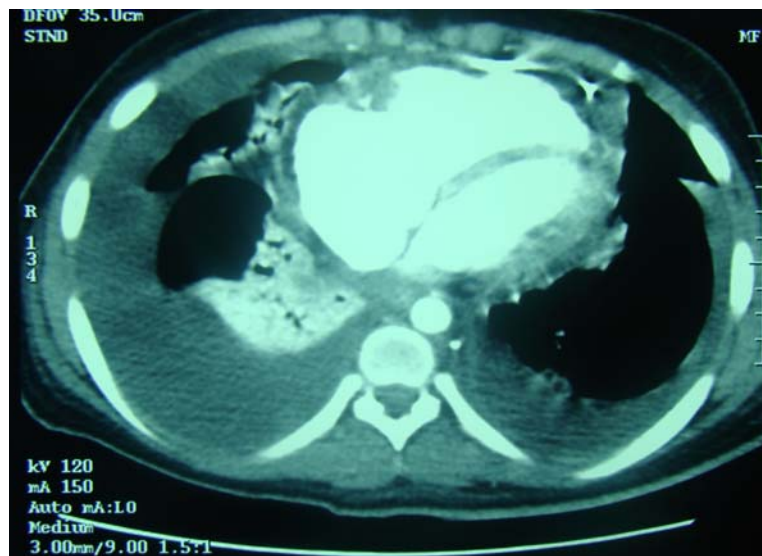

Fig. 1: Chest CT scan with contrast revealed large amount of pericardial effusion and anterior mediastinal mass

adhesion to the aorta, very thick pericardium and inflammation between the pericardium and myocardium and two large right atrial masses (6.2, 2.5 cm) were seen. Surgical excision of the mediastinal and right atrial masses was performed and epicardial temporary pace was fixed for prevention of arrhythmia and sudden death.

Histologic sections revealed necrotic thrombus in the right atrial lesions and chronic mediastinitis in the mediastinal mass. No evidence of

malignancy was seen which was due to chemotherapy effect. All workups for thrombosis risk factors were negative including: ANA, dsDNA, ACLA, P-ANCA, C-ANCA, factor five Leiden, and thrombin 20210 mutations. The levels of C3, C4, CH50, protein C, S and anti-thrombin III were also in normal ranges.

We continued chemotherapy and the patient had no evidence of disease or cardiac problem 1.5 years after the presentation.

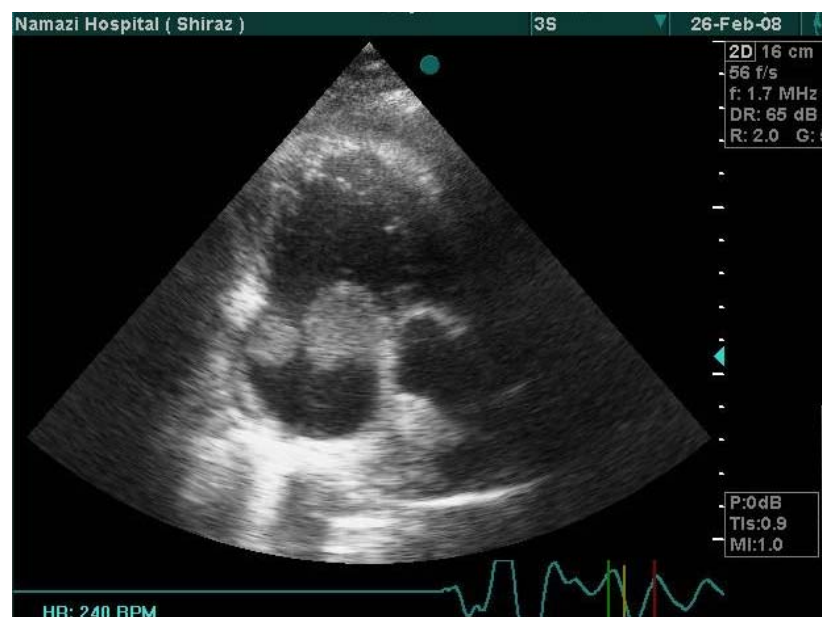


Fig. 2: Two large thromboses in right atrium in four chamber view of echocardiography

Discussion

Pericardial effusion in leukemia patients may be caused by any of the following conditions: infection, cell infiltration with (or without) extramedullary hematopoiesis, and other effects of anti-leukemia drugs [5,6]. Infiltration of the pericardium with effusion should, therefore, be considered in every patient with leukemia, for both therapeutic and prognostic reasons. Imaging examinations including echocardiography, chest radiography, computed tomography (CT) scan, magnetic resonance imaging (MRI), and radioisotope scan are the best methods for initial diagnosis. However, the final diagnosis is made by pathology, such as tissue biopsy and cytologic examination of the effusive fluid [6].

In our patient, we inserted pericardial tube drainage without any instrumentation or manipulation of the heart chambers or great vessels, and used only a few doses of systemic anticancer chemotherapy. Subsequently, she developed right atrial thrombosis without any risk factor for thrombus formation. Generally, thrombus formation is less common in the right compared to the left atrium. It occurs in association with in-dwelling catheters, especially at the junction of the superior vena cava and right atrium and in patients with atrial fibrillation or prothrombotic states[7]. This case was unusual because the patient lacked all the common clinical features of childhood T-cell ALL. She did not have two major predisposing factors for right atrial thrombus formation including stasis and in-dwelling catheter. We present this case so as to increase awareness that childhood T-cell ALL could initially present with pericardial effusion, and thrombosis may occur in patients with malignancy without any obvious cause.

Conclusion

It is emphasized that T-cell ALL can present with pericardial and mediastinal involvement as an

initial manifestation. We also suggest that such patients could be treated with pericardiocentesis and systemic anticancer chemotherapy without local chemotherapy.

Acknowledgement

Our special thanks to Dr. N. Shokrpour for the linguistic editing of the manuscript.

Conflict of interest: There are no conflicts of interest.

References

1. Goldberg JM, Silverman LB, Levy DE, et al. Childhood T-cell acute lymphoblastic leukemia: The Dana-Farber Cancer Institute Acute Lymphoblastic Leukemia Consortium Experience. *J Clin Oncol* 2003;21(19):3616-22.
2. Chves FP, Quillen K, Dongsheng XU. Pericardial effusion: A rare presentation of adult T-cell leukemia/lymphoma. *Am J Hematol* 2004;77(4):381-3.
3. Handra R, Bhatia S, Wali JP, et al. Acute leukemia presenting as pericardial effusion: A case report. *Singapore Med J* 1997;38(11):491-2.
4. Söğüt A, Yilmaz K, Yalman N, et al. A case with acute leukemia presenting with cardiac tamponade. *Turk J Pediatr* 1999;4(4):509-16.
5. Bradford CR, Smith SR, Wallis JP. Pericardial extramedullary haemopoiesis in chronic myelomonocytic leukaemia. *J Clin Pathol* 1993;46(7):674-5.
6. Sarjeant JM, Butany J, Cusimano RJ. Cancer of the heart: epidemiology and management of primary tumors and metastases. *Am J Cardiol* 2003;3(6):407-21.
7. de Divitis M, Omran H, Rabahieh R, et al. Right atrial appendage thrombosis in atrial fibrillation: its frequency and its clinical predictors. *Am J Cardiol* 1999;84(9):1023-8.