

Interstitial Lung Disease in a Patient with Chronic Granulomatous Disease

Mozhgan Moghtaderi^{*1,2}, MD; Sara Kashef, MD^{1,2}, and Nima Rezaei, MD, PhD^{3,4}

1. Allergy Research Center, Shiraz University of Medical Sciences, Shiraz, Iran
2. Department of Pediatrics, Division of Immunology and Allergy, Shiraz University of Medical Sciences, Shiraz, Iran
3. Research Group for Immunodeficiencies, Children's Medical Center, Tehran University of Medical Sciences, Tehran, Iran
4. Molecular Immunology Research Center; and Department of Immunology, Tehran University of Medical Sciences, Tehran, Iran

Received: Oct 27, 2010; Final Revision: Dec 29, 2010; Accepted: Mar 03, 2011

Abstract

Background: Chronic granulomatous disease (CGD) is an inherited phagocytes defect, characterized by defects of NADPH-oxidase and inability of bacterial killing, which leads to recurrent life-threatening infections. Respiratory problems, which are the major cause of morbidity in CGD, usually result from recurrent severe infections; however, vigorous inflammatory response could also cause respiratory diseases.

Case Presentation: Herein, an 11 year-old patient with CGD is presented who suffered from chronic cough and dyspnea for 7 years. Considering the results of chest X-ray, high-resolution computed tomography, and pulmonary function test, the diagnosis of interstitial lung disease was made.

Conclusion: Early recognition of manifestations associated with CGD and appropriate treatment could prevent further complications and reduce morbidity and mortality in this group of patients.

Iranian Journal of Pediatrics, Volume 22 (Number 1), March 2012, Pages: 129-132

Key Words: Chronic Granulomatous Disease; Interstitial Lung Disease; Immunodeficiency

Introduction

Chronic granulomatous disease (CGD) is a rare primary immunodeficiency disorder, which is caused by defects in superoxide generation and phagocytes function. Subsequent defect of bacterial killing leads to cytokine release and inflammation of different organs in the patients with CGD [1-3].

Involvement of respiratory system is one of the main characteristics of patients with CGD. The majority of CGD patients suffer from

respiratory disease, including pneumonia, lung abscess, and pulmonary fibrosis. Interstitial lung disease (ILD) is a rare pulmonary condition in this group of patients which causes derangements of the alveolar walls and loss of functional alveolar capillary units leading to restrictive lung disease. Typical features of ILD include the presence of diffuse infiltrates on chest radiograph, and abnormal pulmonary function test (PFT) with evidence of a restrictive defect and/or impaired gas exchange [4]. Exposure-related ILD, systemic disease-associated ILD, alveolar structure disorder-

*** Corresponding Author;**

Address: Allergy Research Center, Shiraz University of Medical Sciences, Post code: 71937-11351, Shiraz, Iran

E-mail: moghtaderi@sums.ac.ir

© 2012 by Pediatrics Center of Excellence, Children's Medical Center, Tehran University of Medical Sciences, All rights reserved.

associated ILD, and idiopathic ILD in older children are generally considered as the main causes of ILD in children [5]. ILD could be as a result of recurrent life-threatening infections, whereas non-infectious inflammation could also be responsible for such lung disease.

Herein, we present a CGD child complicated with ILD.

Case Presentation

An 11 year-old boy was diagnosed with CGD in infancy, following severe recurrent lower respiratory tract infections. There was no history of primary immunodeficiency disease in his family.

The patient gradually developed hypoxia, dyspnea on exertion, cyanosis and became worse during childhood. There were some evidences of repeated pneumonia and consequently using intravenous antibiotics in his past medical history. At the time of his admission to our clinic, he had not fever, but physical examination revealed tachypnea, crackles, retraction, and increased anteroposterior diameter of chest. Laboratory findings, including complete cell blood count (CBC), ESR, liver function test, sweat chloride test and serum immunoglobulin levels were normal. Arterial

blood gas (ABG) analysis showed: pH 7.28, O₂ saturation 64.7% and PCO₂ 54.3 mmHg. Blood cultures and tracheobronchial secretion cultures for pyogenic, fungal and mycobacterial infections were negative. Polymerase chain reaction (PCR) for *Aspergillus* and *Candida albicans* was negative. Diagnostic bronchoalveolar lavage (BAL) was performed to obtain specimens for cytology and culture. The smear of BAL showed many isolated bronchial epithelial cells accompanied with few inflammatory cells.

Nitroblue-tetrazolium (NBT) dye test was defective. The result was compatible with diagnosis of CGD, which was also further confirmed by dihydro rhodamine123 (DHR) dye test.

Serial plain chest X-rays showed increased vascular and interstitial markings. The Result of high-resolution computed tomography (HRCT) scan revealed ground glass appearance in both lung fields with some areas of decreased attenuation, honeycombing, asymmetric emphysematous change and increased interstitial marking, which was compatible with diagnosis of interstitial lung disease (Fig. 1).

In PFT, forced expiratory volume in 1 second (FEV1) was decreased to 38.7%; residual volume (RV) and total lung capacity were increased to 773.2% and 203.8%, respectively. The result of PFT was air trapping and high airway resistance in favor of restrictive pattern and destructive lung disease.

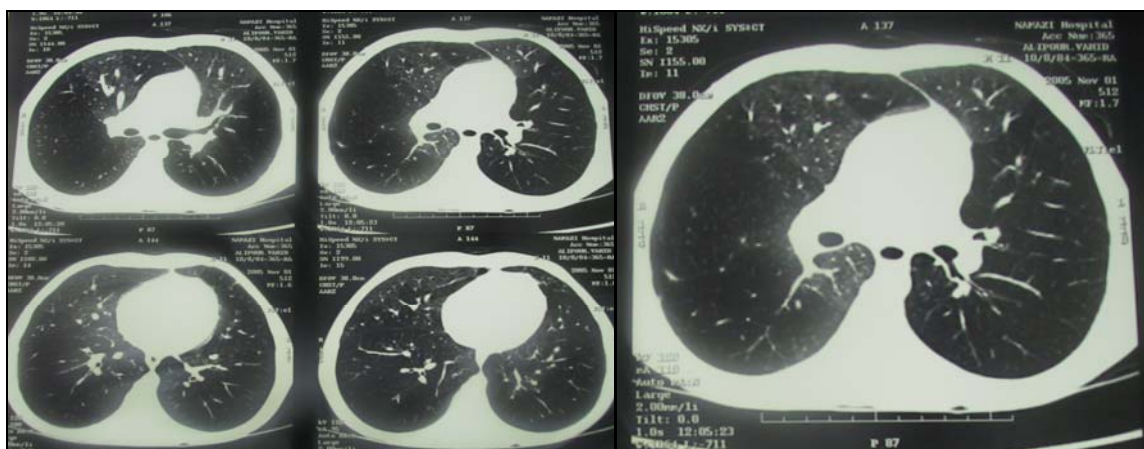


Figure1: High resolution CT scan of the patient revealed ground glass appearance and emphysematous change

Echocardiography revealed normal systolic and diastolic function without pulmonary hypertension. For excluding systemic disease-associated interstitial lung diseases, IgM rheumatoid factor, serum antinuclear antibodies reactive to nuclear (ANA), cytoplasmic antigens, anti smooth muscle antibody as well as serum angiotensin-converting enzyme level were measured, which were all normal.

After considering ILD in the patient, prednisolon therapy was initiated at a dose of 1 mg/kg/day associated with hydroxychloroquine. At the time of discharge, 30 days after admission, clinical respiratory findings such as cough and dyspnea subsided. After a 3-month course of prednisolone and tapering the dosage, an increased oxygenation at rest and sleep was achieved. Such treatment leads to improvement of pulmonary disease in the patient.

Discussion

Chronic granulomatous disease (CGD) is an inherited immunodeficiency disease, which is generally considered as a rare disease, but its frequency, especially its autosomal recessive form, seems to be much higher in the regions with high rate of consanguinity [6-8]. Although several organs could be affected in CGD, the most common site of involvement is lung [3,6].

ILD is characterized by thickening of the alveolar walls by a wide spectrum of inflammatory cells, immunoregulatory cells and/or fibrosis, accompanied by loss of functional alveolar capillary unit [5]. Diagnostic procedures could be used to detect ILD, including chest X-ray, HRCT, bronchoalveolar lavage, PFT, and sometimes thorascopic lung biopsy[9].

Etiology of ILD encompasses a group of known and unknown disorders in children, but infections account for many cases of known etiologies. After considering ILD, an etiological diagnostic approach is required. A careful history and serum levels of antibodies is needed

for eliminating exposure-related ILD and systemic disease-associated ILD, respectively. Among disorders affecting the alveolar epithelium and the alveolar space, viral infections is mainly suggested in pathogenesis of ILD[10]. In CGD patients, microorganisms can be protected from intracellular killing, which consequently leads to leukocyte accumulation, cytokine release and inflammation[11]. In spite of the fact that laboratory findings and BAL specimens revealed no sign of bacterial, mycobacterial, and fungal infection, there was no further adequate facilities for diagnosis of respiratory viral infections in the patient.

Idiopathic ILD with unknown etiology may be seen even in CGD, but the reason for non-infectious inflammation remains mostly elusive.

Recent studies demonstrated that genes encoding polymorphonuclear cells in CGD patients have an increased expression of pro-inflammatory molecules and decreased anti-inflammation mediators. Key regulators of apoptosis, inflammation and host defense were differentially expressed in the absence or presence of reactive oxygen species, respectively [12]. Although CGD patients have increased susceptibility to infections, a higher incidence of sterile inflammatory disorders in these patients has also been noted.

Although a favorable response to corticosteroid therapy can be expected in about 50% of cases, significant sequels such as need for long-term oxygen therapy are often observed[13].

Conclusion

In this report, a rare complication of ILD in a child with CGD has been reported which could be resulted as of either viral or non-infectious etiology. Early diagnosis of lung disease in an immunodeficient patient and appropriate management can prevent further complications, such as pulmonary fibrosis in this group of patients.

Acknowledgments

We thank A Emad, M Rasouli and the center for development of clinical studies, Nemazee Hospital, because of their kind assistance.

References

1. Roesler J, Koch A, Porkzen G, et al. Benefit assessment of preventive medical check-ups in patients suffering from CGD. *J Eval Clin Practice* 2005;11(6):513-21.
2. Winkelstein JA, Marino MC, Johnston RB, Jr., et al. Chronic granulomatous disease. Report on a national registry of 368 patients. *Medicine (Baltimore)* 2000;79(3):155-69.
3. Movahedi M, Aghamohammadi A, Rezaei N, et al. Chronic granulomatous disease: a clinical survey of 41 patients from the Iranian primary immunodeficiency registry. *Int Arch Allergy Immunol* 2004;134(3):253-9.
4. Fan LL, Kozinetz CA. Factors influencing survival in children with chronic interstitial lung disease. *Am J Respir Crit Care Med* 1997; 156(3 Pt 1):939-42.
5. Clement A, Nathan N, Epaud R, et al. Interstitial lung diseases in children. *Orphanet J Rare Dis* 2010;20:5-22.
6. Rezaei N, Aghamohammadi A, Moin M, et al. Frequency and clinical manifestations of patients with primary immunodeficiency disorders in Iran: update from the Iranian Primary Immunodeficiency Registry. *J Clin Immunol* 2006;26(6):519-32.
7. Rezaei N, Pourpak Z, Aghamohammadi A, et al. Consanguinity in primary immunodeficiency disorders; the report from Iranian Primary Immunodeficiency Registry. *Am J Reprod Immunol* 2006;56(2):145-51.
8. Aghamohammadi A, Moin M, Rezaei N. History of primary immunodeficiency diseases in Iran. *Iran J Pediatr* 2010;20(1):16-34.
9. Ostojic P, Cerinic MM, Silver R, et al. Interstitial lung disease in systemic sclerosis. *Lung* 2007; 185(4):211-20.
10. Vannella KM, Moore BB. Viruses as co-factors for the initiation or exacerbation of lung fibrosis. *Fibrogen Tissue Repair* 2008;1(1):2.
11. Segal BH, Leto TL, Gallin JI, et al. Genetic, biochemical, and clinical features of chronic granulomatous disease. *Medicine (Baltimore)* 2000;79(3):170-200.
12. Kobayashi SD, Voyich JM, Braughton KR, et al. Gene expression profiling provides insight into the pathophysiology of chronic granulomatous disease. *J Immunol* 2004;172(1): 636-43.
13. Fan LL, Deterding RR, Langston C. Pediatric interstitial lung disease revisited. *Pediatr Pulmonol* 2004;38(5):369-78.