

Paragonimiasis in Chinese Children: 58 Cases Analysis

Hong Zhen Xu, MN; Lan Fang Tang*, MD, PhD; Xiao Ping Zheng, MN, and Zhi Min Chen, MD, PhD

Department of Pulmonology, The Children's Hospital of Zhejiang University School of Medicine and the Key Laboratory of Reproductive Genetics (Zhejiang University), Ministry of Education, China

Received: Jun 07, 2011; Final Revision: Apr 18, 2012; Accepted: Apr 25, 2012

Abstract

Objective: To analyze the clinical and radiological features of paragonimiasis in children and raise the awareness of this disease.

Methods: A total of 58 paragonimiasis patients were reviewed. They were 42 boys and 16 girls aged 2.0 to 15.3 years.

Findings: Among these patients, 20 were diagnosed in the recent 5 years, 46 with a history of raw water or food ingestion. Except 2 patients without any complaint, the most common features involved the systemic (41, 70.7%) and respiratory systems (43, 74.1%), followed by abdominal, cardiac and nervous systems, with rash and mass. Eosinophilia was noted in 46 (79.3%) patients, granulocytosis in 45 (77.6%), anemia in 14 (24.1%), and thrombocytopenia in 3. Imageology showed pneumonia in 26 (44.8%) patients, pleurisy in 28 (48.3%), hydropericardium in 17 (29.3%), ascites in 16 (27.6%), and celiac lymphadenitis in 13 (22.4%). Besides hepatomegaly and splenomegaly, calcification and multiple lamellar low echogenic areas in the liver were noted, each in one patient. Abnormal brain imaging was noted in 4 of 10 patients. Karyocyte hyperplasia with eosinophilia was noted in all the 19 patients who received bone marrow puncture.

Conclusion: Paragonimiasis should be considered in the differential diagnosis of patients with multiple organs or system lesions, especially those with eosinophilia, serous cavity effusion, respiratory, cardiac, digestive system, nervous system abnormality, and/or mass. Healthy eating habit is helpful for paragonimiasis prevention.

Iranian Journal of Pediatrics, Volume 22 (Number 4), December 2012, Pages: 505-511

Key Words: Paragonimiasis; Paragonimus; Metacercariae; Eosinophilia; China

Introduction

Paragonimiasis, also known as lung fluke disease, is a parasitic disease in humans and other mammals caused by infection with *Paragonimus spp*^[1-3]. Human infection often occurs by ingestion of infectious *Paragonimus metacercariae* in freshwater crab or crayfishes^[4]. Therefore, the disease is common and limited to areas where the people habitually take raw or undercooked water

or food, including such Asian countries as China, Korea, Japan, Lao PDR and Philippines, some part of Latin America and Africa^[1,4-7]. Zhejiang province, located on the eastern coast of China, is known to be a paragonimiasis endemic area.

The *Paragonimus metacercariae* exist in the small intestine, and pass through the intestinal wall, peritoneal cavity, diaphragm, and pleural cavity, and finally enter the lung parenchyma, where they mature into adults^[2-5]. Infrequently,

* Corresponding Author;

Address: Children's Hospital of Zhejiang University School of Medicine, 57 Zhugan Xiang, Hangzhou 310003, China

E-mail: tlf119100@sina.com.cn

© 2012 by Pediatrics Center of Excellence, Children's Medical Center, Tehran University of Medical Sciences, All rights reserved.

the metacercariae migrate to some other tissues, such as the liver, neck, brain and fossa orbitalis, which is named extrapulmonary paragonimiasis^[8,9]. The classic symptoms of pulmonary paragonimiasis include a chronic cough with rusty-brown sputum, hemoptysis, pleurisy, and fever with radiographic findings of patchy density, linear infiltration, nodules, pleural effusion and pulmonary cavities^[5,10]. It was reported to be more prevalent in middle-aged patients, frequently with nodular lesions on chest radiography. However, paragonimiasis has been rarely reported in children and usually misdiagnosed as rheumatopyra, pulmonary tuberculosis, pneumonia, liver abscess, or meningitis^[11,12]. Herein, we retrospectively reviewed the pediatric patients with paragonimiasis diagnosed in our hospital to summarize the clinical features and raise awareness of this disease.

Subjects and Methods

A total of 58 patients diagnosed with paragonimiasis in our hospital from 2000 to 2009 were enrolled. They were 42 boys and 16 girls aged 2.0 to 15.3 years with a mean age of 6.48 ± 3.01 years. The diagnoses were based on positive serologic test results for *Paragonimus*-specific antibody, or the detection of characteristic *Paragonimus* eggs in sputum.

The medical records were reviewed for information related to the clinical data of the patients, including age, gender, history of ingestion of raw or undercooked freshwater crab or crayfishes, symptoms, duration of symptoms, laboratory tests, chest radiographs, complications and therapy.

Findings

Clinical features

Among the 58 patients, 46 (79.3%) admitted a history of raw water or food ingestion. The first complaint included fever in 17 (29.3%) patients,

cough in 16 (27.6%), chest distress and tachypnea in 4, abdominal distention in 4, abdominal pain in 4, edema in 3, headache in 3, mass in 2, and vomiting, recurrent epistaxis, poor appetite, hepatomegaly and recurrent rash, each in one. Two other patients were found occasionally who only presented with eosinophilia without any complaint.

During the disease progression, respiratory symptoms were the most common features, found in 43 (74.1%) patients, including cough in 34 (58.6%), tachypnea in 9 (15.5%), and chest pain in one. Systemic symptoms were found in 41 (70.7%) patients, including fever in 35 (60.3%), edema in 5, and fatigue in 3. Abdominal symptoms were noted in 22 (37.9%) patients, including abdominal pain in 13 (22.4%), vomiting in 10 (17.2%), abdominal distention in 6 (10.3%), and diarrhea in 2. Nervous system abnormality was noted in 6 (10.3%) patients, including headache in 5, convulsion, and facial palsy and hemiplegia each in one. Chest distress and rash (including urticaria in one) were noted each in 5 patients (Table 1).

Physical examination revealed pulmonary rale in 15 (25.9%) patients, asymmetrical breath sound in 7 (12.1%), superficial lymphadenitis in 9 (15.5%), abdominal distention in 4, hepatomegaly in 28 (48.3%), and splenomegaly in 4 (Table 1). Mass was noted in 2 patients: one had multiple painless nodes with a diameter of 2 cm in neck, and the other had a painful mass in the right upper abdomen measuring 4×4 cm.

Laboratory data

In the 58 patients, WBC ranged from 3.77 to $45.5 \times 10^9/L$, with one patient lower than $4.0 \times 10^9/L$ and 45 (77.6%) over $10 \times 10^9/L$. The percentage of neutrophils ranged from 6.2% to 84.0%, and eosinophils ranged from 0.2% to 71.2%, with 45 (77.6%) over 5%. The number of eosinophils ranged from 14 to 29542/ml, including 46 (79.3%) over 500/ml. Anemia and thrombocytopenia were noted in 14 and 3 patients respectively. Elevated ESR was noted in 24 of 50 (48.0%) patients with a highest of 89 mm/hr. Raised CRP was noted in 27 of 54 (50.0%) patients. Increased alanine aminotransferase was noted in 3 patients. Serum immunoglobulins (Ig

Table 1: The clinical characteristics of the 58 patients

Variable	Number	%
History of raw water or food ingestion	46	79.3
Fever	35	60.3
Cough	34	58.6
Abdominal pain	13	22.4
Vomiting	10	17.2
Tachypnea	9	15.5
Abdominal distention	6	10.3
Headache	5	8.6
Chest distress	5	8.6
Edema	5	8.6
Fatigue	3	5.2
Diarrhea	2	3.4
Facial palsy and hemiplegia	1	1.7
Convulsion	1	1.7
Hepatomegaly	28	48.3
Superficial lymphadenitis	9	15.5
Rash	5	8.6
Splenomegaly	4	6.9
Mass	2	3.4

were measured for 24 patients. Elevated IgG, IgM, and IgA was noted in 19 (79.2%), 14 (58.3%), and 8 (33.3%), respectively. IgE ranged from 0.5 IU/L to >400 IU/L (normal range, <100 IU/L) and elevated in 22 (91.7%), as shown in Table 2.

Radiography showed pneumonia in 26 (44.8%) patients, including lobar or segmental pneumonia in 20. It was interesting that transigrating patchy density in the right lung was noted by chest radiography, and several cysts were noted by CT scan in one patient. Meanwhile, pleurisy was found in 28 (48.3%) patients, including pleural effusion or pleural thickening (Fig 1A). Hydropericardium was found in 17 (29.3%, Fig 1A-B), ascites in 16 (27.6%), and celiac lymphadenitis in 13 (22.4%), as shown in Table 2. Pericardial fluid was collected from 9 patients. All the samples were muddy and 5 were red or brown. WBC ranged from 1280 to 15200×10⁶/L. Polymorphnuclear ranged from 45% to 85% and most were eosinophils. Protein ranged from 49.6 to 81.1 g/L with a mean of 63.76±11.57 g/L. Lactate dehydrogenase (LDH) ranged from 737.0 to 4780.0 U/L with a mean of 2147.17±1565.72 U/L. Pleural fluid was obtained from 3 patients. All samples were muddy and one red colored. WBC

ranged from 46 to 70×10⁶/L and most were monocytes. Protein ranged from 49.3 to 68.2 g/L. Ascetic fluid was collected in 2 patients. They were muddy and yellow with WBC of 368×10⁶/L and 1440×10⁶/L, polymorphnuclear of 68% and 80%, protein of 33.1 and 41.1g/L. Besides hepatomegaly and splenomegaly, calcification in the liver was found in one patient (Fig 1C), and multiple lamellar low echogenic areas were noted in another (Fig 1D). Edema of cholecystic wall was found in 9 (15.5%).

Brain abnormality was found in 4 of 10 patients undergoing CT and/or MR. Hemorrhage in the left temporal and apical lobe in one patient with facial palsy and hemiplegia was found by MR (Fig 1E). Foliated area with slight long T1 and T2 signal and obscure boundary were noted in the right parietal lobe in one patient without nervous symptoms by MR (Fig 1F). Lamella area with hypodensity in the right temporal and apical lobes, and slight anfractuosity widening were noted in another 2 patients with nervous features. Karyocyte hyperplasia was noted in all the 19 patients who received bone marrow puncture. The percentage of eosinophil granulocytes increased, even up to 55.5% (Fig 2A). The pathological study of the neck

Table 2: The laboratory data of the patients

Parameter	Median/Number	%
White blood cell ($\times 10^9/L$)	15.0 (3.77 - 45.5)	
Neutrophils (%)	47.0 (6.2 - 84.0)	
Lymphocytes (%)	28.0 (12.0 - 58.1)	
Eosinophils (%)	19.0 (0.2 - 71.2)	
Eosinophils (/ml)	2340 (14 - 29542)	
Granulocytosis	45	77.6
Eosinophilia	46	79.3
Anemia	14	24.1
Thrombocytopenia	3	5.2
Increased ESR	24/50	48.0
Increased CRP	27/54	50.0
Increased ALT	3	5.2
Increased IgG	19/24	79.2
Increased IgM	14/24	58.3
Increased IgA	8/24	33.3
Increased IgE	22/24	91.7
Pleurisy	28	48.3
Hydropericardium	17	29.3
Ascites	16	27.6
Celiac lymphadenitis	13	22.4

ESR: Erythrocyte Sedimentation Rate; CRP: C-Reactive Protein; Ig: Immunoglobulin; ALT: Alanine Aminotransferase;

mass revealed reactive hyperplasia of the lymphnodes (Fig 2B).

Diagnosis and treatment

The duration of symptoms before admission to our hospital ranged from 2 days to over 1.5 years with a median of 2 weeks. Parasitic disease was considered for 7 of the 58 patients in local hospitals. In the other patients, misdiagnosis made as pneumonia in 25, oncocytosis in 9, systemic lupus erythematosus in 4, sepsis in 4, rheumatic fever in 2, tuberculosis in 2, and liver abscess, purulent meningitis and infectious mononucleosis syndrome each in one. In our hospital, most of these patients were diagnosed with parasitic disease according to the eosinophilia in blood, pericardial fluid, ascetic fluid and/or bone marrow findings.

Praziquantel was administered at a dose of 20-80 mg/kg⁻¹/d⁻¹. Pericardial paracentesis was performed in 9 patients and constant drainage in 6 because of large pericardial fluid. All the patients improved and were discharged. The duration of hospitalization ranged from 3 to 30 days with a median of 9 days.

Discussion

The incidence of Paragonimiasis was reported to increase in some areas of China in recent years^[13]. Similarly, we found that the number of cases presented to our hospital showed an increasing trend. It might be associated with the economic development and medical science advancement, also closely related to the habitual eating of raw or undercooked food. Some eating habits are also fashionable in Zhejiang province which was transmitted from other areas, such as "Guoqiao rice noodle" from Yunnan, "Chongqi hot pot" from Chongqing, and "Sashimi" from Japan. It is notable that there were few patients not having history of raw food ingestion. Whether they were infected by just contacting metacercariae-contaminated stream is unclear. Hence, it is necessary to strengthen the awareness of not taking raw water or food.

Male was predominant in a ratio of 3:1 among the patients in this study, which is higher than in the reports in adults^[12,14,15] and may be associated with the fact that boys are more likely to eat raw crabs or crayfish. The clinical features in our

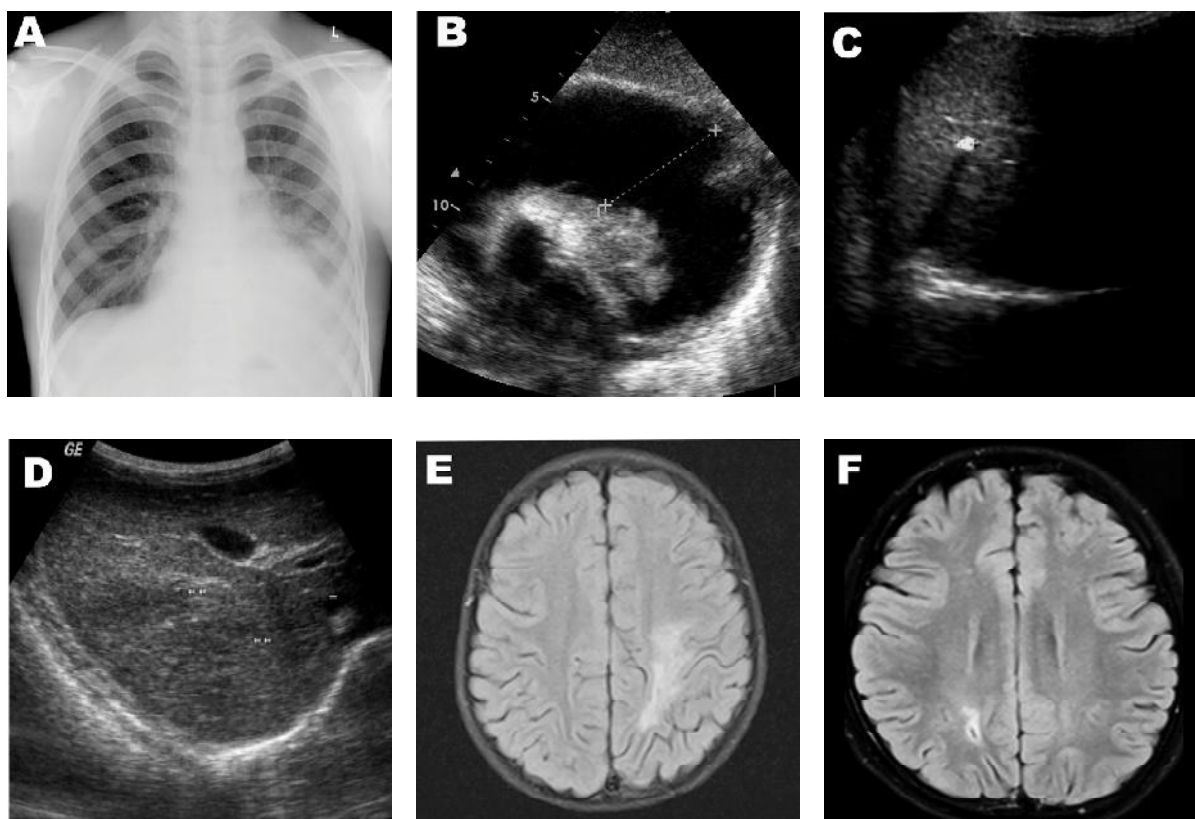


Fig. 1: Imageology of patients. **A.** Chest radiograph shows pleural effusion and hydropericardium. **B.** Ultrasound shows hydropericardium. **C.** Ultrasound shows calcification in the right liver with a size of 0.4 cm. **D.** Ultrasound shows multiple low echogenic areas in the liver. **E.** MRI shows a long T1 and T2 signal area in the left temporal and apical lobes. **F.** MRI shows slight long T1 and T2 signal area with obscure boundary in the right parietal lobe. Stick shape with hyposignal was noted within this area

patients were variable, predominated by systemic, respiratory, cardiac, and digestive system symptoms and cavity effusion. Multiple organ or system lesions were involved in most of our patients, which is similar to reports in adults [5,8,10,12]. Hemoptysis was commonly seen in adult patients [12,16,17]; however, it is rarely observed in our patients. In addition, our imageology results supported direct lesion in the liver and brain, although hepatomegaly and splenomegaly may also be induced by hydropericardium. It is notable that abnormal brain image was found in patients without any nervous feature, indicating that careful examination for the nervous, digestive and other systems should be conducted in all the patients, even without any associated features.

Eosinophilia in peripheral blood, pericardial and ascitic fluid, and bone marrow was commonly observed in our patients, as reported by others, too [5]. Granulocytosis, another common feature of paragonimiasis [18], was noted in 77.6%

of our patients. Besides, it is notable that increased immunoglobulin was also frequently seen in our patients, especially IgG and IgE, which may be associated with the immunologic sensitization and immunologic response to parasites.

Although most patients provided a history of raw water drinking or food eating after careful inquisition, only one patient provided a history of raw crab ingestion in advance.

This may be associated with the life cycle of *Paragonimus*. Because most serious symptoms were caused by the adult worms and their eggs, and the time from infection to oviposition is 2-3 months, some pediatric patients may have forgotten the history of raw food ingestion [8].

In this study, 2 asymptomatic patients were diagnosed with the clues of eosinophilia found occasionally, and most of our patients were suspected of paragonimiasis after eosinophilia detection. Based on the previous studies, at least 293.8 million people are at risk of infection with

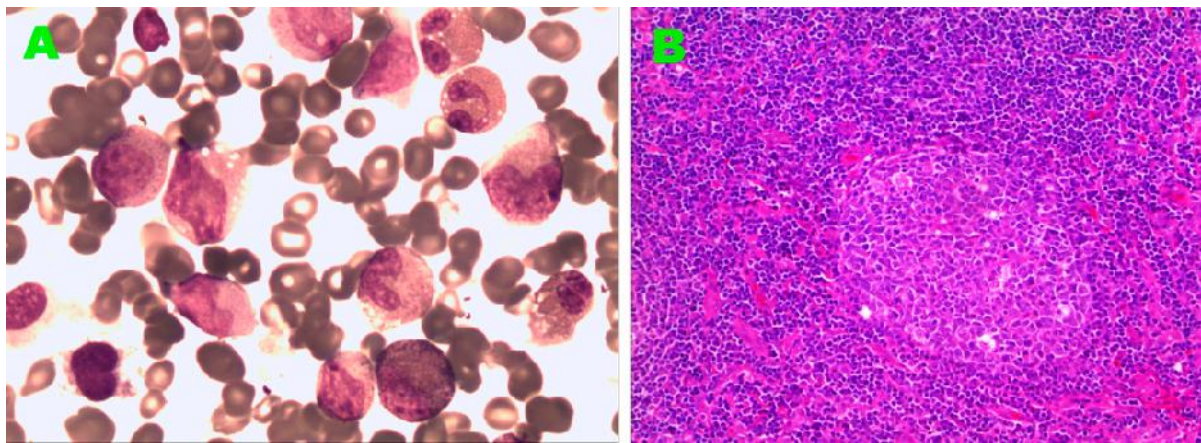


Fig. 2: The pathological study of bone marrow and lymphonodular analysis. **A)** Karyocyte hyperplasia with eosinophilia noted in bone marrow. **B)** Reactive hyperplasia of lymph node (HE, 100×)

Paragonimus parasites, with 195 million residing in China^[19]. It has been reported that children had a higher positive rate of Paragonimus antibody^[17]. These suggested that some cases might have been missed because of inapparent infection. Moreover, paragonimiasis should be considered in the differential diagnosis in patients with multiple organ or system lesions, especially in those with eosinophilia; serous cavity effusion; respiratory, cardiac, digestive, or nervous system abnormality; and/or mass. The history of raw water or food eating should be carefully inquired and specific antibodies should be detected to confirm the diagnosis.

Praziquantel and triclabendazole are two WHO-recommended drugs for treatment of human paragonimiasis. Praziquantel at a high dose of 75 mg/kg⁻¹ (divided into three doses per day) for 2 days was suggested for these patients^[5]. In this study, we noted that some patients were effectively treated with a low dose of praziquantel, even 20 to 50 mg/kg⁻¹/d⁻¹. Whether it implied that the paragonimiasis can be treated with praziquantel at a lower dose needs further investigation.

Conclusion

In summary, our results suggest that paragonimiasis should be considered in patients with

multiple organ or system lesions, especially in those with eosinophilia, serous cavity effusion, respiratory, cardiac, digestive system, nervous system abnormality. Healthy eating habit is helpful for paragonimiasis prevention.

Acknowledgment

This study was approved by the Ethical Committee of the Children's Hospital of Zhejiang University School of Medicine. We thank the guardians of these patients for permitting us used these data. This is supported by the Fundamental Research Funds for the Central Universities (2012QNA7040) and Zhejiang Province Innovation Team for Early Screening and Intervention of Birth Defects (2010R50045).

Conflict of Interest: None

References

1. Nkouawa A, Okamoto M, Mabou AK, et al. Paragonimiasis in Cameroon: molecular identification, serodiagnosis and clinical manifestations. *Trans R Soc Trop Med Hyg* 2009; 103(3):255-61.
2. Procop GW. North American paragonimiasis (Caused by *Paragonimus kellicotti*) in the context of global paragonimiasis. *Clin Microbiol Rev* 2009; 22(3):415-46.

3. Sohn WM, Ryu JS, Min DY, et al. Indochinamon ou (Crustacea: Potamidae) as a new second intermediate host for *Paragonimus harinasutai* in Luang Prabang Province, Lao PDR. *Korean J Parasitol* 2009;47(1):25-9.
4. Sugiyama H, Umehara A, Morishima Y, et al. Detection of *Paragonimus metacercariae* in the Japanese freshwater crab, *Geothelphusa dehaani*, bought at retail fish markets in Japan. *Jpn J Infect Dis* 2009;62(4):324-5.
5. Vidamaly S, Choumlivong K, Keolouangkhot V, et al. Paragonimiasis: a common cause of persistent pleural effusion in Lao PDR. *Trans R Soc Trop Med Hyg* 2009;103(10):1019-23.
6. Singh TS, Sugiyama H, Umehara A, et al. *Paragonimus heterotremus* infection in Nagaland: A new focus of Paragonimiasis in India. *Indian J Med Microbiol* 2009;27(2):123-7.
7. Lane MA, Barsanti MC, Santos CA, et al. Human paragonimiasis in North America following ingestion of raw crayfish. *Clin Infect Dis* 2009; 49(6):e55-61.
8. Liu Q, Wei F, Liu W, et al. Paragonimiasis: an important food-borne zoonosis in China. *Trends Parasitol* 2008;24(7):318-23.
9. Chen Z, Zhu G, Lin J, et al. Acute cerebral paragonimiasis presenting as hemorrhagic stroke in a child. *Pediatr Neurol* 2008;39(2):133-6.
10. McManus TE, Thomas M, Rogers D, et al. Pleuropulmonary paragonimiasis. *Intern Med J* 2009;39(3):203.
11. Tay NS, Ong KC, Tan SY, Kaw GJ. Tuberculosis mimicry. *Eur Respir J* 2005;26(3):554-6.
12. Jeon K, Koh WJ, Kim H, et al. Clinical features of recently diagnosed pulmonary paragonimiasis in Korea. *Chest* 2005; 128:1423-30.
13. Coordinating Office of the National Survey on the Important Human Parasitic Diseases A national survey on current status of the important parasitic diseases in human population. *Zhongguo Ji Sheng Chong Xue Yu Ji Sheng Chong Bing Za Zhi* 2005;23(5 suppl):332-40. [Article in Chinese]
14. Kim TS, Han J, Shim SS, et al. Pleuropulmonary paragonimiasis: CT findings in 31 patients. *AJR Am J Roentgenol* 2005;185(3):616-21.
15. Wang SM, Yang FF, Huang YX, et al. Clinical analysis of 78 cases of parasitic encephalopathy. *Zhongguo Ji Sheng Chong Xue Yu Ji Sheng Chong Bing Za Zhi* 2009;27(3):245-8. [Article in Chinese]
16. Ibrahim MG, Bunter R, Rajasooriar S, Thien F. Paragonimiasis: an unusual case of haemoptysis. *Med J Aust* 2008;188(12):734-5.
17. Devi KR, Narain K, Bhattacharya S, et al. Pleuropulmonary paragonimiasis due to *Paragonimus heterotremus*: molecular diagnosis, prevalence of infection and clinicoradiological features in an endemic area of northeastern India. *Trans R Soc Trop Med Hyg* 2007;101(8): 786-92.
18. Sohn BS, Bae YJ, Cho YS, et al. Three cases of paragonimiasis in a family. *Korean J Parasitol* 2009;47(3):281-5.
19. Keiser J, Utzinger J. Emerging foodborne trematodiasis. *Emerg Infect Dis* 2005;11(10): 1507-14.