

Pseudotumor Cerebri in a Case of Ulcerative Colitis with Sagittal Sinus Thrombosis

Ashrafi, Mahmoud Reza^{1,2,3}, MD; Hosseini, Firozeh^{*3}, MD; Alizadeh, Houman³, MD; Najafi Sani, Mehri^{1,3}, MD

1. Department of Pediatrics, Tehran University of Medical Sciences, Tehran, Iran
2. Growth & Development Research Center, Tehran University of Medical Sciences, Tehran, Iran
3. Children's Medical Center, Pediatrics Center of Excellence, Tehran, Iran

Received: Dec 24, 2012; Accepted: Jun 22, 2012; First Online Available: Dec 11, 2012

Abstract

Background: Thromboembolic events are a known complication of Inflammatory Bowel Disease (IBD) especially during disease relapse, more commonly in deep veins of extremities and lung, and rarely as Cerebral Sinovenous Thrombosis (CSVT).

Case Presentation: We describe an 11 year, old male patient with 3 months history of Ulcerative Colitis (UC) who presented as pseudotumor cerebri due to superior sagittal sinus thrombosis during an acute exacerbation of his colitis, that was successfully treated with heparin and then warfarin.

Conclusion: In any known cases of UC presenting as acute severe headache, consider CSVT and request brain MRI and MRV to facilitate the diagnosis and early treatment.

Iranian Journal of Pediatrics, Volume 23 (Number 1), February 2013, Pages: 109-112

Key Words: Inflammatory Bowel Disease; Pseudotumor Cerebri; Ulcerative Colitis; Cerebral Thrombosis

Introduction

Cerebral Sinovenous Thrombosis (CSVT) is a significant cause of pseudotumor cerebri or secondary intracranial hypertension, that is being increasingly detected due to practice of newer neuroimaging techniques including Magnetic Resonance Imaging (MRI) and Magnetic Resonance Venography (MRV). The incidence of CSVT is at least 0.67 per 100,000 children per year^[1]. The risk of thromboembolism in Inflammatory Bowel Disease (IBD) is 3-4 fold more than general population^[2]. CSVT is a rare and often under, diagnosed complication of IBD, more common in UC than in Crohn's Disease (CD). Pseudotumor cerebri is a rare presentation of

sinovenous thrombosis. We report a newly diagnosed case of ulcerative colitis (UC) that was admitted because of pseudotumor cerebri due to Superior Sagittal Sinus Thrombosis during the flare up of his colitis.

Case Presentation

An 11, year, old boy was admitted due to severe pulsatile bilateral frontal and occipital headache since 2 days ago. Headache was associated with orbital pain, photophobia, somnolence, transient blurred vision and recurrent vomiting for two

*** Corresponding Author:**

Address: Division of Neurology, Children's medical Center, No 62, Dr Gharib St., Tehran, Iran

E.mail: firozeh_hosseini@yahoo.com

© 2013 by Pediatrics Center of Excellence, Children's Medical Center, Tehran University of Medical Sciences, All rights reserved.

days. Blood Pressure 130/80 mmHg, respiratory rate 30 per minute; temperature normal. The patient was a known case of UC that has been treated with prednisolone, Asacol since 3 months ago. Because of flare up of colitis from one week ago the dose of prednisolone was increased up to 40 mg. In past medical history neonatal jaundice and operated hypospadias was reported. The mother had migraine since 15 years ago. Neurologic examination was normal except for bilateral papilledema and exaggerated (+++) bilateral deep tendon reflexes. In complete blood count (CBC) white blood cells (WBC) was 26430 (PMN73%, L17.8%, M8.8%), hemoglobin (Hgb) 11 and hematocrit (Hct) 34 and platelets (Plt) was 436000. Other laboratory findings include erythrocyte sedimentation rate (ESR) was 6 and Anti-nuclear antibodies was negative. In second CBC, WBC, Hgb and Plt were 10180 and 9.5, 344000 respectively. Urinalysis and renal function tests were normal. Lumbar puncture (LP) findings were WBC: 0.2, Pro: 6.5, RBC: 700, Glu: 65 and lactate: 15.

Brain Computerized Tomography (CT) scan showed right parasagittal low attenuated lesion in subcortical area above the central sulcus. First brain MRI showed some narrowing of superior sagittal sinus without strong evidences of thrombosis in T1 and T2 weighted imaging sequences (Fig. 1). LP showed normal cerebro-

spinal fluid (CSF) analysis with increased (32.5 cmH₂O) CSF opening pressure. With the diagnosis of pseudotumor cerebri, we continued corticosteroid administration and started acetazolamide. The second LP showed normal (14 cmH₂O) CSF pressure. The patient was readmitted one week after the discharge because of severe headache, photophobia, drowsiness and painful eye movements. LP showed increased CSF opening pressure (60 cmH₂O). In order to reduce the cerebrospinal pressure 30 ml of CSF was withdrawn. Although the second brain MRI seemed almost normal (Fig. 1), brain MRV was performed with phase contrast sequence after Gd injection that showed clearly superior sagittal sinus filling defects and irregularities due to thrombosis (Fig. 2). During the second admission an episode of transient gross hematuria was seen but abdominal sonography was normal. Serum homocysteine and B₁₂ level were within normal limits. Visual evoked potential and visual field evaluation were also normal.

Treatment with intravenous heparin infusion was initiated for 7 days and then continued with warfarin for 6 months. Control brain MRV revealed remarkable improvement in venous flow, with some residual thrombosis after three months and normal MRV after 6 months. During 6 months follow up, the patient had 2 flare-ups of ulcerative colitis without neurologic complication.

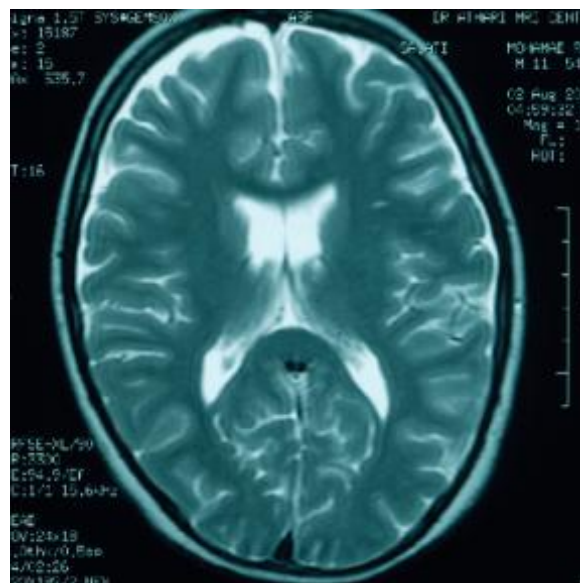


Fig. 1: Axial T2 WI looks almost normal. Note signal void superior sagittal sinus against evidence of thrombosis

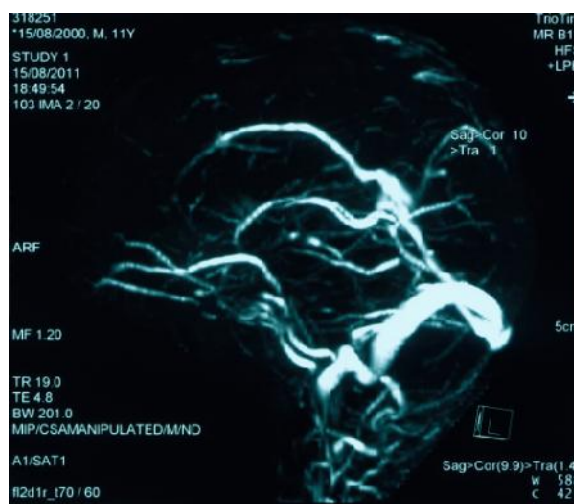


Fig. 2: MRV with Gd injection revealed nonvisualization of superior sagittal sinus due to complete thrombosis

Discussion

IBD and its thrombotic complications were first noticed by Bargen and Barker in 1936^[3]. Thromboembolic events are a known complication of IBD occurring in 1.3% to 7/5% of these patients^[4-6]. Thromboembolic complications are three fold more likely in IBD patients than in controls and the relative risk exceeds 15 during disease flares^[7].

Deep venous thrombosis and pulmonary emboli are the most common thrombotic complications of IBD, but CSVT is rare and more critical event. The most frequently involved vessels are transverse sinus (86%), superior sagittal sinus (62%), straight sinus (18%), cortical veins (17%), vein of Galen and internal cerebral veins (11%)^[7,8]. In our case the superior sagittal sinus is involved; this is reported in 0.8% of UC patients^[9]. The clinical presentations of CSVT are various including headache, encephalopathy, focal deficit and intracranial hypertension. The clinical manifestations of CSVT are nonspecific; therefore its diagnosis is difficult and requires improved attention and more suspicion. In older children headache is a common presentation of CSVT^[10]. Pseudotumor cerebri is a well documented^[11] but rare presentation of CSVT in IBD. The reported patient is a known case of UC, in whom thromboembolic complications presented as pseudotumor cerebri.

Causes of hypercoagulable state in IBD are complex, including increased procoagulants,

decreased anticoagulants, depressed fibrinolysis, platelet abnormalities, endothelial dysfunction and immunological abnormalities^[12]. Other risk factors that may play a role for thrombotic complications are corticosteroid therapy, dehydration, immobilization, iron deficiency, increased homocysteine, B₁₂ deficiency and infections^[2]. Our reported case had normal serum homocysteine and B₁₂ level but increment of corticosteroid dosage and relapse of his colitis were the known risk factors of the CSVT.

Modern neuroimaging techniques such as brain MRI and MRV are the most important investigating tools for the diagnosis of CSVT. Although linear densities and the empty delta sign in an unenhanced brain CT may suggest the diagnosis of CSVT^[1], even enhanced CT may miss the diagnosis in up to 40% of patients^[8,13]. In this patient brain CT did not suggest the diagnosis and surprisingly brain MRI was normal while MRV confirmed the diagnosis of sagittal sinus thrombosis. Cooperation between the clinician and radiologist can be helpful for appropriate imaging and establishing a faster and more accurate diagnosis. Antithrombotic therapy with standard or low molecular weight heparin for 7-10 days followed by oral anticoagulants for 3-6 months has been proved to be effective and safe^[14]. In this case we started intravenous heparin infusion and then continued antithrombotic therapy with warfarin.

Prognosis of CSVT is poor and 50% of these patients had neurologic sequelae or died^[9]. In one study 38% of the patients had neurologic deficits

and 8% died^[6]. Eight months follow-up of this case showed him in a good clinical condition and last MRV was normal.

Conclusion

We recommend considering the occurrence of CSVT in any case of UC that complains of acute severe headache and performing brain MRI and MRV to confirm the diagnosis and then faster initiation of antithrombotic therapy.

References

1. De Veber G, Monagle P, Chan A, et al. Prothrombotic disorders in infants and children with cerebral thromboembolism. *Arch Neurol* 1998;55(12):1539-43.
2. Twig G, Zandman-Goddard G, Szyper-Kravitz M. Systemic thromboembolism in inflammatory bowel disease: mechanisms and clinical applications. *Ann N Y Acad Sci* 2005;1051:166-173.
3. Bagen JA, Barker NW. Extensive arterial and venous thrombosis complicating chronic ulcerative colitis. *Arch Intern Med* 1936;58(1):17-31.
4. Murata S, Ishikawa N, Oshikawa S, et al. Cerebral sinus thrombosis associated with severe active ulcerative colitis. *Intern Med* 2004;43(5):400-3.
5. Shigemori Y, Koshinaga M, Suma T, et al. Superior sagittal sinus thrombosis suffered as a complication of ulcerative colitis: case report. *No Shinkei Geka* 2006;34(9):939-42.
6. Kawanishi M, Yoshida Y, Sakaguchi I, et al. Cerebral venous sinus thrombosis in a patient with ulcerative colitis. *J Stroke Cerebrovasc Dis* 2003;12(6):271-5.
7. Zitomersky NL, Verhave M, Trenor CC, et al. Thrombosis and inflammatory bowel disease: A call for improved awareness and prevention. *Inflamm Bowel Dis* 2001;17(1):458-70.
8. De Veber G, Maureen A, Adams C, et al. Cerebral sinovenous thrombosis in children. *N Engl J Med* 2001;345(6):417-22.
9. Ozdil S, Akyüz F, Pinarbasi B, et al. Ulcerative colitis: analyses of 116 cases (do extraintestinal manifestations effect the time to catch remission?). *Hepatogastroenterology* 2004;51(57):768-70.
10. Nudelman RJ, Rosen DG, Rouah E, Verstovsek G. Cerebral sinus thrombosis: a fatal neurological complication of ulcerative colitis. *Patholog Res Int* 2010; 2010:132754.
11. Carvalho KS, Bodensteiner JB, Connolly PJ, Garg BP. Cerebral venous thrombosis in children. *J Child Neurol* 2000;16(8):574-80.
12. Biousse V, Ameri A, Bousser MG. Isolated intracranial hypertension the only sign of cerebral venous thrombosis. *Neurology* 1999; 53(7):1537-42.
13. Barron TF, Gusnard DA, Zimmerman RA, et al. Cerebral venous thrombosis in neonate and children. *Pediatr Neurol* 1992;8(2):112-6.
14. Sebire G, Tabarki D, Saunders E, et al. Cerebral venous sinus thrombosis in children: risk factors, presentation, diagnosis and outcome. *Brain* 2005; 128(pt 3):477-89.