

Overweight and Obesity among Urban Bengalee Early Adolescent School Girls of Kharagpur, West Bengal, India

Maiti, Soumyajit^{1,2}, MSc; Chatterjee, Kausik¹, MSc;
Monjur Ali, Kazi¹, MSc; Ghosh, Abhinandan¹, MSc;
Ghosh, Debidas^{*1,2,3}, MSc, PhD;
Paul, Shyamapada^{2,3}, MSc, PhD

1. Department of Bio-Medical Laboratory Science and Management, Vidyasagar University, Midnapore, West Bengal, India
2. Rural Research Institute of Physiology & Applied Nutrition 'Gitanjali', Midnapore, West Bengal, India
3. Nutrition & Dietetics Unit, Vidyasagar University, Midnapore, West Bengal, India

Received: Oct 10, 2011; Accepted: Jan 16, 2012;
First Online Available: Jan 17, 2013

A dramatic increase in the prevalence of overweight and obesity has occurred during the last few decades worldwide^[1,2] and is prevalent across gender and ethnic groups^[3,4]. Recent statistics also shows that prevalence of overweight continues to increase during the school age and pre-adolescent/adolescent stages^[3]. In this stage children attain a rapid growth spurt, characterized by rapid linear growth and deposition of fat mass^[3]. Many studies reported that girls had higher average of body fat mass than their boy counterparts^[1,4]. Abdominal obesity among girls is shown to be an emerging issue. Boys tend to deposit more fat free mass than fat mass while girls tend to deposit more fat mass than fat free mass^[3]. Similar trend has also been demonstrated in Indian school-aged children^[5].

Epidemiological literature shows that about one-third of obese pre-school children and about one-half of obese school age children become obese adults^[2]. Lifestyle transition and socio-economic improvement have contributed enormously to the escalating problem of overweight and obesity among children in developing countries^[5]. A child with obesity is at risk to develop a wide spectrum of adiposity-related diseases and comorbid conditions^[1,3]. Hence close monitoring of overweight

prevalence in children and adolescents and taking timely preventive measures will be an effective approach in dealing with the problem of obesity.

Seven secondary schools in Kharagpur municipality of Paschim Medinipur district, West Bengal, India were randomly selected and all 1481 girls (Bengalee Hindu and Muslims ethnicity) from the age group of 10-14 studying in these schools were screened for overweight and obesity.

The height and weight measurements were made and recorded following the standard techniques^[6]. Height and weight were measured using anthropometric rod and weighing scale to the nearest of 0.1cm and 0.5kg, respectively. Technical errors of measurements (TEM) were computed and they were found to be within acceptable limits. The body mass index (BMI=weight/height²) has been recommended to be used routinely to evaluate obesity in children and adolescents^[7].

Two methods for the classification of obesity and overweight were utilized in this study. The first was according to the proposed cut-off points for BMI adopted by the International Obesity Task Force (IOTF)^[8], based on international data and linked to the widely accepted adult cut-off points for overweight and obesity (BMI of 25 and 30 kg/m², respectively). The second was based on CDC growth charts, and more specifically the 85th percentile was taken as a cut-off point for overweight whereas the 95th was taken for obesity^[9].

The overall mean values (\pm SD) of weight, height and BMI of participants were 32.47(\pm 8.37), 139.39(\pm 10.16) and 16.50(\pm 2.85), respectively. According to the BMI cut-off points of IOTF, 6.75% of girls in the study were classified as overweight, whereas obese were 1.01%. Corresponding values using CDC growth charts were 6.89% of girls for overweight and 1.89% of girls for obese. The prevalence of overweight obesity was highest at 14 years of age and lowest at 12 years of age.

Present study also illustrated ethnic specific comparisons of BMI in Fig. 1. When we examined

* Corresponding Author; Address: Bio-Medical Laboratory Science and Management (U.G.C. Innovative Funded Department), Vidyasagar University, Midnapore -721 102, West Bengal, India
E-mail: debidas_ghosh@yahoo.co.in

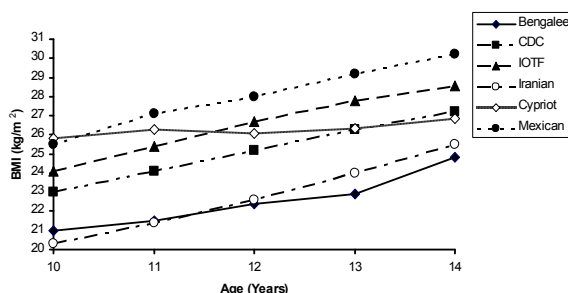


Fig. 1: Comparison of the 95th percentile of BMI values in early adolescent girls from various parts of the world [CDC, IOTF, Sanghai, Cypriot, Mexican].

the early adolescent girls' 95th BMI percentile curves, Mexican adolescent girls' [11] percentiles stayed highest on the figure and above the IOTF standards values. Cypriot adolescent girls' [11] percentiles curve dropped at the age of 12 years. Both curves were above the CDC standard curve. The smoothed curve of Iranian girls was the below the curves of CDC. Interestingly, 95th BMI curve of the Bengalee early adolescent girls lied at the bottom on early ages and increased more sharply with age.

Childhood obesity is a growing national concern. This study and other recent studies^[2,5] confirm that it has become a major public health challenge in urban areas of India. The increasing prevalence of obesity in a population is an early indicator of an emerging health burden due to the increasing mortality and morbidity from NCDs in developing societies^[2].

School based data in India showed the extent of overweight is most pronounced in the pre-adolescents group^[3,5]. A study in urban areas of India (as per IOTF) showed that overweight and obesity among early adolescent school girls was 15.2% and 5.3%, respectively^[2]. This probably accounted for the better nutrition of the affluent girl. Prevalence of overweight in the present study was similar to those reported extent of overweight among *Bengalee* early adolescent girls was 7.20% (IOTF criterion used)^[5].

Modern lifestyles (nutritional habits, inactivity and socio-economic improvement) in an obesogenic environment cause an increased prevalence of obesity among children^[1,3]. The increasing incidence of overweight during early adolescence in girls is a critical health issue^[5].

The present study highlights that childhood overweight/obesity is an emerging health problem that requires effective preventive

strategies to halt the epidemic. Targeting interventions at early stages may be effective way of dealing with overweight and obesity.

Acknowledgements

We are grateful to the children who participated, their parents and teachers for their support and cooperation in field work of this study.

Key words: Obesity; Overweight; Children; Adolescent

References

1. Gaeini A, Kashef M, Samadi A, et al. Prevalence of underweight, overweight and obesity in preschool children of Tehran, Iran. *JRMS* 2011; 16(6):821-27.
2. Mehta M, Bhasin SK, Agrawal K, et al. Obesity amongst affluent adolescent girls. *Ind J Pediatr* 2007; 74:619-22.
3. Mosha TCE, Fungo S. Prevalence of overweight and obesity among children aged 6-12 years in Dodoma and Kinondoni Municipalities, Tanzania. *Tanzania J Health Res* 2010; 12(1):
4. Mohammadpour-Ahranjani B, Rashidi A, Karandish M, et al. Prevalence of overweight and obesity in adolescent Tehrani students, 2000-2001: an epidemic health problem. *Public Health Nutr* 2004; 7:645-48.
5. Bisai S, Khongsdier R, Bose K, et al. Prevalence of overweight and obesity among Bengalee adolescents in Midnapore town, West Bengal, India. *Int J Cur Res* 2010; 10:74-83.
6. Lohman TG, Roche AF, Martorell R. Anthropometric Standardization Reference Manual. Chicago: Human Kinetics Books. 1988.
7. Hosseini M, Carpenter RG, Mohammad K, et al. Standardized percentile curves of body mass index of Iranian children compared to the US population reference. *International Journal of Obesity* 1999; 23:783-87.
8. Cole TJ, Bellizzi MC, Flegal KM, et al. Establishing a standard definition for child overweight and obesity worldwide: international survey. *BMJ* 2000; 320:1240-43.
9. CDC/NCHS. Centers for Diseases control and Prevention / National Center for Health Statistics. CDC Growth Charts: United States, 2000. Available at: 'at:<http://www.cdc.gov/growthcharts>. Access Date: Aug 10, 2011.
10. Savva SC, Kourides Y, Tornaritis M, et al. Reference Growth Curves for Cypriot Children 6 to 17 Years of Age. *Obesity Res* 2001; 9(12):754-62.
11. del Rio-Navarro BE, Velazquez-Monroy O, et al. The High Prevalence of Overweight and Obesity in Mexican Children. *Obesity Res* 2004;12(2):215-23.

Kabuki Make-Up Syndrome with Bilateral Dislocation of the Hip

Elmouhtadi, Aghoutane*, MD; Redouane, Fezzazi, MD

Department of Orthopedic Pediatric Surgery, Medical University Hospital Mohammed VI, Faculty of Medicine and Pharmacy, Marrakech, Morocco

Received: Oct 19, 2011; Accepted: Apr 08, 2012;
First Online Available: Jan 17, 2013

Kabuki make-up syndrome (KMS) is a rare multiple congenital anomalies/mental retardation syndrome of unknown cause, first described independently by Niikawa and Kuroki. It is characterized by distinctive facial features, skeletal anomalies, dermatoglyphic abnormalities, short stature, and mental retardation. A group of abnormalities with involvement of other organs can lead to diagnosis of KMS.

The authors report a 4-and-half-year old girl with KMS, admitted for bilateral dislocation of the hip. On this case, we try to explain the syndrome and to allow pediatricians and other physicians to become familiar with this syndrome.

KMS (OMIM#147920) is a rare dysmorphic syndrome that was first described in 1981 by Niikawa et al^[1] and Kuroki et al^[2]. The name of the syndrome, Kabuki make-up, refers to resemblance of the facial traits of KMS patients to the make-up of actors in Kabuki, the traditional Japanese theatre^[1,2].

KMS is more common in Japan, although it has been reported from different geographic regions

in the world^[3]. Only few hundred cases have been described, and it is expressed as 1/32000 incidence in Japan^[4]. We recently observed a 4 and half year old girl with typical KMS presented with bilateral dislocation of the hip.

The patient was referred to pediatric orthopedic department for bilateral dislocation of the hip. Her parents were healthy with no consanguinity.

Psychomotor development was delayed with speech defects. On physical examination at the age of 4 years, the patient's height was 92 cm, weight 15 kg. She had characteristic facial dysmorphism with high arched eyebrows that were sparse in the lateral part, long palpebral fissures, prominent and protruding ears and lip pits on the lower lip, depressed nasal tip (Fig. 1A). She also had joint laxity, brachydactyly V (Fig. 1B) and finger tip pads (Fig. 1C).

Other findings were normal. Chest radiography showed kyphotic deformity of the spine. Echocardiography was normal. Abdomen and pelvic sonography showed pelvic situation of the right kidney. Pelvic radiography showed bilateral dislocation of the hip (Fig. 2). She was diagnosed as Kabuki make-up syndrome due to clinical findings.

She was operated for bilateral dislocation of the hip with, in the first, the right hip by open reduction, iliopsoas and adductor releases, capsuloraphy and Salter innominate osteotomy, and the same technique in the left hip with good results.

KMS occurs mostly sporadic, although some familial cases have been reported^[6]. Inheritance

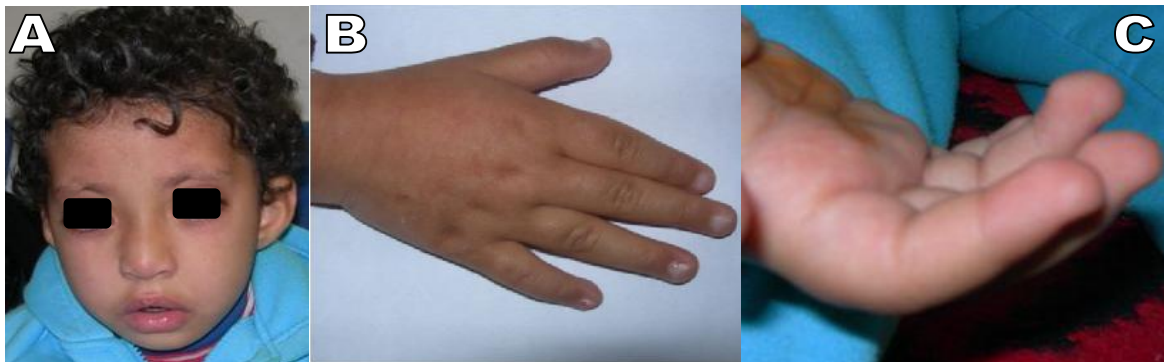

Fig. 1: A) Characteristic facial dysmorphism with high arched eyebrows that were sparse in the lateral part, long palpebral fissures, prominent and protruding ears and lip pits on the lower lip, depressed nasal tip. B): Brachydactyly V and C) finger tip pads in patient with Kabuki make-up syndrome.

* Corresponding Author; Address: BP 3939 amerchich Marrakech, Morocco

E-mail: elmouhtadi@yahoo.com

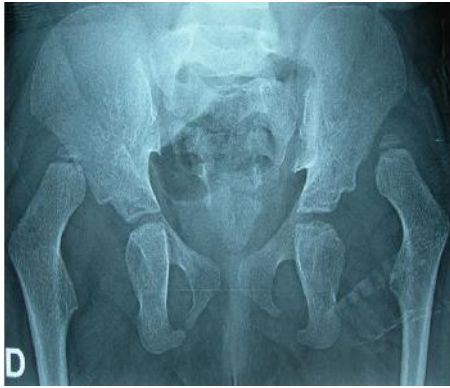

Fig. 4: Pelvic radiography shows bilateral dislocation of the hip

is thought to be autosomal dominant on X-linked recessive; although several cases with KMS features have been reported with different chromosomal anomalies, none have had an autosomal cytogenetic aberration in common^[5,6]. In 1988, Niikawa et al^[7] reported 62 patients diagnosed with KMS. Based on the findings in these patients, five cardinal manifestations were defined. These included a peculiar face characterized by eversion of the lower lateral eyelid, arched eyebrows with the lateral one-third dispersed or sparse, depressed nasal tip, and prominent ears in 100%, skeletal anomalies characterized by deformed spinal column with or without sagittal cleft vertebrae, and brachydactyly V in 92%, dermatoglyphic abnormalities including fingertip pads, absence of digital triradius c and/or d, and increased digital ulnar loop and hypothenar loop patterns in 93%, mild to moderate mental retardation in 92%, and postnatal growth deficiency in 83% of their patients. For positive diagnosis, it is necessary to have minimally peculiar facial appearance, mental retardation and postnatal growth deficiency^[7-10]. Our patient had a typical KMS. Philip et al^[11] have commented from various European centers that skeletal abnormalities are common in the syndrome, but that they are usually not specific radiologically. They included shortening of metacarpals and phalanges in the majority of cases, syndactyly and joint laxity, short stature, scoliosis and short fifth fingers^[10].

The high risk of dislocation of the hip has been attributed to the generalized joint laxity that was observed in 10 of 16 cases^[8,9].

Structural heart defects are encountered in 32%-58% of children, and non specific congenital heart defect predominates^[7,9].

Neonatal hypotonia and feeding difficulties, recurrent infections, reno-urinary malformations, diaphragmatic anomalies, neurological symptoms, abnormalities of the central nervous system, obesity, and precocious puberty are also reported in this syndrome^[9,10].

Key words: Kabuki Make-Up Syndrome; Children; Dislocation of the hip

References

1. Nikawa N, Matsuura N, Fukushima Y, et al. Kabuki make up syndrome: a syndrome of mental retardation, unusual facies, large and protruding ears, and post natal growth deficiency. *J Pediatr* 1981; 99(4):565-9.
2. Kuroki Y, Suzuki Y, Chyo H, et al. A new malformation syndrome of long palpebral fissures, large ears, depressed nasal tip, and skeletal anomalies associated with postnatal dwarfism and mental retardation. *J Pediatr* 1981;99(4):570-3.
3. Muluk NB, Yalcinkaya F, Budak B, et al. Evaluation for language and speech development in Kabuki make-up syndrome. A case report. *Int J Pediatr Otorhinolaryngol* 2009;73(12):1837-40.
4. Tekin M, Fitoz S, Arici S, et al. Niikawa Kuroki (Kabuki) syndrome with congenital sensorineural deafness: Evidence for a wide spectrum of inner ear abnormalities. *Int J Pediatr Otorhinolaryngol* 2006; 70(5):885-9.
5. Vaccaro M, Salpietro DC, Briuglia S, et al. Cutis laxa in Kabuki make-up syndrome. *J Am Acad Dermatol* 2005;53(5 Suppl 1):247-51.
6. Courtens W, Rassart A, Stene JJ, et al. Further evidence for autosomal dominant inheritance and ectodermal abnormalities in Kabuki syndrome. *Am J Med Genet* 2000;93(3):244-49.
7. Niikawa N, Kuroki Y, Kajii T, et al. Kabuki make-up (Niikawa-Kuroki) syndrome: a study of 62 patients. *Am J Med Genet* 1988;31(3):565-89.
8. Kawame H, Hannibal C, Hudgins L, et al. Phenotypic spectrum and management issues in Kabuki syndrome. *J Pediatr* 1999;134(4):480-5.
9. Santiago J, Muszlak M, Goulois E, et al. A case of Kabuki syndrome admitted for acute diarrhea and growth retardation in a French hospital in tropical area. *Arch Pédiatrie* 2010;17(5):588-93. [In French]
10. Matsumoto N, Niikawa N. Kabuki make-up syndrome: a review. *Am J Med Genet* 2003; 117C(1):57-65.

Basal Encephalocele Associated with Teratoma; Pathogenesis and Management, Case Report

Shahjouei, Shima, MD; Nejat, Farideh*, MD, MPH;
El Khashab, Mostafa, MD, PhD

1. Department of Neurosurgery, Tehran University of Medical Sciences, Tehran, Iran
2. Children's Medical Center, Pediatric Center of Excellence, Tehran, Iran
3. Department of Neurosurgery, Hackensack University Medical Center, New Jersey, USA

Received: Jun 21, 2012; Accepted: Oct 31, 2012;
Online Available: Dec 05, 2012

Encephaloceles are rare entities presenting as protrusion of intracranial structures through a defect in the skull^[1,2]. Teratomas, tumors with the potential of giving rise to all three germ cell layers, are other rare entities which can involve the intracranial components. Here we describe a patient with basal encephalocele associated with teratoma.

A 9-month-old girl was referred to the neurosurgical department due to small frontal mass since birth and progressive hypertelorism. On examination she had a bifid nose, prominent hypertelorism and small midline mass covered by abnormal skin and small thick hairs (Fig 1).

She was normal in developmental status. Brain magnetic resonance imaging showed normal brain but nonhomogenous anterior fossa mass. Computed tomography scan confirmed a small hole in proximal portion of nasal bone, associated with a nonhomogenous mass between the two right and left ethmoidal sinuses that seemed to be in continuity with extracranial mass descending through the nasal bone defect (Fig. 1).

Surgery was performed through bifrontal craniotomy. The nasal small defect contained a lipomatous tissue that traversed the bone defect to intracranial space and was going to anterior fossa intradurally to reach the basal mass. There was a 2×2 cm bone and dural defect in the anterior fossa, around foramen caecum, which was filled with basal mass (Fig. 2).

The mass contained soft tissue and cartilaginous material that invaginated into nasal cavity and displaced both ethmoidal sinuses

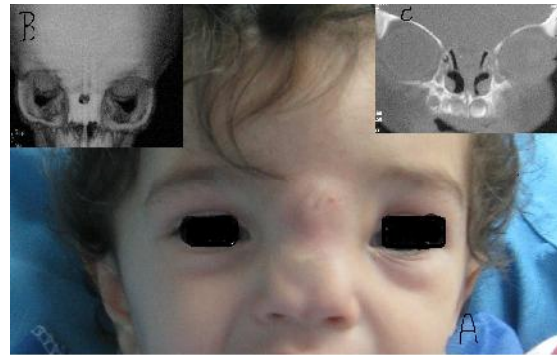


Fig. 1: A: Photograph of the patient shows hypertelorism, small midline mass associated with nasal pole widening.

B: Brain CT scan reveals a small hole in the proximal portion of nasal bone. **C:** The mass is located between two ethmoidal sinuses displacing two sinuses laterally.

laterally which was en bloc resected. The dural defect was repaired with pericranium patch graft and the basal bone defect was covered with bone harvested from posterior part of craniotomy. Pathological examination of the surgical specimen revealed a variety of tissues including neural tissue, muscle, cartilage, adipose tissue, vascular structures, and respiratory epithelium diagnosed as mature teratoma. The postoperative period was uneventful. She had regular follow up and now one year after surgery, she has normal development and growth without recurrence of the tumor or progression of her hypertelorism.

Teratoma is the most frequent congenital tumor with early presentation at birth^[3]. Head and neck teratomas account for 2-9% of all teratomas^[2].

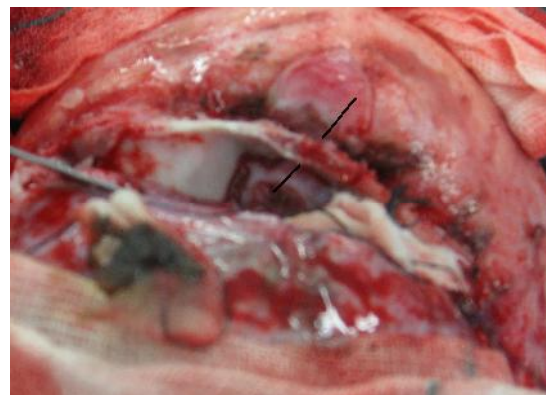

Fig. 2: Intraoperative photography confirms the basal mass which was in continuity with nasal mass (black line) and displaced two ethmoidal cells laterally

* Corresponding Author; Address: Division of Neurosurgery, No 62, Children's Medical Center, Dr Gharib St., Tehran, Iran
E-mail: nejat@sina.tums.ac.ir

Our patient had an anterior encephalocele accompanied by teratoma. According to our extensive literature review, this association was very rarely reported so far^[2,4].

Several hypotheses had been suggested to describe the pathogenesis of encephaloceles or teratomas but association of two entities cannot be simply explained by these models. Enrolment of tissue induction through different steps of embryogenesis and neurulation has been suggested in the pathogenesis. Migration and differentiation of neural crest cells affect greatly the fate of other cells and interrupted migration^[5,6]. Human neural crest cells develop late at the first month of embryonic period and give rise to neurons and glial cells of peripheral nervous system, meninges, dermis, bone, cartilage and some other tissues^[7]. Failure of neural crest cells migration, by interrupting this induction effect and preventing correctly cell differentiation can result in major structural defects like encephalocele. Surprisingly, human neural crest cells have the characteristic of uncommitted stem cells due to highly similar molecular profile to pluripotent embryonic stem cells. On this basis, neural crest cells can be able to produce tumors consisting of three germ layers, commonly called teratomas^[7]. However, by this hypothesis we would expect higher incidence of encephaloceles containing teratomas. This controversy might be solved by assuming that formation of these two entities needs defect in early stages of differentiation, resulting in defective development of other structures and putting the embryo in the risk of prenatal death.

The other hypothesis can be interpositioning of teratomatous cells in the tissue producing the future skull that makes bone defect and subsequently encephalocele^[4].

The impact of basal encephaloceles on the surrounding tissues develops hypertelorism which progresses rapidly during first years of life. Early surgical correction of this abnormality can stop or even prevent hypertelorism.

Key words: Basal Encephalocele; Hypertelorism; Pathogenesis; Teratoma; Surgery

References

1. Suwanwela C. Geographical distribution of fronto-ethmoidal encephalomeningocele. *Br J Prev Soc Med* 1972;26(3):193-8.
2. Turgut M, Meteoglu I. Mature teratoma associated with an interparietal encephalocele. *Neurosurg* 2007;106(4 Suppl):305-7.
3. Yu L, Krishnamurthy S, Chang H, et al. Congenital maturing immature intraventricular teratoma. *Clin Imaging* 2010;34(3):222-5.
4. Radmanesh F, Nejat F, Monajemzadeh M. Teratoma within an encephalocele: common etiology or coincidence. *J Neurosurg* 2007;107(3):263-5.
5. Blustajn J, Netchine I, Frédy D, et al. Dysgenesis of the internal carotid artery associated with transsphenoidal encephalocele: a neural crest syndrome? *Am J Neuroradiol* 1999;20(6):1154-7.
6. Joy HM, Barker CS, Small JH, et al. Trans-sphenoidal encephalocele in association with Dandy-Walker complex and cardiovascular anomalies. *Neuroradiology* 2001;43(1):45-8.
7. Thomas S, Thomas M, Wincker P, et al. Human neural crest cells display molecular and phenotypic hallmarks of stem cells. *Hum Mol Genet* 2008;17(21):3411-25.

Pulmonary Hypoplasia Associated with Multiorgan Developmental Abnormalities – a Rare Case Report

Shu, Chang¹; He, Ling²; Li, Qubei¹; Wang, Qiao³; Huang, Ying^{*1}

1. Department of Respiratory Medicine, Children's Hospital of Chong Qing Medical University, Chong Qing, China
2. Department of Radiology, Children's Hospital of Chong Qing Medical University, Chong Qing, China
3. Department of Ultrasonic Diagnosis, Children's Hospital of Chong Qing Medical University, Chong Qing, China

Received: Sep 15, 2011; Accepted: Apr 22, 2012;
First Online Available: Feb 25, 2013

Pulmonary hypoplasia and pulmonary artery hypoplasia are two congenital malformations of the respiratory system which are rarely observed in the clinic^[1,2]. The difference in patterns and the extent of this congenital malformation result in a great variability in clinical manifestations, usually leading to misdiagnoses. We herein for the first time report a case of a boy who presented with dyspnea, cough, cyanosis and fever, and was initially diagnosed as pulmonary atelectasis. Later on,

* Corresponding Author; Address: Department of Respiratory Medicine Children's Hospital of Chong Qing Medical University, Chong Qing, China
E-mail: huangying62@126.com

through a series of computed tomography angiography (CTA), color Doppler ultrasonography and fiberoptic bronchoscopy procedures, he was found to have malformations of the lung and digestive system, atrial septal defect and spina bifida.

A 16 month-old Han (Mongolian race) boy from the Sichuan Province was admitted to our hospital due to difficulty in breathing, cough, expectoration, cyanosis, and medium-high fever that were persistent for more than one month. He was marasmic with poor eating, passed loose yellow-green stools without blood three to four times per day. His mother suffered from colporrhagia and was administered with Chinese medicine during her first month of pregnancy. No history of radioactive, toxic material and pet exposure before and during pregnancy were found. This child had an anoplasty for congenital anal atresia, and had blue light treatment for jaundice during neonatal period. He also had recurrent upper respiratory tract infection previously.

There was no similar case in his family and his parents were not intermarried. Physical examination revealed normal vital signs. The boy was underweight without icterus in both his skin and sclera, short of breath, showed flaring of alae nasi, lip cyanosis, trachea deviation to the left, and marked with an inspiratory of three depressions. While his right thoracic cage was full and stable, his left side was collapsed, leaving uneven respiratory movement, no sense of pleural friction. In addition, exaggerated breath sounds were heard throughout the right lung,

while breath sounds were diminished in the left lung; without dry or moist rales. Heart percussion was normal. The abdomen was slightly distended and venae epigastriacae were visible. While the liver under the right rib cage was untouched, the 4 cm spleen was felt under the left rib edge. His liver function, blood, stool, urinalysis and other biochemical parameters were within normal ranges. Cytomegalovirus (CMV)-IgM was negative, CMV-IgG ++. Sputum was positive for *Hemophilus parainfluenzae* and *Pseudomonas aeruginosa*. Virus tests in nasopharyngeal secretion sample were all negative. Chest X-ray and CT scan suggested pneumonia, left-side pleurisy and agenesis of the left lung. Fiberoptic bronchoscopy showed luminal stenosis in the middle and lower part of the left main bronchial tube, and dead ends in the left superior and lower lobe bronchus.

To further investigate, we performed 64-slice chest and abdominal CT angiography. The results, summarized in Fig. 1, showed: 1) Absence of the left pulmonary artery, agenesis of the left lung and obstruction of the distal area of the left main bronchial tube. 2) Heart and mediastinum were displaced to the left, and a left hernia of the mediastinum. 3) Light interstitial inflammation in the right lung with pleura thickened on both sides. 4) A mass of irregular, tortuous blood vessels in the first hepatic hilar region, and varices of fundus of stomach with splenomegaly, which was consistent with the cavernous transformation of the portal vein (CTPV). 5) Spina bifida at the L3 level.

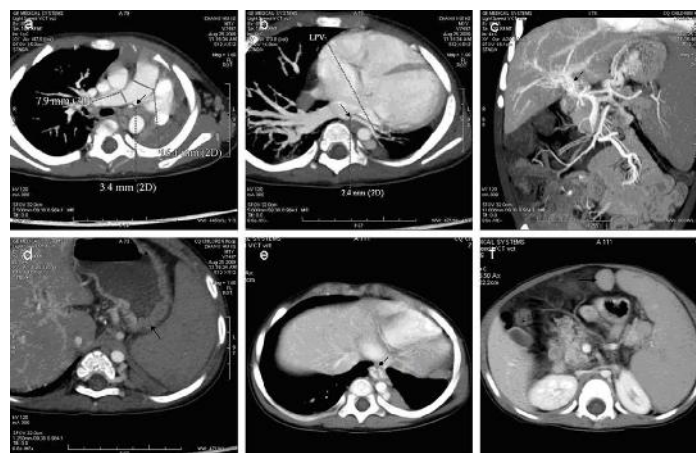


Fig 1. a-b. The left pulmonary artery and vein were thinned; diameters were 3.4 and 2.4 mm, respectively. c. The irregular vessels in the primary hepatic portal area. The venous plexus of the portal vein area was thick and varicose. d. Gastric varices. e. Esophageal and gastric varices. f. Accessory spleen.

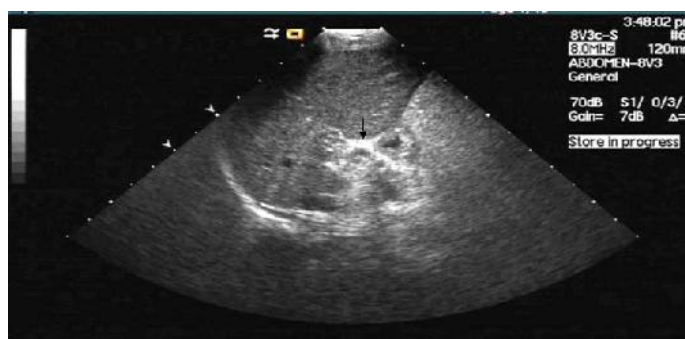

Fig. 2: Ultrasonic appearance: The hepatic capsule was smooth and the echo of the liver parenchyma was slightly enhanced, but homogenous. The portal vein was tortuous with a thickened and echo enhanced wall. The inside diameter of PV was from 0.28 cm to 0.6 cm and the flow rate was 0.11m/s. The inside diameter of the splenic vein was 0.8 cm. The ultrasonic appearance of the pancreas, gallbladder and common bile duct were all normal.

The results of color Doppler ultrasonography, shown in Fig. 2, unveiled the following: 1) Absence of the pulmonary artery. 2) Enhancement of the liver parenchyma echo. This describes the thick wall of the portal vein and the enhanced echo of the wall. The vein was tortuous and the velocity of blood flow was slow, which was consistent with CTPV. 3) Splenomegaly associated with the widened splenic vein. 4) Atrial-septal defect (ASD, 5.7 mm) associated with light tricuspid regurgitation.

Based on patient history and physical and other tests, the following final diagnoses were made: 1) congenital left pulmonary hypoplasia associated with an absent left pulmonary artery, left mediastinum, and right emphysema; 2) primarily CTPV, portal hypertension and splenomegaly; 3) ASD, congenital anal atresia (after anoplasty), and spina bifida; 4) pneumonia and pleurisy; 5) secondary thrombocytopenia.

Unfortunately, the patient had no indication for major surgical procedures for his abnormalities. Cefapime was used for bacterial pneumonia and pleurisy. Symptomatic and supportive treatments, such as oxygen therapy, IVIG and oral drugs to facilitate expectoration and suppress his cough until the boy was discharged from hospital after his pneumonia and pleurisy were cured. No surgery was performed after his discharge. Unfortunately, the boy died due to uncontrollable massive hemorrhage of digestive tract after 6 months.

There were few cases regarding other congenital malformations being associated with pulmonary hypoplasia (estimated incidence of

total pulmonary agenesis is 0.0034–0.0097%^[3-5]). When treating patients with pulmonary atelectasis fails to respond to antibiotic therapy, physicians should think on the possibility of pulmonary hypoplasia, especially in children. Though highly improbable, pulmonary hypoplasia may be associated with multiple abnormalities. CT angiography and color Doppler ultrasonography will be helpful to diagnose accompanying malformations, such as CTPV, in patients with pulmonary hypoplasia. In addition, more studies are needed to better understand the etiology, occurrence and treatment of this rare abnormality.

Key words: Cavernous transformation of the portal vein; Pulmonary artery hypoplasia; Pulmonary hypoplasia; Respiratory system; Multiorgan developmental abnormalities

References

1. Andrade CF, Ferreira HP, Fischer GB. Congenital lung malformations. *J Bras Pneumol* 2011;37(2): 259-71.
2. Biyyam DR, Chapman T, Ferguson MR, et al. Congenital lung abnormalities: embryologic features, prenatal diagnosis, and postnatal radiologic-pathologic correlation. *Radiographics* 2010;30(6):1721-38.
3. Espinosa L, Agarwal P. Adult presentation of right lung agenesis and left pulmonary artery sling. *Acta Radiol* 2008;49(1):41-4.
4. Tortajada-Girbés M, López-Calatayud V, Navarro-Ruiz A, et al. Pulmonary agenesis: importance of the diagnosis. *Allergol Immunopathol* 2010;38(3):162-5.
5. Sorrentino D, Labombarda A, DeBiase F, et al. Cavernous transformation of the portal vein associated to multiorgan developmental abnormalities. *Liver Int* 2004;24(1):80-3.

Affective Disorder as the First Manifestation of Methylmalonic Acidemia: A Case Report

Sheikhmoonesi, Fatemeh^{*1}, MD; Shafaat, Arefeh¹, MD;
Moarefian, Shirin², MD; Zaman, Talieh, MD

1. Psychiatry and Behavioral Sciences Research Center, Mazandaran University of Medical Sciences, Sari, Iran
2. Iranian Inherited Metabolic Diseases Association
3. Department of Pediatric, Tehran University of Medical Sciences, Tehran, Iran

Received: Jan 20, 2012; Accepted: Jun 27, 2012;
First Online Available: Feb 25, 2013

Methylmalonic acidemia (MMA) is the most common organic acidemia in Asian cases. We report a 14-year-old boy who was admitted to psychiatric clinic with affective symptoms. MMA was diagnosed after extensive laboratory tests. This emphasizes that even a typical psychiatric disorder can actually represent part of the spectrum of an underlying systemic disorder. MMA is an autosomal-recessive inborn error of metabolism. The incidence might be as high as 1 in 25,000^[1]. It is believed that this disease is more prevalent in the Middle East because of consanguineous marriages^[2]. MMA usually presents clinically with nonspecific symptoms such as seizure, poor feeding, loss of consciousness, psychomotor retardation. As a consequence, patients often undergo extensive work-up before the correct diagnosis is made^[3,4].

MMA is usually diagnosed in the first year of life^[2], however, this report deals with a patient whose disease could not be diagnosed until the age fourteen.

H. is a 14-year-old male who was referred to child and adolescent psychiatry clinic without previous psychiatric history.

At that time, he exhibited irritability, labile mood, irrelevant speech, distractibility, agitated psychomotor, poor concentration, poor attention, self crying, self laughing, hypersomnia and hyper sexuality. His behavior had changed since 3 days ago suddenly without any significant stressor. He was admitted for inpatient treatment. On detailed history taking and assessment, it was found that he did not use

any substance or drug, past medical history and familial history were negative. Furthermore, it was realized that his parents were cousins.

Routine lab tests showed normal results. Brain CT-scan (Computerized tomography) and brain MRI (Magnetic resonance imaging) with contrast were normal. Moreover, Electroencephalography (EEG) and LP (Lumbar puncture) findings were normal.

He was drug free for three days and the symptoms disappeared gradually, therefore, his parents requested to discharge him against physician's advice. Two months after the onset of the psychiatric syndrome, he was admitted again. Reason of admission was symptoms such as mood fluctuations, hypersexuality, hypersomnia, visual and olfactory hallucination, which started two days before this admission.

A preliminary diagnosis of bipolar mood disorder with psychotic feature was made according to DSM-IV-TR by psychiatrist. So, H. received lithium 1500 mg/day and Na-Valproate 800 mg/day and propranolol 30 mg/day for two months without satisfactory outcome. He was referred to the Institute of Study for Inborn Errors of Metabolism. Laboratory tests were carried out, through which the following results were found:

Plasma Ammonia: 86 micromol/l (NL:10-47), Plasma Lactate: 16mg/dl (NL<20), Plasma Pyruvate: 0.7 mg/dl (NL:0.3-0.7), Plasma Acyl-Carnitin Profile revealed high C3/C2 ratio: 5.12/12.05=0.42 (NL<0.2), High C3: 5.12 micromol/l (NL:0.98-3.09), High normal C4DC:0.89 micromol/l (NL:0.22-0.89). Plasma Aminoacid Profile revealed high Branched chain aminoacids (Valin, Isoleucin and Leucin) as a result of low level of their metabolic activity. However, Homocystin and methionine were within normal ranges.

So the patient was treated as Methylmalonic Acidemia with L-carnitin 100mg/Kg of body weight and biotin 5 mg BID and oral B₁₂ 1000mic/day. A three year follow-up evaluation indicated a clinically stable patient.

Edwin and his colleague have suggested that a low serum concentration of vitamin B₁₂ may cause mental illness^[4]. It is known that defects in methylmalonyl-CoA mutase or its coenzyme, cobalamin (vitamin B₁₂) will lead to the

* Corresponding Author; Address: Department of Psychiatry, Zare Hospital, Sari-Neka Road, Sari, Iran
E-mail: fmoonesi@mazums.ac.ir

accumulation of methylmalonic acid and a clinical picture of MMA^[2].

Another case report showed acute extrapyramidal symptoms in methylmalonic acidemia and the authors assumed metabolic stroke in MMA. It was believed the accumulation of toxic organ acid metabolites was responsible for these lesions^[5].

The most common phenotype features appear during infancy. Rare patients may present as adolescents or adults with CNS disease^[6]. Our patient had episodes of confusion and mood lability which could be related to metabolic decompensation episodes.

When a patient has been labeled as having a psychiatric illness, other general medical conditions (especially rare diseases) might be ignored. This emphasizes that even a typical psychiatric disorder can actually represent part of the spectrum of an underlying systemic disorder.

Key words: Adolescent; Metabolic Disorder; Methylmalonic Acidemia; Affective Disorder; Psychiatric Disorder

References

1. Mahoney MS, Bick D. Recent advances in the inherited methylmalonic acidemias. *Acta Paediatr Scand* 1987;76(5):689-96.
2. Radmanesh A, Zaman T, Ghannati H, et al. Methylmalonic acidemia: brain imaging findings in 52 children and a review of the literature. *Pediatr Radiol* 2008;38(10):1054-61.
3. Scriver CR, Beaudet AL, Valle S. The metabolic and molecular basis of inherited disease. New York: MC Graw-Hill. 2001.
4. Edwin E, Holten K, Norum KR, et al. Vitamin B₁₂ hypovitaminosis in mental disease. *Acta Med Scand* 1965; 177: 689-99.
5. Heidenreich R, Natowicz M, Hainline BE, et al. Acute extrapyramidal syndrome in methylmalonic acidemia: "Metabolic stroke" involving the globus pallidus. *J Pediatr* 1988;113(6):1022-7.
6. Kanaumi T, Takashima S, Hirose S, et al. Neuropathology of methylmalonic acidemia in a child. *Pediatr Neurol* 2006;34(2):156-9.