

Severe Multiple Necrotizing Fasciitis Complicated by Abdominal Compartment Syndrome in an Infant

Zhao Jing-Chun, MD; Xian Chun-Jing, MD; Kai Shi*,
MD; Yu Jia-Ao, PhD

Burns and Plastic Reconstruction Unit, First Hospital of Jilin
University, Changchun, China

Received: Aug 23, 2012; Accepted: Mar 09, 2013;
First Online Available: Jul 30, 2013

Necrotizing fasciitis (NF) is rare in infants, and abdominal compartment syndrome (ACS) resulting from NF in an infant has not previously been reported. Proper management is challenging, including the optimal time for treatment. The authors report an infant with *Pseudomonas aeruginosa* and *Staphylococcus epidermidis*-mediated NF complicated with ACS and its successful management with combined application of negative pressure wound therapy (NPWT) and split-thickness skin grafts (STSG).

A 7-month old boy initially had a rigid red rash on the back of the left lower leg. His parents did nothing until five days later when a similar rash appeared on the right lower extremity, anterior trunk, right upper arm and face. He also developed a fever (38.5°C- 39.0°C), swelling and ecchymosis on the posterior aspect of both legs, oliguria and anorexia. Both legs were severely swollen. Blood and wound swab cultures yielded *Pseudomonas aeruginosa*. Repeat wound swab two days following admission to the Department of Pediatrics yielded *Staphylococcus epidermidis*.

Immediately, open decompression was performed by pediatric surgeons. However, swelling of both legs did not subside and open decompression was attempted again on the third day following admission. Following day seven of hospitalization, erythema, high fever, dyspnea and oliguria persisted along with soft tissue necrosis occurring in both legs, hypogastrium and both iliac regions, accompanied by massive abdominal distention. Tachypnea (respiratory rate 50/min),

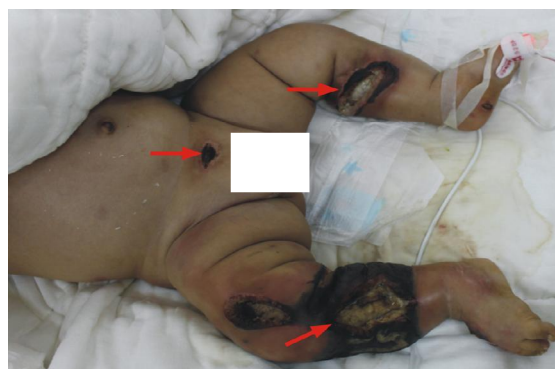


Fig. 1: The necrotic tissue in both legs (circumferential) and hypogastrium (arrows). Both lower limbs including feet were severely swollen.

and cyanosis of the lips and extremities further appeared, and retractions in the suprasternal, supraclavicular and intercostal spaces were noticed. Therefore, the infant was transferred to our department for a definitive treatment.

Abdominal ultrasound revealed gas accumulation in the gastrointestinal tract and minimum fluid. Meanwhile following hospitalization, erythema and swelling of the legs was found to be rapidly progressing (Fig. 1). Fasciectomy and extensive surgical debridement of the two legs, hypogastrium and bilateral iliac regions was performed immediately and hand-made NPWT was applied simultaneously (Fig. 2). Pressure was applied at -50 mmHg continuously for the duration of therapy.

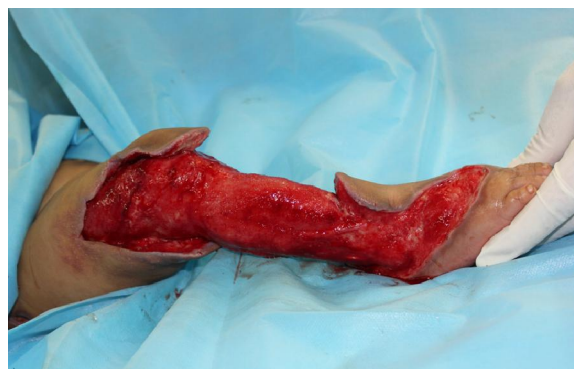

Fig. 2: The defect following surgical debridement. It was not suitable for immediate closure with flap or skin graft

* Corresponding Author; Address: Burns and Plastic Reconstruction
Unit, First Hospital of Jilin University, No. 3302 Jilin Road, Changchun
130031, Jilin Province, China

E-mail: bu_dong007@163.com

Meropenem (0.1 gr, three times a day) was administered intravenously and changed to ceftazidime (0.5 gr, twice a day) upon receiving the antimicrobial susceptibility test report. Albumin transfusion, nutrition support, and continuous gastrointestinal decompression via nasal tube were performed postoperatively. The wound was assessed and dressings were changed on the third day. Abdominal distention, oliguria and fever subsided, the granulation tissue was activated and edema of the right foot and lower leg resolved rapidly with NPWT therapy. STSG was performed when the granulation tissue was fresh and no secretions were observed (Fig. 4). Hand-made NPWT was used again to fix the skin. The skin graft survived intact with a satisfactory outcome. Despite advances in medical and surgical therapy complications of NF could be inevitable. ACS, whether primary or secondary, is also a fatal condition. Management of these two diseases is challenging. NF caused by *Staphylococcus epidermidis*^[1] and *Pseudomonas aeruginosa*^[2], were described earlier but ACS as a complication of NF in a infant has not previously been reported.

ACS is defined as a sustained intra-abdominal pressure (IAP) greater than 20 mmHg that is associated with new organ dysfunction or failure^[3,4]. The diagnosis of ACS in our patient was considered mainly by clinical symptoms. Infant had massive abdominal distention, respiratory compromise, cardiovascular compromise (tachycardia), acute renal insufficiency and evidence of systemic infection. We did not attempt to measure and record IAP since the infant was critically ill and required a since the infant was critically ill and required an emergent operation. A

urinary catheter was inserted only following adequate general anesthesia in the operating room.

Reconstruction of wounds of the infant is more challenging because of special characteristics^[5]. Although numerous studies of NPWT have been published regarding outcomes and methods of therapy used for managing difficult-to-treat pediatric wounds or as an effective adjunct to expedite granulation tissue in wound preparation^[6], no report on combined usage of NPWT with STSG in infants has been found. Wound size of this infant was extensive and across the knee joint. There is also difficulty in immobilization in infants following skin grafting. Due to these reasons, we adopted NPWT that can provide continuous adequate pressure to the recipient site of the skin graft to obtain a higher take rate, and to accelerate the epithelialization of the "blank space" following meshed STSG.

Our report highlights the importance of early diagnosis, treatment with modern techniques including negative pressure therapy, prompt surgical debridement, appropriate antibiotics and aggressive supportive care in successful management and improved survival and cosmetic outcome in children with NF, even those complicated with ACS. However, we also know that it is hard to draw any convincing evidence from a single case and therefore, further research is required to verify the effect of NPWT in management of NF before wide acceptance of this method.

Key words: Necrotizing Fasciitis; Abdominal Compartment Syndrome; Negative-Pressure Wound Therapy; Infant

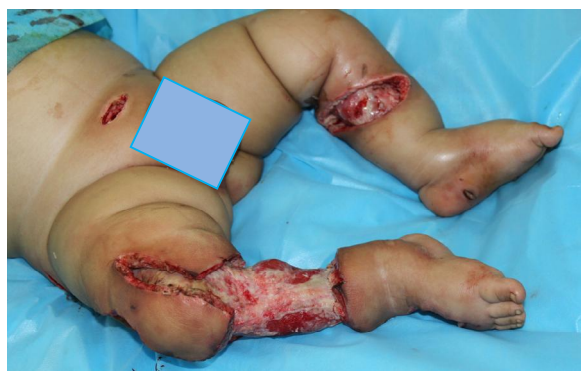

Fig. 4: Healthy granulation tissue of the debrided wound before proceeding with the reconstruction

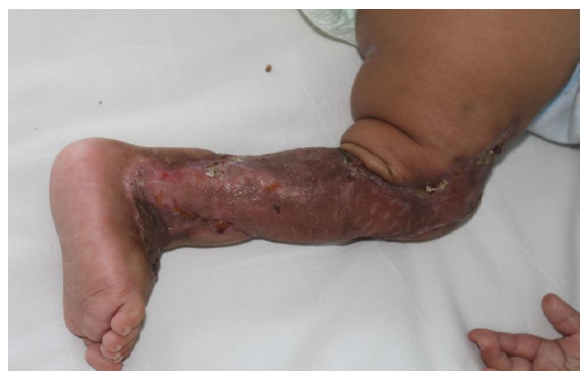

Fig 5.One month following placement of meshed split-thickness skin graft on the right leg

References

1. Peker E, Kirimi E, Tuncer O, et al. Necrotizing fasciitis caused by *Staphylococcus epidermidis* in a neonate with extremely low birthweight. *J Dermatol* 2010;37(7):671-3.
2. Abbo O, Accadbled F, Guitard J, et al. Necrotizing fasciitis due to *Pseudomonas aeruginosa* in immunocompromised children. *Pediatr Blood Cancer* 2010;55(1):213-4.
3. Malbrain ML, Cheatham ML, Kirkpatrick A, et al. Results from the international conference of experts on intra-abdominal hypertension and abdominal compartment syndrome I: definitions. *Intensive Care Med* 2006;32(11):1722-32.
4. Cheatham ML, Malbrain ML, Kirkpatrick A, et al. Results from the international conference of experts on intra-abdominal hypertension and abdominal compartment syndrome II: recommendations. *Intensive Care Med* 2007;33(6): 951-62.
5. Baharestani MM. An overview of neonatal and pediatric wound care knowledge and considerations. *Ostomy Wound Manage* 2007; 53(6):34-6.
6. Aydin U, Ozgenel Y, Kanturk R. Vacuum-assisted closure therapy in newborn gangrene. *J Plast Reconstr Aesthet Surg* 2010;63(3):e277-9.

Cytokine Gene Polymorphisms in Childhood Dilated Cardiomyopathy: Interferon- gamma, Tumor Necrosis Factor-alpha and Transforming Growth Factor - beta 1 Genes Are Associated with the Disease in Turkish Patients

Sibel Oguzkan Balci*¹, PhD; Nilgun Col-Araz², MD; Osman Baspinar³, MD; Tugce Sever¹, MSc; Ayse Balat⁴, MD; Sacide Pehlivan¹, PhD

1. Department of Medical Biology and Genetics, Faculty of Medicine, University of Gaziantep, Turkey
2. Department of Pediatrics, Faculty of Medicine, University of Gaziantep, Turkey
3. Department of Pediatric Cardiology, Faculty of Medicine, University of Gaziantep, Turkey
4. Department of Pediatric Nephrology, Faculty of Medicine, University of Gaziantep, Turkey

Received: Marr 19, 2013; Accepted: Jun 28, 2013;
First Online Available: Aug 14, 2013

Dilated cardiomyopathy (DCM) is a cardiac muscle disease with reduced left ventricular systolic function^[1]. Myocardial inflammation is the most common mechanism in the pathogenesis of cardiomyopathy in which cytokines may play an

important role^[2]. The objective of this study was to investigate the associations between tumor necrosis factor-alpha (TNF- α , -308), transforming growth factor-beta 1 (TGF- β 1, +10, +25), interleukin-10 (IL-10, -1082, -819, and -592), interleukin-6 (IL-6, -174), interferon-gamma (IFN- γ , +874) gene polymorphisms and DCM.

Sixteen children with DCM (3 months-13 years) and 21 healthy controls were tested for the cytokine genes with polymerase chain reaction-sequence-specific primers (PCR-SSP). In our results, TNF- α (-308) A allele was higher in DCM ($P=0.03$). The frequency of TNF- α (-308) GG genotype (low expression) was significantly decreased in DCM ($P=0.02$). The children with DCM had significantly higher frequencies of IFN- γ (+874) TT genotype (high expression) and allele T while TA genotype (intermediate expression) was lower in patients ($P=0.003$, $P=0.01$ and $P=0.04$, respectively). Haplotype analyses showed that TT/GG and TC/GG haplotypes of TGF- β 1 (high expression) were significantly decreased while TC/GC, CC/GG and TT/GC (intermediate expression) haplotypes were increased ($P=0.01$ and $P=0.04$, respectively). There was no association between IL-6 and IL-10 genotypes/haplotypes and DCM ($P>0.05$).

TNF- α is a strong proinflammatory and immunomodulatory cytokine that intervenes inflammatory diseases and is produced by activated macrophages^[3]. Frequency of TNF- α allele A was found high in DCM^[4]. TNF- α allele A (-308) was found over-expressed in patients with end-stage non-ischemic myocardial dysfunction^[5]. Tired et al did not find any association between TNF- α (-308) polymorphism and DCM^[6]. In our study, allele A of TNF- α (-308) gene was found susceptible to DCM, while GG genotype of TNF- α (-308) showed a protective effect against the disease.

The production or activities of several cytokines are modulated by IFN- γ ^[7]. The AA homozygosity of IFN- γ (+874) T/A polymorphism was associated with poor prognosis in idiopathic DCM in older patients^[2]. IFN- γ protected against the development of severe chronic myocarditis, pericarditis, and DCM after Coxsackievirus B3 infection by reducing mast cell degranulation, and the profibrotic cytokines (IL-4, IL-1 β , TGF- β 1) in the heart^[8]. In our study, the high expression of IFN- γ was found susceptible to DCM. We

* Corresponding Author; Address: Department of Medical Biology and Genetics, University of Gaziantep, 27310 Gaziantep, Turkey
E-mail: oguzkan@gantep.edu.tr