

Protective Temporary Vesicostomy for Upper Urinary Tract Problems in Children: A Five-Year Experience

Mohsen Rouzrokh¹, MD; Alireza Mirshemirani^{*1}, MD; Ahmad Khaleghnejad-Tabari¹, MD;
Naser Sadeghian¹, MD; Leily Mohajerzadeh¹, MD; Maesomh Mohkam², MD;

1. Pediatric Surgery Research Center, Shahid Beheshti University of Medical Sciences, Tehran, Iran
2. Pediatric Nephrology Research Center, Shahid Beheshti University of Medical Sciences, Tehran, Iran

Received: Oct 23, 2012; Accepted: Jun 27, 2013; First Online Available: Nov 09, 2013

Abstract

Objective: Temporary vesicostomy is a urinary diversion procedure for patients with upper urinary tract (UUT) dilatation, secondary to bladder outlet obstruction or dysfunction. The aim of this study was to evaluate our experience in children undergoing such diversion, analyzing its efficacy to prevent urinary tract infection (UTI), improve or resolve hydronephrosis, stabilize or improve kidney function and restore the health of UUT.

Methods: In this retrospective study, patients who had vesicostomy by Blocksom technique due to bladder outlet obstruction or dysfunction were evaluated in Mofid Children's Hospital (in Tehran) from March 2007 to March 2012. The reason for applying this procedure was failure in clinical treatment. Data regarding gender, age, diagnosis, time of any surgical intervention, associated anomalies, primary/secondary complications and mortality were collected using a questionnaire, and evaluated by giving a grade that ranged from 0 (worst) to 10 (best) based on Lickert's scale.

Findings: From a total number of 53 patients, (88.7% male and 11.3% female) with a mean age of 225 days, 66% had posterior urethral valve and 16 (30%) neurogenic bladder. UTI was present in all cases, hydronephrosis in 52 (98.1%), and vesico-ureteral reflux only in 45 (84.9%) patients. Valve ablation was performed in 17 cases, and clean intermittent catheterization in 14 patients which were unsuccessful. We performed vesicostomy in all patients. Mortality rate was 7.5%. Vesicostomy was closed in 35 patients. Cure rate was 85% in UTI, 82.7% in hydronephrosis, 80% in VUR, and 86.5% in kidney function.

Conclusion: Vesicostomy is a simple procedure that protects upper urinary tract, decreases hydronephrosis, and improves kidney function. The procedure is well tolerated and reversible, with less complication and should be considered in children in whom conservative and medical treatment has failed.

Iranian Journal of Pediatrics, Volume 23 (Number 6), December 2013, Pages: 648-652

Key Words: Vesicostomy; Urinary Tract Infection; Protection; Voiding Dysfunction; Vesico-Ureteral Reflux

Introduction

Voiding dysfunction either functional or neurogenic in children may cause a challenge for the pediatricians and pediatric nephrologists^[1].

When voiding dysfunction is detected, attempting to preserve the upper urinary tract (UUT) by reducing episodes of urinary tract infection (UTI) and promotion of continence are in priorities^[1]. Treatments include physiotherapy, Clean

* Corresponding Author;

Address: Pediatric Surgery Research Center, Shahid Beheshti University of Medical Sciences, Tehran-Iran

E-mail: almirshemirani@gmail.com

© 2013 by Pediatrics Center of Excellence, Children's Medical Center, Tehran University of Medical Sciences, All rights reserved.

Intermittent Catheterization (CIC), and anti cholinergic drugs; surgery is considered if medical treatment has failed^[2]. Vesicostomy in myelodysplastic children is effective in preventing/resolving the deleterious consequences of a hostile bladder^[2,3]. In early infancy when preventing renal scarring and loss of kidney function is vital, temporary diversion by surgery is the first treatment option to permit maturing^[4]. The use of vesicostomy in children was first proposed by Michie and colleagues and Duckett in 1960s^[5]. Neonates with posterior urethral valve (PUV) and non-responders to catheter drainage also are candidates for a vesicostomy procedure^[6,7]. If urine drainage is expected to last longer than 2-4 weeks, surgical drainage using a vesicostomy is preferable^[7,8]. So, lower urinary tract diversion is the first step in these patients, but if decrease in kidney function or recurrent UTI occurs after the procedure, an upper tract diversion is considered^[8,9]. The aim of this study was to evaluate our experience in children undergoing such diversion, analyzing its efficacy to prevent UTI, improve or resolve hydronephrosis, stabilize or improve kidney function and restore the health of UUT.

Subjects and Methods

In this retrospective study, patients who had vesicostomy using the Blocksom^[10] technique due to bladder outlet obstruction or dysfunction were evaluated in Mofid Children's Hospital from March 2007 to March 2012. The reason for applying this procedure was failure in clinical treatment defined by recurrent UTI, stable high degree vesico-ureteral reflux (VUR), worsening hydronephrosis and renal function despite using CIC and anticholinergic drugs. All patients received prophylactic antibiotic after vesicostomy. In this technique the vesicostomy is created from the bladder dome to minimize the risk of prolapse. We performed ultrasonography (US), voiding-cystourethrography (VCUG), and static renal scintigraphy, and lumbo-sacral magnetic resonance imaging (MRI) in myelodysplastic cases. Creatinine clearance was measured based on Schwartz formula, and urine cultures were

obtained before surgery. Urine culture and sonography checked every three months and diethylenetriaminepentaacetic acid (DTPA) and dimercaptosuccinic acid (DMSA), if necessary, every six months during the follow-up. Reduction in grade of hydronephrosis or VUR was considered as improvement, and absence of disorders on evaluation was considered as cure. A standard questionnaire was completed for all patients which included gender, age, diagnosis, time of any surgical intervention, associated anomalies, primary/secondary complications, mortality, and researchers at the last follow up carried out the cure global score of patients according to assessment of clinical and paraclinical observations ranged from 0 (worst) to 10 (best) based on Lickert's scale. Descriptive statistical analysis was performed by SPSS16 software.

Findings

From a total number of 53 patients, 47 (88.7%) were male and 6(11.3%) female, with a mean age of 225 days (range, 2 days to 6 years) (Table 1). Thirty five (66%) cases had PUV and 16 (30%) neurogenic bladder (NGB) (Fig. 1). Mean follow-up was 35.0±19.3 months (range, 6-60 months). UTI was present in all cases (100%), hydronephrosis in 52 (98.1%) patients and VUR in 45 (84.9%) patients. The most common associated anomalies were kidney disease (15%), meningocele (5.6%), hernia and patent ductus arteriosus (PDA) (each 3.7%) and 36 patients (68%) had no anomalies. We performed vesicostomy in all patients. Complications related to vesicostomy were dermatitis in 10 cases, mild stomal stenosis in 3 cases and mucosal prolapse in 2 cases. 33 patients had renal failure. All cases had high level of

Table 1: Age distribution of patients

Age groups	n	%
0 - 1 month	26	49
1.1 month - 1 year	16	30
1.1 - 3 years	9	17
3.1 - 5 years	1	2
5.1- 7 years	1	2

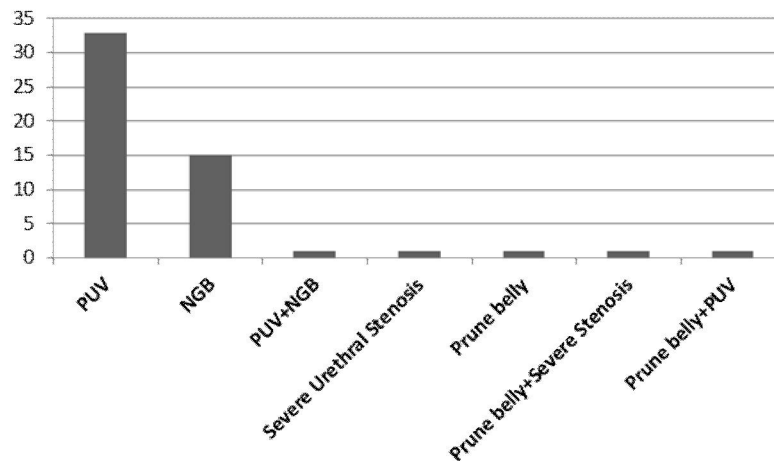


Fig. 1: Diagnosis in our study group.
PUV: posterior urethral valve; NGB: neurogenic bladder

creatinine (1.5-5.9), 90.5% decreased to normal after vesicostomy and during follow-up. Mean cure global score was 7.1 ± 2.7 (range 0-10). Cure rate was 85 % in UTI, 82.7% in hydronephrosis, 80% in VUR, and 86.5% in kidney dysfunction (Table 2), and mortality rate was 7.5% (due to severe renal failure).

Discussion

Vesicostomy is considered a temporary urinary diversion. In our study more than 90% had PUV and NGB. Indication for applying this surgical procedure was failure in clinical treatment defined by worsening hydronephrosis, recurrent UTI, stable high-degree VUR, worsening kidney function, and noncompliance with CIC and anticholinergics. In this regard vesicostomy is proven in many studies to be useful in upper tract dilatation due to neurogenic bladder dysfunction^[5,6]. Bruce et al^[11] reported on vesicostomy in 24 children with hostile bladder,

and the result within 2 years was successful in 23 cases. Mandell J et al^[12] used vesicostomy in 10 infants with neurogenic bladder dysfunction, improvement was seen in all cases, and the median follow-up was only 24 months. Queipta Zaragoza JA, et al^[13], studied 43 children with NGB with vesicostomy, and observed 100% improvement in hydronephrosis and 90% in kidney function^[14]. Recent studies have shown that long-term results are effective even in 15 high-risk children with spina bifida^[4]. Our study showed 80% cure rate in hydronephrosis and 80% in VUR within 35 months follow-up.

Hutchinson JC, et al^[15] published the 13-year results of 18 patients treated with vesicostomy with a mean age of 2.6 years, which showed improvement in 89% of patients. The correct and successful management is valve ablation with antibiotic coverage, and in case of ureteric reflux it is continued for at least 3 years. All patients should have urodynamic studies, and in case of incomplete voiding CIC should be carried out as described in Westney^[16], and if improvement in renal function and anatomy of upper urinary tract is gained, there is no need for surgical

Table 2: Cure rate of hydronephrosis and vesico-ureteral reflux in our study

Disease	Outcome	
	Cure	Renal Failure
Urinary Tract Infection	45 (85%)	8 (15%)
Hydronephrosis	43 (82.7%)	9 (17.3%)
Vesico-ureteral reflux	36 (80%)	9 (20%)
Kidney dysfunction	45 (86.5%)	7 (13.5%)

intervention, but if improvement does not take place temporary diversion is indicated^[17-24]. We had 33 cases of PUV in our study, who were managed by valve ablation/non ablation (due to non-availability of adequate size resectoscope) and as medical treatment was unsuccessful, we performed vesicostomy as a temporary diversion, and the result showed cure rate of 85% in UTI, 82.7% in hydronephrosis, 80% in VUR and 86.5% in kidney function and overall cure rate was 83.5%. Choudhury SR et al^[6], showed that the growth and nutrition of PUV patients on vesicostomy appears to be satisfactory. Hutton, K^[22] concluded that temporary vesicostomy is still a reasonable option for PUV of premature neonates. Podesta ML et al^[25] reported their study about bladder functional outcome after delayed vesicostomy closure. Following vesicostomy, an objective improvement of hydronephrosis ranging from 85% to 100% and stabilization of kidney function, evaluated by scintigraphy, of around 88% have been detected^[13,16]. Queipta Zaragoza JA^[13] observed 100% in improvement of hydronephrosis, and 90% in stabilization of kidney function, but these were improved in our study with the rate of 82.7% and 86.5% respectively. In case of decreasing kidney function we consider the upper tract diversion as well. The complications of vesicostomy in our study were dermatitis, mild stomal stenosis and mucosal prolapse, but there were no cases of urinary tract lithiasis in our patients, such as in Prudente AP's study^[1]. Mortality rate in PUV patients has significantly decreased in recent studies, and some have reported it even less than 5% or lower^[21]. mortality rate in our series was 7.5%.

Conclusion

Vesicostomy is a simple surgery that protects upper urinary tract, decreases hydronephrosis, UTI, VUR, and improves kidney function. The procedure is well tolerated and reversible, with few complications and should be considered in children in whom conservative and medical treatment has failed

Acknowledgment

This study was financially supported by the office of the Vice Chancellor for Clinical Research Development Center (CRDC) of Mofid Children's Hospital.

Conflict of Interest: None

References

1. Prudente A, Reis OL, Franca Rde P, et al. Vesicostomy as a protector of upper urinary tract in long-term follow-up. *Urol J* 2009;6(2):96-100.
2. Lee MW, Greenfield SP. Intractable high-pressure bladder in female infants with spina bifida: clinical characteristics and use of vesicostomy. *J Urology* 2005;65(3):568-71.
3. Morrisroe SN, O'Connor RC, Nanigian DK, et al. Vesicostomy revisited: the best treatment for the hostile bladder in myelodysplastic children? *BJU Int* 2005;96(3):397-400.
4. Michie AJ, Borns P, Ames MD. Improvement following tubeless suprapubic cystostomy of myelomeningocele patients with hydronephrosis and recurrent acute pyelonephritis. *J Pediatr Surg* 1966;1(4):347-52.
5. Duckett JW Jr. Cutaneous vesicostomy in childhood: the Blocksom technique. *Urol Clin North Am* 1974; 1(3):485-95.
6. Choudhury SR, Chadha R, Puri A, et al. Clinical spectrum of posterior urethral valve obstruction in children. *J Indian Assoc Pediatr Surg* 2003;8(3):148-52.
7. Ikuerowo SO, Balogun BO, Akintomide TE, et al. clinical and radiological characteristics of Nigerian boys with PUV. *Pediatr Surg Int* 2008;24(7):825-9.
8. Ikuerowo SO, Omisano OA, Balogun BO, et al. Mohan's valvotome for the ablation of PUV. *J Pediatr Urol* 2009;5(4):279-82.
9. Tarcan T, Bauer S, Olmedo E, et al. Long-term follow-up of newborn with myelodysplasia and normal urodynamic findings: is follow-up necessary? *J Urol* 2001;165(2):564-7.
10. Blocksom BH Jr. Bladder pouch for prolonged tubeless cystostomy. *J Urol* 1957;78(4):398-401.
11. Bruce RR, Gonzales ET. Cutaneous vesicostomy: a useful form of temporary diversion in children. *J Urol* 1980;123(6):927-8.
12. Mandell J, Bauer SB, Colodny AH, et al. Coetaneous vesicostomy in infancy. *J Urol* 1981;126(1):92-3.
13. Queipta Zaragoza JA, Dominguez Hinarejos C, Serrano Durbá A, et al. Vesicostomy in children. our experience with 43 patients. *Acta Urol Esp* 2003; 27(1):33-8.

14. Mingin GC, Baskin LS. Surgical management of the neurogenic bladder and bowel. *Int Braz J Urol* 2003; 29(1):53-61.
15. Hutcheson JC, Cooper CS, Canning DA, et al. The use of vesicostomy as permanent urinary diversion in the child with myelomeningocele. *J Urol* 2001; 166(6):2351-3.
16. Westney OL. The neurogenic bladder and incontinent urinary diversion. *Urol Clin North Am* 2010;37(4):581-92.
17. Sato Y, Kitagawa H, Pringle KC, et al. Effect of early vesicostomy in obstructive uropathy on bladder development. *J Pediatr Surg* 2004;39(12):1849-52.
18. Bradshaw CJ, Gray R, Downer A, et al. Button vesicostomy; 13 years of experience. *J Pediatr Urol* 2013; In Press.
19. Malik MA, Javad Sial SH, Iqbal Z, et al. Posterior urethral valves. *Professional Med J* 2005;12(4): 473-8.
20. Mackinnon AE. Posterior urethral valves: the value of high diversion. *J Indian Assoc Pediatr Surg* 2005; 10(3):158-63.
21. Sudarsanan B, Nasir AA, Puzhankara R, et al. Posterior urethral valves: a single center experience over 7 years. *Pediatr Surg Int* 2009; 25 (3):283-7.
22. Hutton KAR. Management of posterior urethral valves. *Curr Pediatr* 2004;14(7):568-75.
23. Caione P, Nappo SG. Posterior urethral valves: Long-term outcome. *Pediatr Surg Int* 2011;27(10):1027-35.
24. Mirshemirani A, Khaleghnejad A, Rouzrokh M, et al. Posterior urethral valves: a single center experience. *Iran J Pediatr* 2013;23(5):531-5.
25. Podesta ML, Ruarte A, Herrera M, et al. Bladder functional outcome after delayed vesicostomy closure and antireflux surgery in young infants with primary vesico-ureteric reflux. *BJU Int* 2001;87(6):473-9.