

groups: those who have chicken meat only allergy^[1,3], and a second group, a subset of 'bird-egg syndrome' with allergies to chicken meat, egg yolks, and other bird allergens from serum and feathers^[4,5].

The most reported symptoms of allergy to chicken meat are urticaria^[6], oral allergy syndrome^[7], and non-IgE mediated colitis^[8]. A few cases of anaphylaxis due to chicken meat have been reported: allergy to chicken meat only beginning from childhood in two cases^[6,9]; allergy to chicken meat only in two adults^[1,3]; a single case report of a child with bird-egg syndrome^[4]. Our case represents the third reported case of chicken meat anaphylaxis in children with no allergies to eggs or feathers.

In our patient, SPTs were found to be positive with commercial allergenic extracts of egg white, egg yolk, and chicken. However, he was able to tolerate eggs. His SPT with the feather mixture was negative. Gal d 5 (alpha-livetin) is believed to be the causative antigen of bird-egg syndrome^[10]. Although IgE reactivity against Gal d 5 can be reduced 88% by heating^[1], skin PPTs performed with both raw and cooked chicken and turkey meat were positive in our patient.

Recently, muscle alpha-parvalbumin and myosin light chain 1 (MLC) have been identified as new allergens in chicken meat allergy^[3]. Unfortunately, we could not carry out a further investigation to determine allergenic components such as immunoblotting or mass spectrometry. However, the patient's tolerance of eggs led us to believe that allergens such as MLC might be the responsible antigens in our patient's case.

The causative antigen in chicken meat only allergy is not known for certain. Antibiotics given to chicken via chicken feed have been thought to be responsible^[1]. However, our patient had no known antibiotic allergy.

The patient had never before consumed turkey. However, since IgE binding to alpha-parvalbumin and myosin has been identified in turkey meat^[3], we advised him not to eat turkey meat due to cross-reactivity.

We have presented this case because of the rarity of allergy to chicken meat and because we wish to attract attention to chicken meat allergy without bird-egg syndrome.

Key words: Chicken; Meat; Anaphylaxis; Eggs; Feathers

References

1. Zacharisen MC. Severe allergy to chicken meat. *WMJ* 2006;105(5):50-2.
2. Besler M, Restani P. Chicken meat (*Gallus domesticus*). *Internet Symposium on Food Allergens* 2001;3(4):193-201.
3. González-Mancebo E, Pastor C, González-de-Olano D, et al. Identification of allergens in chicken meat allergy. *J Investig Allergol Clin Immunol* 2011;21(4):326-7.
4. Cheikh Rouhou S, Bachouch I, Racil H, et al. Anaphylaxis due to chicken meat. *Rev Mal Respir* 2012;29(1):98-100.
5. Nevot Falcó S, Casas Ramisa R, Lleona Bellfill R. Bird-egg syndrome in children. *Allergol Immunopathol (Madr)* 2003;31(3):161-5.
6. Cahen YD, Fritsch R, Wuthrich B. Food allergy with monovalent sensitivity to poultry meat. *Clin Exp Allergy* 1998;28(8):1026-30.
7. Vila L, Barbarin E, Sanz ML. Chicken meat induces oral allergy syndrome: a case report. *Ann Allergy Asthma Immunol* 1998;80(2):195-6.
8. Vandenplas Y, Edelman R, Sacre L. Chicken -induced anaphylactoid reaction and colitis. *J Ped Gastro Nutrition* 1994;19(2):240-1.
9. Liccardi G, Szepfalusi Z, Noschese P, et al. Allergy to chicken meat without sensitization to egg proteins: a case report. *J Allergy Clin Immunol* 1997;100(4):577-9.
10. Quirce S, Marañón F, Umpiérrez A, et al. Chicken serum albumin (Gal d 5*) is a partly heat-labile inhalant and food allergen implicated in the bird-egg syndrome. *Allergy* 2001;56(8):754-62.

Unusual Presentation of Congenital Neuroblastoma as Persistent Respiratory Distress and Fever from Age of 13 Days in an Infant: A Case Report

Deepak Sharma; Jaivinder Yadav; Eva Garg

Department of Pediatrics, PtBDS PGIMS Rohtak, Haryana, India

Received: Sep 17, 2013; Accepted: Mar 09, 2014;
First Online Available: Apr 15, 2014

Dear Editor

Neuroblastoma, an embryonal tumor arising from the sympathetic nervous system, is the most common neonatal malignancy that accounts for >20% of neonatal cancers^[1]. The most common location for neuroblastoma to originate (i.e., the primary tumor) is on the adrenal glands but

* Corresponding Author; Address: Department of Pediatrics, Pt.B.D.S PGIMS, Rohtak, Haryana, India
E-mail: dr.deepak.rohtak@gmail.com

primary cancer originating from lung is very rare. We report a case of newborn who was referred to us as case of persistent pneumonia but was diagnosed as primary congenital neuroblastoma of lung.

Baby Y, female infant was referred at age of 23 days with difficulty in breathing from age of 13 days. The infant was born by normal vaginal delivery with weight of 2.6 kg and Apgar of 7/8/8. Ante-natal period was uncomplicated with normal scans. Infant had fever (101° to 102° F) on and off from 13 days of age and respiratory distress for which baby was admitted in hospital. Baby received injectable antibiotics in referral NICU for 10 days. Baby was referred to us in view of persistence of respiratory distress and X-ray findings. At admission, the infant weighed 2.5 kg, had a temperature of 37.5°C, HR 148/min, RR 50/min, BP 64/42 mm Hg, mild to moderate subcostal and intercostal retractions, air entry decreased on right side, dusky peripheries, SpO₂ 65% on room air, SpO₂ 93% with oxygen by hood with flow of 5 liters/min, liver 2cm below costal margin, spleen 1cm below costal margin, pedal edema. Blood counts revealed neutrophilic leukocytosis (total count 18600/mm³, neutrophils 66%), C-reactive protein -41.4 mg/l. Chest X-ray showed right upper lobe heterogeneous opacity and distal consolidation with right lower lobe showing patchy consolidation (Fig. 1).

Ultrasonography showed hepatosplenomegaly in abdomen and in chest showing intrathoracic soft tissue mass lesion in right paratracheal and upper lobe with distal consolidation of middle and lower lobe. The infant was started on intravenous antibiotics and supportive care. In view of persistence of respiratory distress repeat X-ray was done after 1 week which didn't show any

improvement (Fig. 2). Chest CT scan showed posterior and apical segments of right upper lobe having consolidation without air bronchogram with small central cavitation. Anterior segments of right upper lobe and right middle lobe lateral segment showed nodular lesions. Right lower lobe basal segments showed areas of consolidation with curvilinear air lucencies with intercavitary bodies. Left lower lobe showed multiple confluent nodular lesions with curvilinear air lucencies (Fig 3). CECT chest showed possibility of metastatic neuroblastoma and Fine needle aspiration cytology (FNAC) and biopsy was planned. FNAC was done which revealed moderate cellular cells which were mostly acute inflammatory cells with atypical tumor cells. Individual cells were round to polygonal cells having scanty to moderate amount of eosinophilic cytoplasm with anisopoikilocytosis with hyperchromasia, high nuclear to cytoplasmic ratio with prominent nucleoli. Biopsy showed small, round, blue cell tumor cells with high nuclear to cytoplasmic ratio and presence of Homer-Wright pseudo rosettes. Baby was started on chemotherapy but infant succumbed to death after 10 days of starting treatment.

Congenital neuroblastoma is defined as neuroblastoma identified within a month of birth^[1]. Neuroblastoma is slightly more common in boys than in girls with a male to female sex ratio of 1.2:1^[2]. Neuroblastoma is especially unique because of its varied presentation in the young. The tumor has been detected as an unexpected finding in the fetus either as a cystic or solid mass above upper pole of the kidney^[3,4].

Neuroblastoma is characterized with densely cellular, primitive, "small blue-cell tumor" appearance. Undifferentiated neuroblastoma may

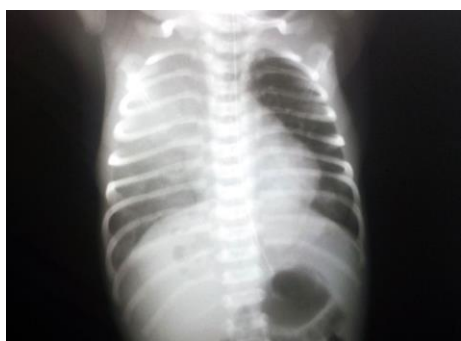

Fig. 1: Chest X-ray at admission

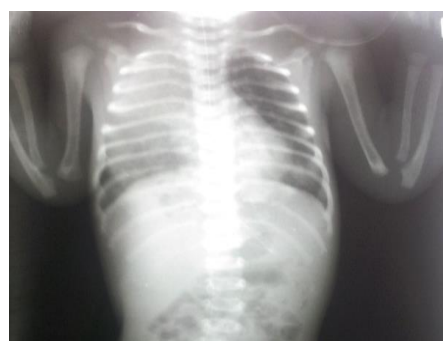

Fig. 2: Chest X-ray after treatment for 1 week

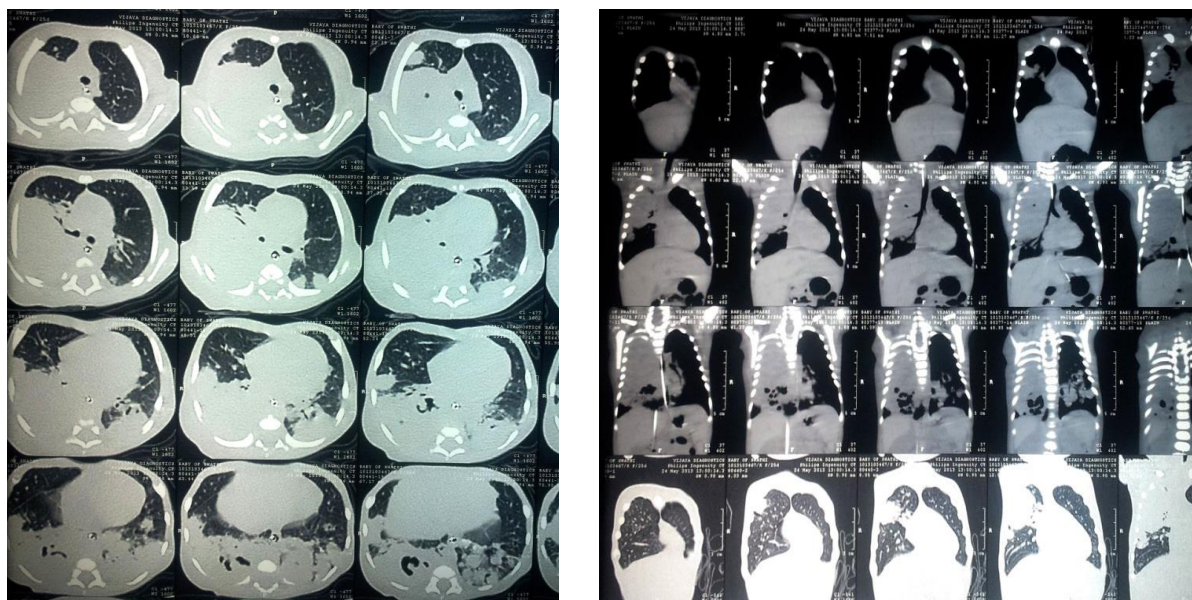


Fig. 3: Multiple confluent nodular lesions with curvilinear air lucencies in Chest CT scan

be difficult to distinguish by electron microscopy from other small-cell malignant tumors. The predominance of blue staining is due to the fact that the cells consist predominantly of nucleus, thus they have scant cytoplasm^[5]. The tumor cells are reactive for neuron specific enolase (NSE), synaptophysin, neurofilament, and focally positive for S-100 protein and they stain negative for desmin, actin, leukocyte common antigen, cytokeratin, and the Ewing antigen^[6]. Urinary catecholamines are raised in >90% of neuroblastomas but only in 33% of perinatal neuroblastomas. I¹³¹ or I¹²³ (preferred) meta-iodo benzyl guanidine (MIBG) scintigraphy is highly sensitive and specific. The treatment of neuroblastoma depends on the stage, and it includes surgical excision, multiagent chemotherapy, and bone marrow transplantation^[7].

Key words: Congenital Neuroblastoma; Pneumonia; Round Cell Tumors

References

1. George TI. Malignant or benign leucocytosis. *Hematology Am Soc Hematol Educ Program* 2012; 2012:1475-84.
2. Halkes CJ, Dijkstra HM, Elkman Rooda SJ, et al. Extreme leucocytosis: not always leukaemia. *Neth J Med* 2007; 65(7):248-51.
3. Zeng Q, Wu Y, Zhan Y, et al. Leukemoid reaction secondary to hypersensitivity syndrome to phenobarbital: a case report. *Int J Clin Exp Pathol* 2013; 6(1):100-4.
4. Moritake H, Ikeda T, Manabe A, et al. Cytomegalovirus infection mimicking juvenile myelomonocytic leukemia showing hypersensitivity to granulocyte-macrophage colony stimulating factor. *Pediatr Blood Cancer* 2009; 53(7):1324-6.
5. Lanzkowsky P. *Manual of Pediatric Hematology and Oncology*. Fifth edn. Elsevier 2011; pp 272-320.