

# Descriptive study of management of palatal fistula in one hundred and ninety-four cleft individuals

**Jyotsna Murthy**

Department of Plastic Surgery, Sri Ramachandra Medical College and Research Institute, Porur, Chennai, India

**Address for correspondence:** Dr. Jyotsna Murthy, Department of Plastic Surgery, Sri Ramachandra Medical College and RI, Porur, Chennai-600 116, Tamil Nadu, India. E-mail: murthyjyotsna@gmail.com

## ABSTRACT

**Objective:** Palatal fistula is a significant complication following cleft palate repair. The guidelines of management of the palatal fistula is dependent on the type of cleft, site of fistula, condition of surrounding tissue and associated problem. We studied the management and outcome of 194 cleft palate fistula in our institute. **Design:** We present the descriptive hospital-based study of management of palatal fistula in 194 cleft patients. We have excluded all the syndromic children and children whose anterior palate was not operated as per protocol. **Settings:** Of 194 cleft palate fistula, 37 had palate repair in our hospital and 157 were referred with fistula following palate repair. The patients were evaluated by interdisciplinary team and plan of management was decided. **Result:** Various parameters like types of cleft, site of fistula and management of fistula were studied in all the patients. Fifty-two percent were in unilateral CLP and 30% in bilateral CLP because unilateral CLP is the commonest type of cleft. Postalveolar and hard palate region contributing to 67% of all fistulae, followed by junctional in (9%). Seventy-two percent of fistula were amenable for repair by local available tissue, 28% needed tongue flap due to shortage of tissue. Minor numbers have failure of procedure for fistula closure needing further management. **Conclusions:** This descriptive study present analysis of management of fistula in our institute. It also reinforces that patient with bilateral cleft lip and palate more likely to have shortage of local tissue needing the local flaps like tongue flap compare to other cleft types. The surgical management of fistula can be combined to tackle the associated problems.

## KEY WORDS

Palatal fistula; tongue flap; post alveolar fistula

## INTRODUCTION

One of the expected outcomes of palate repair is to achieve complete partition between nasal and oral cavity in addition

to good speech. Any failure of achieving complete structural integrity of palate is labeled as an oronasal (palatal) fistula with persistent passage between oral and nasal cavity. The term, palatal fistula, is normally used for residual non-repaired cleft palate or result of breakdown of repaired palate.<sup>[1]</sup>

Every visible palatal fistula does not need surgical repair. The indications for a fistula repair depend on the associated symptoms, which are in turn related to the size and location of the fistula. The common symptoms which have been extensively discussed in the literature are: 1. Nasal emission causing speech distortions, 2. Leakage of fluid

Access this article online	
Quick Response Code: 	Website: www.ijps.org
	DOI: 10.4103/0970-0358.81447

and food into the nasal cavity leading to poor oral hygiene and foul smell. The timing of the fistula repair depends on symptoms like nasal regurgitation, effect on speech and concerned of the patient. It is generally agreed that fistulae causing disturbances in speech should be repaired as soon as possible. A fistula leading to significant regurgitation of fluid/food into the nose, resulting in inflammation of nasal lining and malodor also needs to be repaired early. However, the repair of a small fistula with no effect on speech and occasional regurgitation of fluid/food into nose, can be delayed to be combined with other procedures. Many attempts have been made to classify palatal fistulae according to the site and is the best presented by Cohen *et al.*<sup>[2]</sup> Smith *et al.*, presented modified classification and presented fistula in VII categories according to its site with more details.<sup>[3]</sup>

The speech evaluation by the speech pathologist is essential to diagnose if the fistula is contributing to the speech problems. The speech pathologist also provides information regarding the associated Velo-pharyngeal incompetence (VPI) which may or may not be due to the fistula after closing the fistula with chewing gum temporarily.<sup>[4]</sup> Similarly, evaluation and suggestions by an orthodontist are essential for a perialveolar fistula. In certain cases, orthodontic treatment e.g., expansion of arches and removal of deciduous or supernumerary teeth may be necessary. This additional information is vital for combining fistula closure with another procedure like VPI correction, alveolar bone graft or lip revision. The factors which need to be studied and examined before fistula repair are presented in Table 1. The concerns and complaints of the patients need to be elicited in detail and to be taken into consideration while planning the management.

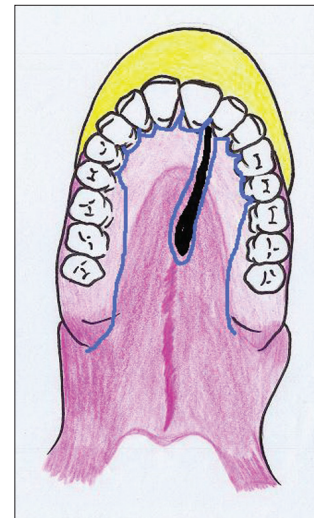
## MATERIALS AND METHODS

We analyzed the management of palatal fistula in 194 fistulae in our institute since 2002. Of total 194 fistulae,

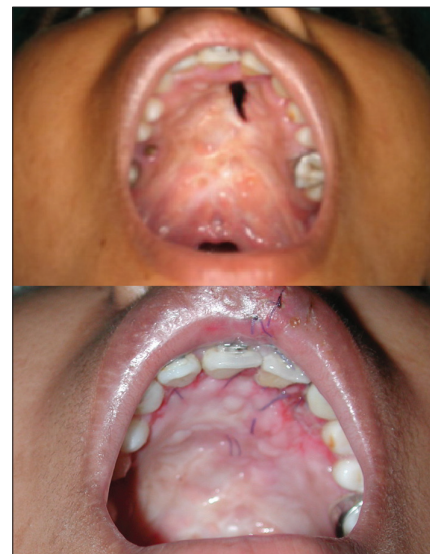**Table 1 : Evaluation of fistula**

Age of patient
Complaints of patients
Site/Size of defect
Scarring/previous surgeries
Availability of soft tissue
Effect on oral hygiene
Comments of speech pathologist/orthodontist
Feasibility of providing natural barrier
Purpose of Repair

37 patients had palate repair in our institute, 157 patients were referred to our institute for fistula repair. Of referral patients, 80% were either detected during camps in rural area or referred by the health workers from rural areas and 20% approached directly to our center for help. Our data were collected as alveolar (which also includes prealveolar and postalveolar), hard palate, combined postalveolar extending to hard palate, junction, soft palate and combination of hard and soft palate fistula. In view of this being a retrograde study, we presented the data according to these sites mentioned above. A small uvular notching or bifid uvula was not considered as fistula, but uvular breakdown was considered as soft palate fistula because majority of them will need repair of soft palate. Of 2387 palate repairs in our institute, 2067 patients were followed



**Figure 1a:** Incision for alveolar extension palatoplasty



**Figure 1b:** Fistula repair by alveolar extended palatoplasty

up at least once postoperatively within 1 year and 75 had fistula. Out of 75 patients, we have excluded 38 patients with small, non-symptomatic postalveolar defect which was not repaired as the protocol (no anterior palate repair with lip repair) in our institute between 2001 and 2003. However, the significant postalveolar fistulae in these patients which needed closure were considered as a fistula and included in the study. This protocol was changed thereafter due to higher percentage of postalveolar fistula needing closure. Hence, 37 patients had cleft palate repair in our institute, needing fistula repair were included in this study. We also excluded syndromic cleft lip and palate patients having associated with cardiac anomalies, ectodermal dysplasia and Pierre Robin sequence with compromised airway. Eight patients with total breakdown of palate with severe shortage of tissue, who needed the simultaneous tongue flap and pharyngeal flaps,<sup>[5]</sup> were excluded from this study.

As discussed above, the decision for surgical repair of palatal fistula was done after proper evaluation [Table 1]. The previous surgical techniques, scarring and shortage of tissue, inflammation of tissue and oral hygiene, availability of local tissue and concomitant planned procedures were considered to decide the timing and the surgical procedure for the fistula repair. For fistula in hard palate or junctional area, if adequate local tissue was available, it was closed by the mucoperiosteal flaps with releasing incisions like in Von Langenbeck palatoplasty.<sup>[6]</sup> In large fistulae and/or fistula extending in postalveolar and alveolar region were closed by two-flap technique and preferably with alveolar extended palatoplasty.<sup>[7,8]</sup> Alveolar extension palatoplasty (AEP) flaps were extremely useful [Figure 1a] for fistula in postalveolar region. The AEP flaps could be raised cautiously even in the presence of the previous scars between mucoperiosteum flaps and its extension into alveolus [Figure 1b]. However, an interval of 6 months or more between the palate repair and the fistula repair by AEP flaps is necessary.

For the large fistulae with a shortage of tissue and/or severe scarring preventing mobilization of the palatine tissue, an additional tissue was imported as local flaps according to the site of fistula. For postalveolar or anterior hard palate fistulae, where additional tissue was needed, an anteriorly based tongue flap were done<sup>[9]</sup> [Figure 2]. The tongue flaps provided oral lining, while the nasal lining was repaired with turn-over flaps from the fistula edges (hinge flaps) and this step was of paramount importance to prevent recurrent fistulae. The tongue flaps were routinely divided between 10 and 12 days, postoperatively.

Patients needing VPI correction and/or with a scarred/broken soft palate with fistula had nasoendoscopy for the structural evaluation. In severely scarred and broken soft palate with large nasopharyngeal defect on endoscopy, a superiorly based pharyngeal flap was used to add tissue for the nasal lining for the soft palate which also helps to improve velopharyngeal competence.

In a situation with failure of multiple attempts of fistula repair, refusal for surgery by patients and associated demands for a tooth prosthesis, prosthetic cover for a fistula was used.

We have analyzed the type of cleft, location of fistulae and type of surgeries performed in all the patients.

## RESULT

We studied distribution of fistula in various types of cleft lip and/or palate as shown in Table 2. In our institute, we had comparatively higher fistula occurrence in submucous cleft (6% of total 37 patients). In retrospect, it was noticed that sutures were put in thinner hypoplastic mucoperiosteum, which should have been excised.

The distribution of site of fistula in all 194 palatal fistulae showed most common site is hard palate and in postalveolar region contributing to 67% of all fistulae. This was followed by exclusive postalveolar region (9%) and junctional area [Table 3].

As the majority of the fistula were repaired by different procedure depending on the size of fistula, the availability of local tissue and necessity of adjuvant procedures. The procedures like local flap, Von Lagenback repair, two flap, AEP, palate repair and tongue flap were done to close the fistula. In 65 patients fistula repair was combined with other procedure like VPI correction, ABG and lip revision [Table 3].

Out of total 194 patients had fistula repair, 48% had followed up and 10 patients had residual fistula. All these patients had very poor local condition and oral hygiene. Two of

**Table 2 : Distribution of fistula in various types of cleft**

<i>Type of cleft</i>	<i>Distribution in 194 patient (%)</i>
Unilateral complete cleft lip and palate	101 (52)
Bilateral complete cleft lip and palate	58 (30)
Complete cleft of secondary Palate	22 (11)
Incomplete cleft of secondary palate	11 (6)
Submucous cleft	2 (1)

these were operated by AEP flap closure for postalveolar fistula and eight had tongue flap. Of two with AEP flap, one had successful closure with revision surgery while one had prosthetic rehabilitation. Eight out of 54 patients with tongue flap had postoperative problems. Five patients had flap detachment in postoperatively period. Four out of these five patients were resutured in the first 10 days, and two had complete closure while two had persistent fistula. One patient has revision tongue flap after duration of 8 months successfully. Remaining three patients had residual fistula at the posterior border of tongue flap observed during follow-up.

## DISCUSSION

Although palatal fistula is a common morbidity after cleft

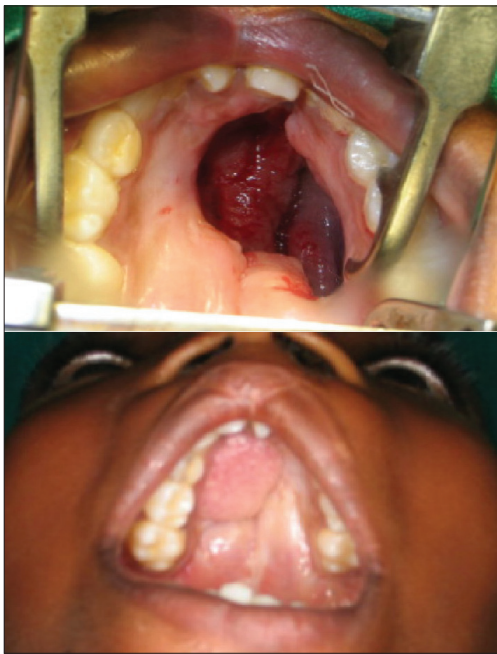

Figure 2: Tongue flap for fistulae repair

palate repair, minimal literature is available regarding the guidelines of management. Palatal fistula is a complication of cleft palate repair observed in different studies ranging from 0 to 34%.<sup>[2]</sup> We have analysed the descriptive data of type of cleft, site of fistula and management of fistula in our institute. From this data, we learned that smaller fistula are tend to be managed in the same hospital, while the larger fistula are more likely to go to specialized center or tertiary center due to difficulty in management and needing multidisciplinary care. The larger fistulae in difficult site like perialveolar region tend to be neglected and need interdisciplinary care in tertiary centers.

Management of cleft palate fistula is multidisciplinary approach and proper evaluation of speech and dental arch in addition to the local tissues are very essential. The functional aspect of the fistula should be given appropriate attention before a decision is reached on its structural surgical repair. After proper evaluation and decision regarding surgical repair, one needs to pay attention to the local tissue condition. The previous surgical techniques, scarring and shortage of tissue, inflammation of tissue and oral hygiene, availability of local tissue and concomitant planned procedures will decide the type of procedure for the fistula repair [Figure 3]. This approach will help to decide the proper timing and appropriate technique for surgical repair. Tongue flap has been a work horse for difficult palatal fistula with shortage of tissue. Similarly, buccal flaps also known as facial mayo-mucosal flap, is the most appropriate for junction fistulae if there is shortage of tissue. We have used the buccal flap for VPI correction but not for fistula repair. However, if utilized in junctional fistula, this will also help to lengthen the palate for VPI correction at the same time.<sup>[10,11]</sup> Other flaps which has been described and utilized

Table 3: Site of fistulae, procedures for fistula repair and adjuvant procedures

Site of fistula	Distribution in 194 patients (%)	Procedures for fistula closure (no. of patients)	Additional procedure (no. of patients)
Alveolar	18 (9)	AEP flap (18)	Lip nose revision (8) VPI corrective surgeries (5)
Hard palate	71 (36)	Local flap, langenbeck (62) Tongue flap (9)	ABG (1) Lip nose revision (5) VPI corrective surgeries (17)
Hard + post alveolar	61 (31.5)	Local flap/ langenbeck, AEP (30) Tongue flap (22)	ABG (2) VPI corrective surgeries (7) Lip nose revision (2)
Junctional	17 (9)	Local flap, langenbeck (17)	VPI corrective surgeries (5)
Soft palate	13 (7)	Soft palate re-repair (13)	VPI corrective surgeries (7) ABG (1)
Hard palate+soft palate	14 (7.5)	Palate re-repair (9) Tongue flap + Soft palate repair (5)	VPI corrective surgeries (5)

AEP - Alveolar extension palatoplasty, VPI - Velo-pharyngeal incompetence, ABG - Alveolar bone grafting

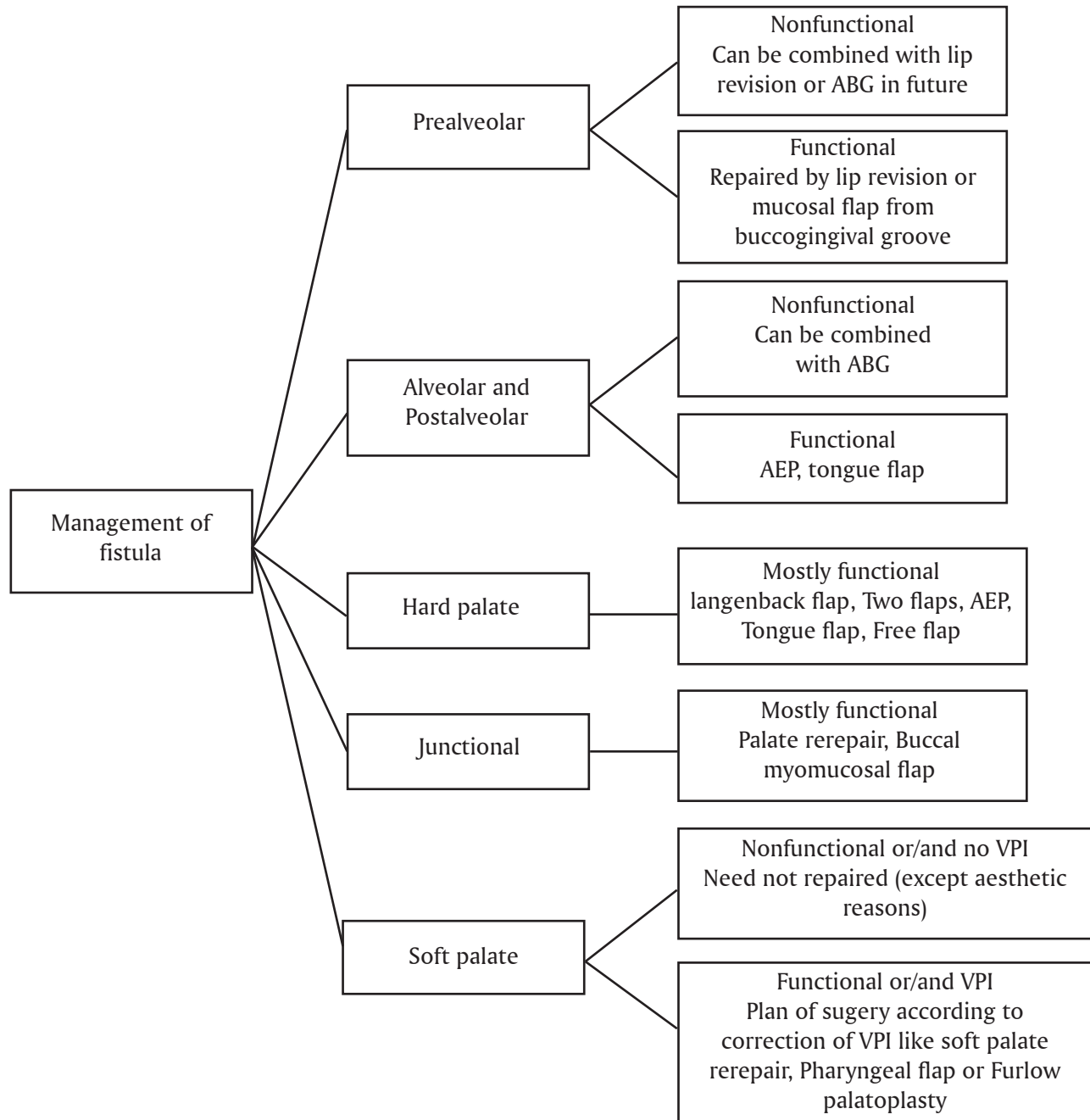


Figure 3: Algorithm for management of palatal fistula

very rarely in specific indication are, temporalis muscle flap and free microvascular free flaps.<sup>[12,13]</sup> However, the later options are more commonly utilized in closing non-cleft palatal reconstruction.

In certain situation like failure of multiple attempts of fistula repair, refusal for surgery by patients and associated demands for tooth prosthesis, the prosthetic cover for fistula can be applied. However, prosthesis can never provide nature barrier like tissue repair and has implication

on oral hygiene and dental health.

## REFERENCES

1. Veau V. Division Palatine. Paris, Masson et Cie, Paris: 1931.
2. Cohen SR, Kalinowski J, LaRossa D, Randall P. Cleft palate fistulas: A multivariate statistical analysis of prevalence, etiology, and surgical management. *Plast Reconstr Surg* 1991;87:1041-7.
3. Smith DM, Vecchione L, Jang S, Ford M, Deleyiannis FW, Haralam MA, *et al.* The Pittsburgh fistula classification system: A standardized scheme for the e description of palatal fistulas. *Cleft Palate Craniofac J* 2007;44:590-4.

4. Nanda V, Sharma R, Mehrotra S, Makkar SS, Munjal S. The "chewing gum test" for cleft palate speech. *Plast Reconstr Surg* 2005;116:18-22.
5. Murthy J. Salvaging procedure for mutilated cleft palate by simultaneous tongue and pharyngeal flap surgery. *Plast Reconstr Surg* 2008;122:29e-30e.
6. Muzaffar AR, Byrd HS, Rohrich RJ, Johns DF, LeBlanc D, Beran SJ, *et al.* Papaioannoua: incidence of cleft palate fistula: An institutional experience with two-stage palatal repair. *Plast Reconstr Surg* 2001;10:1515-8.
7. Denny AD, Amm CA. Surgical technique for the correction of postpalatoplasty fistulae of the hard palate. *Plast Reconstr Surg* 2005;115:383-7.
8. Carsten MH. Sequential cleft management with the sliding sulcus technique and alveolar extension palatoplasty. *J Craniofac Surg* 1999;10:503-18.
9. Jackson IT. Use of tongue flap to resurface lip defect and close palatal fistulae in children. *Plast Reconstr Surg* 1972;49:537-41.
10. Abdel-Aziz M. The use of buccal flap in the closure of posterior post-palatoplasty fistula. *Int J Pediatr Otorhinolaryngol* 2008;72:1657-61.
11. Ashtiani AK, Emami SA, Rasti M. Closure of complicated palatal fistula with facial artery musculomucosal flap. *Plast Reconstr Surg* 2005;116:381-6; discussion 387-8.
12. Krimmel M, Hoffmann J, Reinert S. Cleft palate fistula closure with a mucosal prelaminated lateral upper arm flap. *Plast Reconstr Surg* 2005;116:1870-2.
13. Schwabegger AH, Hubli E, Rieger M, Gassner R, Schmidt A, Ninkovic M. Role of free-tissue transfer in the treatment of recalcitrant palatal fistulae among patients with cleft palates. *Plast Reconstr Surg* 2004;113:1131-9.

**Source of Support:** Nil, **Conflict of Interest:** None declared.