

# Role of platysma muscle flap in depressed scars of neck

Rakesh K. Sandhir, Bharat R. Jindal, Shivanjali Sandhir<sup>1</sup>

Plastic Surgeon, St. Stephen's Hospital, Delhi, <sup>1</sup>HIMS, Dehradun, India.

**Address for correspondence:** Dr. Rakesh Kumar Sandhir, A-402, Sector 31, Noida – 201 303, India. E-mail: minrks@yahoo.in

## ABSTRACT

**Background:** Depressed scars in the neck pose a cosmetic problem. There is a need to fill the lost tissue volume defect between the surface and deeper tissues. It is preferable that the filling is done by autologous tissue which is available in substantial amount in the adjoining area. There should be no donor site morbidity. Platysma muscle flap meets these criteria. **Materials and Methods:** Platysma muscle flap was advanced into the defect after excision of depressed scar. The procedure was done under local anesthetic in two patients. **Result:** The result was a 'good scar' with scar lying in the transversely oriented neck lines. **Conclusions:** Platysma muscle flap has a definitive role in revision surgery of depressed scars in neck as it provides an ideal tissue for lost tissue volume.

## KEY WORDS

Depressed scar; platysma muscle flap; revision

## INTRODUCTION

The scar or cicatrix may be defined as the tissue that is formed in the healing of a wound.<sup>[1]</sup> The wound may occur due to injury, burns, surgery or infection. The shape and size of the scar depends on the wound size, its location and various factors affecting the healing process. The symptoms attributable to scar include itching, pain, functional disabilities due to contractures and poor aesthetics. There are scars, however, whose sole malady is unacceptable aesthetic appearance. These patients suffer from emotional stress, low self-esteem and psychosocial maladjustments and require our attention. Depressed scars in face, neck and exposed areas may fall in this category.

Platysma muscle flap, in the neck, has been interposed between the scar and underlying structures to correct the depression of scar from surface.

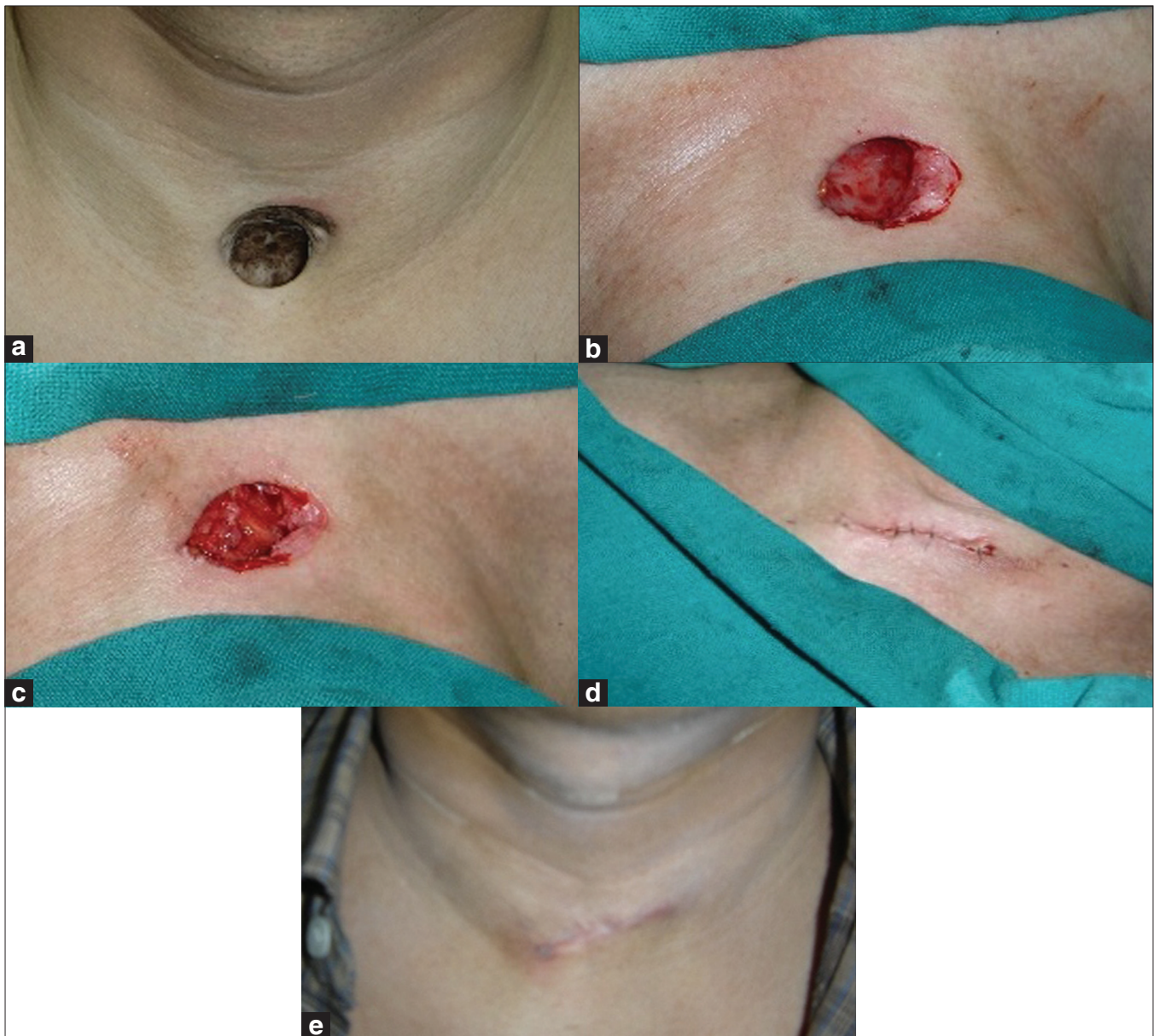## MATERIALS AND METHODS

The procedure was performed in two patients with depressed scars in the neck. The scar and the adjoining area was infiltrated with local anesthetic lignocaine and 1:200,000 adrenaline. The scar was excised. The skin margins were undermined along with subcutaneous tissues and raised off the platysma muscle. The medial margins of the platysma muscle were mobilised. The muscles could be easily freed from the underlying fascia. The muscles were superiorly and inferiorly transected from inside the wound margins for transverse mobilisation as advancement flap. The incisions in the muscles were made to the extent that transverse mobilisation could occur for tension-free closure of muscle flaps. The muscle flaps were sutured. The undermined skin margins were mobilised for tension-free horizontal closure.

### Case 1

A 40-year-old man presented with a depressed scar in

Access this article online	
<b>Quick Response Code:</b> 	<b>Website:</b> www.ijps.org
	<b>DOI:</b> 10.4103/0970-0358.81435



**Figure 1:** (a) Preoperative showing depressed scar at suprasternal notch area; (b) defect after excision of scar; (c) platysma muscle flap advanced into the defect; (d) closure of wound transversely; (e) final result

the suprasternal notch. He had an abscess in this area about 5 months back. A scar was formed after abscess drainage and healing by secondary intention. The scar was excised. Skin margins were freed. Platysma muscle was freed transversely and advanced into the defect. The wound closure was done horizontally [Figure 1 a–e].

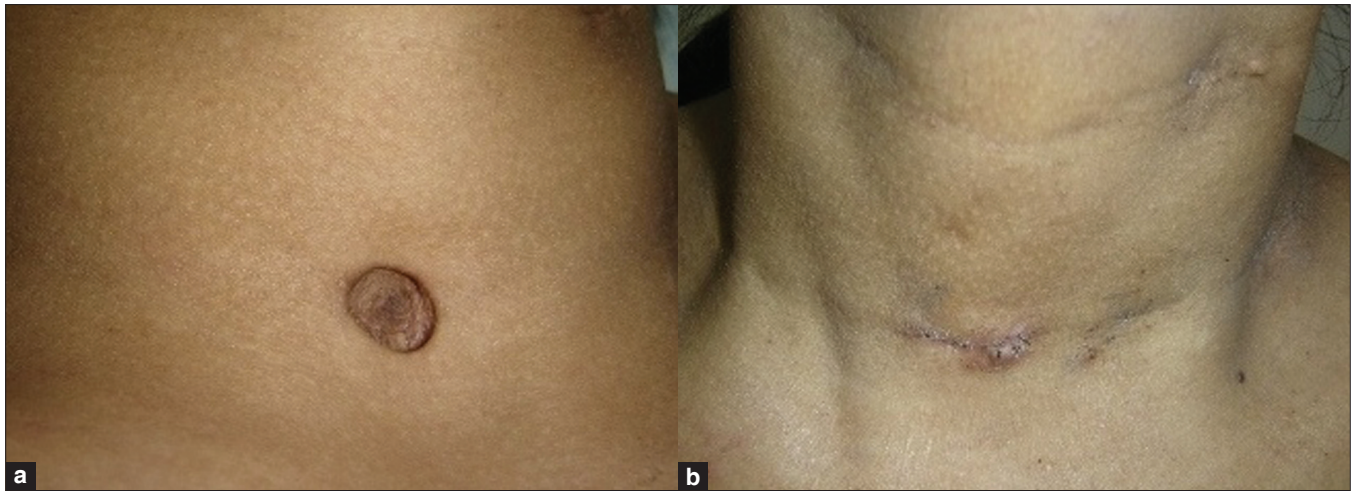
## Case 2

A 20-year-old female had depressed scar in the midneck area. She was treated for tubercular lymphadenitis and abscess in childhood at the age of 6–7 years and the resultant depressed scar was causing concern. The scar was excised and the defect left after excision was volume

filled by advancing platysma muscle flap. The wound was closed transversely [Figure 2a, b].

## DISCUSSION

Skin is a compound organ. The healing of an injured organ occurs by means of a relatively simple mechanism by formation of predominantly fibrous tissue.<sup>[2]</sup> Scar tissue is a component of collagen. There may be disturbed or abnormal collagen production during wound healing which is a dynamic and complex process. The abnormality in healing leads to various types of scars. The scars may be atrophic, hypertrophic, keloids or stretched. There is an excessive



**Figure 2:** (a) Preoperative (b) postoperative

production of collagen in keloid and hypertrophic scars. The stretched scars occur, as in pregnancy, when the dermal elements are damaged without any breach in epidermis. The result is a depressed (atrophic) scar when dermal collagen and connective tissue production during the physiological wound healing process inadequately compensates for the tissue loss present after injury.

Tracheostomy scar is a common depressed scar in neck. The tracheostomy tug during swallowing, as it is commonly called, is because of loss of underlying tissue which occurs due to pressure necrosis of soft tissues by the indwelling tube. Small defects may be filled and improved by edge deepithelialisation technique, dermal fat graft or allogeneic dermal graft.<sup>[3]</sup>

Scars in the neck and face, due to various causes, may be improved by filler agents like collagen and hyaluronic acid after releasing deep dermal adhesions.<sup>[4]</sup> There is less tissue invasion in neck when fillers are used. Fat grafting after subcision has also been done.<sup>[5]</sup> These techniques may be successful in small depressed scars which are not wide. The problems like colour matching or scar direction are not the issues. Moreover, repair by fillers may be a temporary measure. The organic implants may be absorbed over a period of time. Autologous fat grafting may be advantageous for its long-lasting results. However, depending on the clinical judgment and situation, alloplastic permanent fillers may also be used.

Neck defects of large size require flaps for repair. Reconstruction of anterior neck defect by two platysma myocutaneous flaps has been found to be an option.<sup>[6]</sup> Bilateral platysma flaps by overlapping have satisfactorily been used to correct large, depressed, fixed post-

tracheostomy scar.<sup>[7]</sup> Turnover platysma flaps also correct such a deformity.<sup>[8]</sup>

Platysma is a muscle sheet which extends from the deep fascia beneath the breast upwards to the inferior border of mandible. It is obliquely placed and is thick anteriorly. Its flap may be used as superiorly, inferiorly or posteriorly based. The superiorly based flap, with vertical orientation, has vascular axis on submental vessels. The branches of transverse cervical artery supply the muscle inferiorly. The flap can be raised on a horizontal axis, with the vascular supply coming from the posterior neck branches of the transverse cervical and posterior auricular arteries.<sup>[9]</sup> The superior thyroid artery supplies the muscle in the anterior triangle of neck.

The use of platysma myocutaneous flap in reconstructing oral defects after carcinoma surgery has low morbidity in the form of a scar at donor site.<sup>[10]</sup> The platysma muscle flap harvesting does not leave any functional or cosmetic deformity. It is an important consideration in scar revision surgery. The plan of scar defect reconstruction by the muscle flap should be reviewed if its harvesting is likely to lead to donor site morbidity. It may occur in the form of residual scarring when the scar defect for reconstruction is not contiguous with the donor harvest site.

The role of platysma in scar revision has not been fully appreciated. The defects which are not wide are commonly closed by undermining and mobilisation of the surrounding tissues. It is actually a layered closure. The platysma inadvertently is part of this closure which gives satisfactory result.



Surgical revision is the mainstay treatment of depressed scars. The scar has three components: line, contour and colour. The aim of any scar revision surgery is to replace the unpleasant scar with a “good scar”. It is the one which is no more than a fine line, level and even with the surrounding surface; it is of the same colour as the surrounding skin and causes no contracture, pull or distortion of the surrounding structures.<sup>[11]</sup> Any scar revision surgery requires a critical analysis and multidimensional imagination for reconstruction. It may be pointed out here that even in suprasternal notch scar, volume replacement was required (case 1). Three Dimensional restoration of natural depressions is required for proper appearance. The amount of tissue needed for replacement purpose in such cases is guided by clinical judgment. Scars of this type are rare in the mid-anterior neck, especially in suprasternal notch area and very easily visible.

Different scars require different treatment depending upon their individual characteristics. There is a paucity of well-designed, randomised, controlled studies on scar treatment, on which one could rely.<sup>[12]</sup> The watchword in any scar revision surgery is an imaginative eye that views the result even before revision. It may indicate that fine depressed line scars need not require treatment by excision.

The principles of treatment of depressed scar revision are release of inward oriented skin edge, volume replacement and closure of defect in transversely oriented relaxed neck lines. In our cases, after excision of hyperpigmented scar, edges were freed and volume replacement was done by advancing platysma muscle flap. The closure could be done in favourable direction of neck lines. We were able to achieve a good scar.

## CONCLUSIONS

Platysma muscle flap is the tissue of choice for providing

replacement of lost volume in reconstructing depressed scars in the neck.

## REFERENCES

1. Dorland. Dorland's illustrated Medical Dictionary, 25<sup>th</sup> Ed. Philadelphia: WB Saunders Company; 1974.
2. Peacock EE, Winkle WV. Repair of skin wounds (Chapter 6). Wound Repair. 2<sup>nd</sup> ed. Philadelphia: WB Saunders; 1976. p. 204-70.
3. Grant N, Davison SP. Management of the post tracheostomy scar. *Laryngoscope* 2007;117:2107-9.
4. Kontis TC. Scar Revision and skin resurfacing. In: Snow JB, Wackym PA, editors. Ballenger's Otorhinolaryngology Head and Neck Surgery. Cent. ed. People's Medical Publishing House; 17<sup>th</sup> ed. Connecticut 2009. p. 707-16.
5. Shiffman MA, editor. Autologous fat transfer, Art, Science and Clinicalpractice. (Chapter11) Subcision with fat transfer. Heidelberg: Springer; 2009. p. 67.
6. Zimman OA. Reconstruction of the neck with two rotation - advancement Platysma myocutaneous flaps. *Plastic Reconstr Surg* 1999;103:1712-4.
7. Ozgenel GY. Overlapping double platysma flaps for the correction of post-tracheostomy scars. *Eur J Plast Surg* 2004;27:149-51.
8. Yiacoymettis AM, Papadimitriou AM. Platysma muscle turnover flap for correction of tracheostomy scarring. *Br J Plast Surg* 2001;54:205-7.
9. Ariyan S. The transverse platysma myocutaneous flap for head and neck reconstruction. *Plast Reconstr Surg* 1997;99:340.
10. Koch WM. The Platysma Myocutaneous flap: Under used alternative for Head and Neck Reconstruction. *Laryngoscope* 2002;112:1204-8.
11. Crikelair GF, Ju DM, Cosman B. Scar and keloids (Chapter 16). In: Converse JM, editor. *Reconstructive Plastic Surgery*. 2<sup>nd</sup> ed. Philadelphia: WB Saunders; 1977. p. 413-41.
12. Reish RG, Eriksson E. Scars: A review of emerging and currently available therapies. *Plast Reconstr Surg* 2008;122:1068-78.

**Source of Support:** Nil, **Conflict of Interest:** None declared.