

## Case Report

# Toxoplasmosis of the spinal cord in an immunocompromised patient: case report and review of the literature.

## Toxoplasmosis medular en un paciente inmunosuprimido: Informe de un caso y revisión de la literatura

Carolina Rodríguez<sup>\*1</sup>, Ernesto Martínez<sup>2</sup>, Guillermo Bolívar<sup>3</sup>, Sandra Sánchez<sup>4</sup> Edwin Carrascal<sup>4</sup>

<sup>1</sup> Universidad del Valle. Hospital Universitario del Valle. Department of Internal Medicine. Cali, Colombia.

<sup>2</sup> Universidad del Valle and Universidad Libre. Hospital Universitario del Valle, Department of Internal Medicine. Cali, Colombia.

<sup>3</sup> Universidad Libre, Department of Internal Medicine. Cali, Colombia.

<sup>4</sup> Universidad del Valle. Hospital Universitario del Valle, Department of Pathology. Cali, Colombia

Rodríguez C, Martínez E, Bolívar G, Sánchez S, Carrascal E. Toxoplasmosis of the spinal cord in an immunocompromised patient: case report and review of the literature. *Colomb Med.* 2013;44(4)

### Article history:

Received: Feb 22 2012

Received in revised form

Mar 15 2012

Accepted: Ago 16 2013

### Keywords:

Spinal cord toxoplasmosis, central nervous system, myelopathy in immunocompromised patient

### Palabras Clave:

La toxoplasmosis de la médula espinal, sistema nervioso central, mielopatía en paciente inmunocomprometido

### Abstract

We, herein, describe an HIV-positive patient with toxoplasmosis of the spinal cord. We also carried out a comprehensive literature review of this topic, with emphasis on the diagnostic tools and therapeutic approach.

### Resumen

Se presenta el caso de un paciente seropositivo para VIH con diagnóstico de toxoplasmosis medular en conjunto con la revisión de la literatura de los pocos casos descritos hasta la fecha, con énfasis en las claves diagnósticas y la aproximación terapéutica.

### \*Corresponding Author.

E-mail Address :

arpicaro@hotmail.com (Rodríguez C), emarbui@gmail.com (Martínez E)

lunasa12@hotmail.com (Sánchez Sandra)

## Introduction

Toxoplasmosis is the first cause of intracranial lesions associated to neurological deficit in HIV/AIDS<sup>1</sup>. According to geographic location, the frequency varies between 3 and 50% of these patients. The risk factor most strongly related to this infection is CD4-positive lymphocyte count below 200/mm<sup>3</sup>, and especially below 50/mm<sup>3</sup><sup>3-6</sup>. Extracerebral locations are described with less frequency, in less than 11% of the cases<sup>2,6</sup>, with myelitis due to toxoplasma being an uncommon condition, with only 19 cases in medical literature, of which only seven have been confirmed in living patients<sup>1,3</sup>. Herein, we present the case of an HIV-infected patient diagnosed with myelitis due to toxoplasma confirmed by biopsy, and review the published literature on this condition.

Literature search was carried out in PubMed, Medline, LILACS, and SciELO databases by using the terms: toxoplasma, toxoplasmosis, medullary, medular, spinal, myelitis, myelopathy. Descriptions in Spanish and English were considered of infection due to toxoplasmosis in spinal cord among adult patients. Two cases described in French were included.

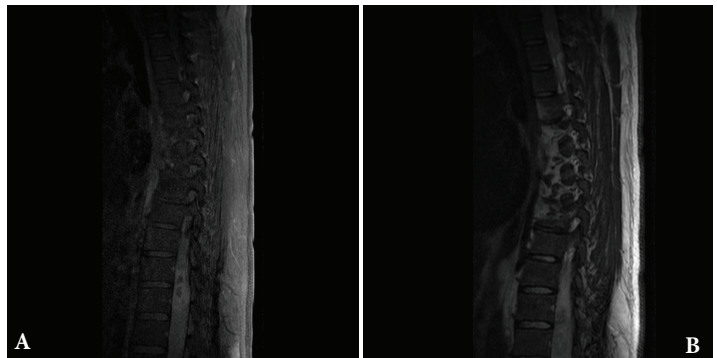
**Case description:** The case was presented in the Internal Medicine Emergency Service at Hospital Universitario del Valle in Cali, Colombia.

Clinical data was collected from the medical chart and signed informed consent was obtained from the patient for its publication. This was a 40 year-old, Latin American, heterosexual, male patient, with history of HIV infection diagnosed seven years ago. The patient was under antiretroviral treatment. His past medical history revealed an episode of cerebral toxoplasmosis five years ago, diagnosed through positive IgG for toxoplasma and suggestive clinical presentation and scan imaging. This former episode was treated with standard dose of pyrimethamine and sulfadiazine with good clinical and imagen response, followed by intermittent prophylaxis with trimethoprim sulfamethoxazole. The patient presented to emergency room at our hospital with a two-year history of evolution of lumbar pain of moderate to severe intensity, associated to diminished strength in the lower limbs, more pronounced on the lower right limb, with compromise of the urinary sphincter during last months. The CD4 count was 60 cells/mm<sup>3</sup> and the viral load was 55,110 copies/mL.

Physical exam revealed a patient in good nutritional condition, bedridden, with neurological deficit characterized by plegia in lower right limb, with greater compromise in distal roots of L3, L4, and L5 and paresis in the lower left limb. Further exam showed lack of bilateral Achilles and patellar reflex. Sensitivity was unaltered. The CSF extension exam resulted not suitable for cell count due to sample coagulation, with glucose of 6 mg/dl, proteins of 4100 mg/dl, and LDH of 274 u/l. Magnetic resonance imaging (MRI) of thoracolumbar spine with gadolinium (Figures 1A, 1B) showed an expansive lesion, with affectation of the distal medullary cone, isointense to spinal cord on T1, heterogeneous intensity, and areas of hyperintensity on T2.

The lesion extended from T10 to T12 and presented peripheral enhancement with contrast in relation to a probably infectious-inflammatory process, suggesting toxoplasmosis as first possibility. Surgical exploration was conducted of the medullary cone, find-

**Figure 1A:** Thoracolumbar MRI. Phase contrasted with gadolinium, evidencing peripheral enhancement of the medullary lesion in segments T10 to T12, suggesting infection due to toxoplasma. **1B:** Thoracolumbar MRI. T2 sequence, evidencing heterogeneous density lesion in medullary segments T10 to T12.

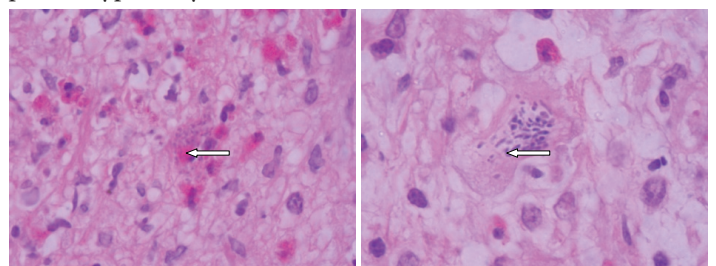


ing a thickened and hardened epiconus, with arachnoid and healthy skin, a tough avascular intra-axial fibrous lesion, from which samples were taken. The pathological study identified acute vasculitis with granulomatous component, extensive necrosis, and tachyzoites compatible with toxoplasmosis (Figure 2). Special stains and cultures for acid fast bacilli and fungi were negative. The immunohistochemical study for toxoplasma was positive (specific monoclonal antibody against *Toxoplasma gondii* – Dako) (Figure 3). The PCR studies in CSF for herpes simplex virus types 1 and 2, Epstein-Barr virus, *Mycobacterium tuberculosis*, and cytomegalovirus were negative. Electromyography of the four limbs provided abnormal results, with electrophysiological evidence of motor polyneuropathy and distal axonal sensitivity in lower limbs. The B12 vitamin and plasma folate levels were normal.

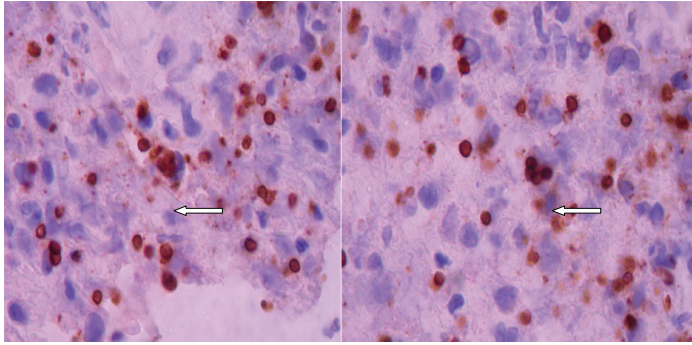
The patient received second-line treatment<sup>7</sup> with trimethoprim sulfamethoxazole at a dose of 10 mg/kg/d IV and clindamycin 1200 mg IV every 6 h, according to the availability in the institution, with adequate tolerance. Clinical improvement was observed with partial recovery of his neurological deficit accomplishing deambulation with a walker aid at eight weeks of treatment, leaving him with a sequel of a right foot drop.

**Discussion:** vacuolar myelopathy is a common condition with medullary compromise in HIV-positive patients, found in over 30% of autopsies prior the start of the era of antiretroviral therapy<sup>1</sup>. Other broadly described causes and possible differential diagnoses to bear in mind include HTLV I or II, herpes simplex 1 or 2, vari-

**Figure 2.** Microphotograph of medullary cone with extensive perivascular lymphocytic inflammatory infiltrate over a fibrillary stroma, with caseous necrosis, abundant eosinophils, and toxoplasma-type tachyzoite. H and E 100X



**Figure 3.** Microphotograph revealing numerous toxoplasma tachyzoites through immunoperoxidase reaction by using a specific monoclonal antibody against *Toxoplasma gondii* (Dako). 100X.



cella zoster, cytomegalovirus, syphilis, and tuberculosis, among the infections; and lymphoma or nutritional deficiencies, among the non-infectious causes<sup>6</sup>. To date, only 18 cases have been described of myelitis due to toxoplasma diagnosed histologically, via biopsy or autopsy, or through successful therapeutic trials within the context of a compatible clinical condition (Table 1). From the epidemiological point of view, these were patients almost all of male gender (90%), between the third and fourth decade of life. All the cases described have been associated to immunodeficiency, which only in three of these was not related to HIV. The symptoms described in most of the cases are lumbar pain, loss of motor function with compromise especially in lower limbs (70%), bladder dysfunction (55%), and sensitive alteration with specific medul-

lar level (75%). One patient presented Brown-Sequard syndrome. In all cases in which a cerebrospinal fluid study was conducted, alterations were found, with increased protein levels being the most common finding, with values up to 2.2 gr/dl. The IgG antibody toxoplasma was positive in all but one of the patients evaluated. Magnetic resonance imaging (MRI) with gadolinium was the preferred imaging diagnostic method, with enhanced solitary intra-medullary lesions as the most frequent findings. The most frequently compromised segment was the thoracic (55%) and simultaneous cerebral and medullary involvement was established in half the cases described<sup>1,3</sup>. All the cases were immunosuppressed patients, with the vast majority being HIV-positive with one case among these suspected medullary toxoplasmosis as a result of Immune Response Inflammatory Syndrome (IRIS)<sup>2</sup>. With regards of treatment, similar courses of antibiotics to those considered standard for cerebral toxoplasmosis were given. According to current guidelines, variable results are obtained with pyrimethamine sulfadiazine as the first option, with early diagnosis being the best prognosis factor for complete recovery of these patients<sup>4</sup>. No special mention of using steroids associated to the antibiotic regime was found, although their use in two cases have been described with success. In our case, steroid treatment was administered during the first eight weeks of treatment, with good relative response in spite of the late diagnosis. More studies are needed to recommend this strategy in the future and determine the adequate manner for follow up and assessment of these patients.

**Conclusion:** In spite of the few cases described in the literature, myelitis due to *Toxoplasma gondii* could be a more common con-

**Table 1.**

Author	Neurological finding	Age gender	Diagnosis	Imaging study	CSF (*)	HIV	CD4/HAART	(**)	Outcome
1.Rohit Vyas and John R. Ebrigh. 1996. <i>Clin Inf Dis</i> .	Paraparesis. Sensitive impairment from T4. Bladder and	32 Male	Empiric toxoplasma therapy response, IgG(+)	MRI ring enhancing lesion T4 level	Prot 193 PMN 4	+	9/no	Yes	Improvement
2. Constance Kayser et al. 1990. <i>J Neuro surgery</i> .	Paraparesis. Sensitive impairment. Bladder and rectal sphincter paralysis.	32 Male	Biopsy, IgG(+)	MRI conus medullaris ring	Prot 220 PMN 30 Gluc 43	+	ND/ND	No	Improvement
3.Doris H Kung et al. 2011. <i>Neurologist</i> .	Paraparesis. Sensitive impairment from L4. Bladder and rectal sphincter paralysis.	34 Male	Biopsy, IgG(-)	MRI ring enhancing lesion T11 T12 level	Prot 49 PMN 2	+	67/no	No	ND
4. Carlos García Gubern et al. 2010 <i>Int J EmergMed</i> .	Flaccid paralysis. Sensitive impairment from L1. Bladder and rectal sphincter paralysis.	40 Male	Empiric toxoplasma therapy response, IgG(+)	MRI transverse myelitis T11 T12	Prot 184 PMN 11	+	56/no	Yes	Improvement
5.Mehre et al. 1988. <i>Neurology</i> .	Hemiparesis. Proprioception and vibratory sense impairment.	63 Male	Autopsy, IgG(+)	MRI ring enhancing lesion C2-C4	Prot 127 L 43 Gluc 53	+	ND/ND	Yes	Deceased
6. Todd M. Harris. 1990. <i>J of Comput Assist Tomogr</i> .	Paraparesis. Sensitive impairment in lower limbs	32 Male	Biopsy IgG(+)	MRI conus medullaris ring	Prot 220 PMN 30 Gluc 43	+	ND/ND	ND	ND
7. Elves Maciel et al. 2000. <i>Arq Neuropsiquiatr</i> .	Paraplegia. Bladder and rectal sphincterparalysis.	51 Male	Autopsy	NO	Prot 22 PMN 1 Gluc 53	-	Leukemia	Yes	Deceased
8. Arshad Saarah et al. 2009. <i>The AIDS reader</i> .	Paraparesis.	46 Female	Empiric toxoplasma therapy response, IgG(+)	MRI multiple ring enhancing lesion,	Prot 259 PMN 21 L 20	+	60/no	Yes	Improvement
9. TungPuiPoon et al.1992. <i>J of Comput Assist Tomogr</i> .	Paraparesis. Sensitive impairment from L2. Bladder and rectal sphincter paralysis.	35 Male	Biopsy,IgG(+)	MRI ring enhancing lesion T11- L1	Prot 74 PMN 4 Gluc 46	+	79/ND	No	No Improvement
10. Daniel K. Resnick et al. 1995. <i>J neurosur</i> .	Paraplegia. Sensitive impairment from L4 .Bladder and rectal sphincter paralysis.	45 Male	Biopsy, IgG(+)	MRI ring enhancing lesion, edema T4	Prot 359 PMN 1 Gluc 23	+	29/ND	No	No Improvement
11. J Marc Overhage. 1990. <i>Am J Med</i>	Paraparesis. Sensitive impairment from L4. Bladder and rectal sphincter paralysis.	34 Male	Biopsy	MRI ring enhancinglesion L1	Prot 2200 PMN 30 Gluc 43	+	ND/ND	No	Improvement
12. C.S.M Straathof. 2001. <i>J Neurol</i> .	Brown Sequard syndrome.	60 Male	IgG(+) PCR (+)	MRI ring enhancing lesion T7	Prot 760 PMN 15	-	Leukemia	No	Improvement
13. Lortholary O et al. 1994. <i>Clin Infect Dis</i> .	Paraparesis. Sensitive impairment from T5 - T10	34 Female	Empiric toxoplasma therapy response, IgG(+)	MRI ring enhancing lesion T4	NR	+	16/Yes	Yes	Improvement
14. Herskovitz S et al. 1989. <i>Neurology</i> .	Paraparesis. Sensitive impairment fromT2. Bladder and rectal sphincter paralysis.	NR	Biopsy, IgG (+)	Ctscan spinele dema T4	Prot 1172 Gluc 46	+	ND/ND	Yes	ND
15. Fairley CK et al. 1992. <i>Int J STD AIDS</i> .	Monoparesis, left upper limb.	NR	IgG(+)	MRI ring enhancing lesion C4-C5	Prot 156 PMN 48	+	ND/ND	Yes	Improvement
16. Chemouilli P et al. 1994 <i>Presse Med</i> .	Dysesthesia (T10-L2)	45 Male	Empiric toxoplasma therapy response, IgG(+)	MRI ring enhancing lesión T10-T11	NR	+	ND/ND	Yes	Improvement
17. Artigas J et al. 1994 <i>Clin Neuropathol</i> .	Cognitive impairment, peripheral polyradiculopathy. Bladder and rectal	ND	Autopsy	ND	Prot 448 PMN 570	+	ND/ND	Yes	Deceased
18. Nag S, Jackson AC. 1989. <i>Can J Neurol Sci</i> .	Lefthemiparesis Sensitive impairment fromT5. Bladder and rectal sphincter paralysis.	58 Female	Autopsy, IgG(+)	CTscan (brain) multiple hipodense frontal lesions	Prot 760 PMN 80 Gluc 56	-	AIHA	Yes	Deceased

dition than thought. By being a treatable disease whose prognosis improves with early diagnosis, toxoplasmosis must be considered in the differential approach of all HIV-positive patients with suggestive clinical history, presence of medullar involvement during magnetic resonance study (especially if it is a solitary lesion), in combination with positive IgG antibody toxoplasma. Timely treatment can result in the patient's significant improvement.

#### **Declaration of interest:**

The authors declare that there is no conflict of interest that could be perceived as prejudicing the impartiality of the information reported.

#### **References**

1. Vyas R, Ebright JR. Toxoplasmosis of the spinal cord in a patient with AIDS: case report and review. *Clin Infect Dis*. 1996 Nov; 23(5):1061-5. Review.
2. Kung DH, Hubenthal EA, Kwan JY, Shelburne SA, Goodman JC, Kass JS. Toxoplasmosis myelopathy and myopathy in an AIDS patient: a case of immune reconstitution inflammatory syndrome? *Neurologist*. 2011 Jan; 17(1):49-51.
3. Garcia-Gubern C, Fuentes R. C, Colon-Rolon L, Masdival D. Spinal cord toxoplasmosis as an unusual presentation of AIDS: case report and review of the literature. *Inte J Emerg Med* (2010) 3:439-442.
4. Arshad S, Skiest D, Granowitz EV. Subacute onset of paralysis in a person with AIDS. *AIDS Read*. 2009 Jan; 19(1):32-5.
5. CK, Wodak J, Benson E. Spinal cord toxoplasmosis in a patient with human immunodeficiency virus infection. *Int J STD AIDS* 1992; 3:366-8.
6. Singer E, Valdes-Sueiras M, Commins D, Levine A. Neurologic Presentations of AIDS. *NeurolClin* 28 (2010) 253-275.
7. Guidelines for prevention and treatment of opportunistic infections in HIV-infected adults and adolescents: Recommendations from CDC, the National Institutes of Health, and the HIV Medicine Association of the Infectious Diseases Society of America. *MMWR MorbMortal Wkly Rep*.2009; 58:1-198.