

CASE REPORT

Enterocutaneous Fistula Coexisting with Enterovesical Fistula: A Rare Complication of Ovarian Cystectomy

DOI: 10.29063/ajrh2019/v23i1.15

Ileogben Sunday-Adeoye¹, Uche E Eni², Kenneth C Ekwedigwe¹, Maradona E Isikhuemen^{1*}, Babafemi C Daniyan¹, Emmanuel N Yakubu¹, Monday O Eliboh¹ and Israel E Uguru¹

National Obstetric Fistula Centre, Abakaliki¹; Department of Surgery, Federal Teaching Hospital, Abakaliki²

*For Correspondence: Email: maradona4real2002@yahoo.com

Abstract

Enterocutaneous fistula is an abnormal communication between the intestine and the skin, while enterovesical fistula is an abnormal communication between the intestine and the bladder. Both are not usual complications of ovarian cystectomy. We present a patient with enterovesical fistula coexisting with enterocutaneous fistula following ovarian cystectomy. She is a 24-year-old lady with background immunosuppression who presented to the National Obstetric Fistula Centre, Abakaliki South-East Nigeria with a history fecaluria, pneumaturia and passage of feculent fluid through the skin following ovarian cystectomy. Fistulogram was in keeping with rectovesical fistula. She was repaired in a single stage and made an uneventful recovery. Enterovesical fistula and enterocutaneous fistula are uncommon but possible complications of ovarian cystectomy. (*Afr J Reprod Health 2019; 23[1]: 150-153*).

Keywords: Enterocutaneous fistula, enterovesical fistula, ovarian cystectomy, fecaluria, pneumaturia

Résumé

La fistule entéro-cutanée est une communication anormale entre l'intestin et la peau, tandis que la fistule entérosiciale est une communication anormale entre l'intestin et la vessie. Les deux ne sont pas des complications habituelles de la cystectomie ovarienne. Nous présentons une patiente avec une fistule entéro-coexistante avec une fistule entéro-cutanée à la suite d'une cystectomie ovarienne. C'est une femme de 24 ans atteinte d'immunosuppression d'origine qui s'est présentée au Centre national de la fistule obstétricale, Abakaliki, dans le sud-est du Nigéria, avec une histoire de fécalurie, de pneumaturia et de passage de liquide fécal à travers la peau après une cystectomie ovarienne. Le fistulogramme correspondait à la fistule rectovesicale. Elle a été réparée en une seule étape et a guéri sans problème. Les fistules entéroptiques et les fistules à enterocutaneus sont des complications rares mais possibles de la cystectomie ovarienne. (*Afr J Reprod Health 2019; 23[1]: 150-153*).

Mots-clés: Fistule entéro-cutanée, fistule entérovasculaire, cystectomie ovarienne, fécalurie, pneumaturia

Introduction

Enterocutaneous fistula is an abnormal communication between the intestine and the skin¹. Enterocutaneous fistula may occur spontaneously or following surgery and the latter is more common². The postoperative causes of enterocutaneous fistula include inflammatory bowel disease operations and surgeries for malignancies³. The diagnosis is usually obvious as affected patients present with external drainage of enteric

contents³. The goals of treatment for patients with enterocutaneous fistula are to correct metabolic and nutritional problems, close the fistula, and re-establish continuity and anatomy of the gastrointestinal tract³. Enterovesical fistula is an abnormal communication between the bladder and the intestine⁴. Diverticulitis is the most common cause⁵. Affected patients commonly present with pneumaturia, haematuria and recurrent urinary tract infection⁴. Its management can be conservative, medical or surgical, depending on

the aetiology⁴. This report presents a case of enterovesical fistula coexisting with enterocutaneous fistula following ovarian cystectomy in a patient with background immunosuppression.

Case Report

A 24-year-old nullipara woman presented at the National Obstetric Fistula Centre, Abakaliki with a history of faecaluria, pneumaturia and haematuria of six years duration. Her problems started one week following ovarian cystectomy for a benign ovarian cyst. She also gave a history of discharge of feculent material through the abdomen. There was also a positive history of urinary frequency and urgency. She was a known retroviral disease patient on HAART.

On examination, a midline infraumbilical abdominal scar was noted. There was a fistula that opened into the scar at its lower end with associated drainage of scanty feculent material. Catheterization revealed faecal matter in the urine.

Laboratory investigations were normal. Abdominal ultrasound showed urinary bladder diverticulum. Barium enema demonstrated rectovesical fistula. The patient was then worked up for surgery.

At surgery, the abdomen was opened using a midline infraumbilical incision and the fistulous tract was noted. There were severe adhesions between the gut, bladder and the anterior abdominal wall which were carefully separated. The fistulous tract that was emptying into the abdominal wall was mobilised and dissected and same was done for the fistulous tract between the bladder and the gut (Figure 1). The bladder was opened and the defect on it was identified and repaired (Figure 2). Following excision of the fistulous opening from the gut, an end to end anastomosis was done. The abdominal incision was then sutured.

In the postoperative period she was managed with antibiotics and analgesics. She was catheterized for 14 days and was then discharged.

Discussion

Abdominal surgery is the commonest aetiological factor for enterocutaneous fistula². A case of enterocutaneous fistula following total abdominal hysterectomy and bilateral salpingo-oophorectomy for ovarian cyst has been reported in the literature⁶. Although the definite cause of enterocutaneous and enterovesical fistula could not be established in this patient, it is probable that both pathologies were iatrogenic.

The diagnosis of enterocutaneous fistula as seen in the index patient may be made clinically by visualizing the type of material draining from the fistula site³. Symptoms can occur five to six days after surgery with associated fever and persistent ileus³. Our patient started having symptoms one week after surgery.

In the management of enterocutaneous fistula, there is patient stabilization, treatment of sepsis when present, skin protection and adequate nutrition⁶. When using non-operative method, adequate nutrition is a recognized modality for reducing the mortality from this disease condition². Surgery is another modality for management of enterocutaneous fistula. It is usually done after the inflammation in the abdomen has subsided². The goal of surgery is to reset the fistula with end-to-end anastomosis of the bowel and secure abdominal wall closure thereby restoring the entire bowel to its pre-morbid state⁷.

Based on the daily output, enterocutaneous fistula may be divided into low output fistula (< 200ml), moderate output (200 – 500ml) and high output (>500ml). Low output fistulae have a better prognosis⁶.

The second pathology in the index patient which is enterovesical fistula is also an uncommon disease. It usually results following diverticular disease but can as well occur from trauma, malignancies and pelvic surgeries^{4,8}. It requires a high index of suspicion for early diagnosis⁴. Clinically, fecaluria, pneumaturia and recurrent urinary tract infection are useful in the diagnosis of this disease condition⁴. Treatment of

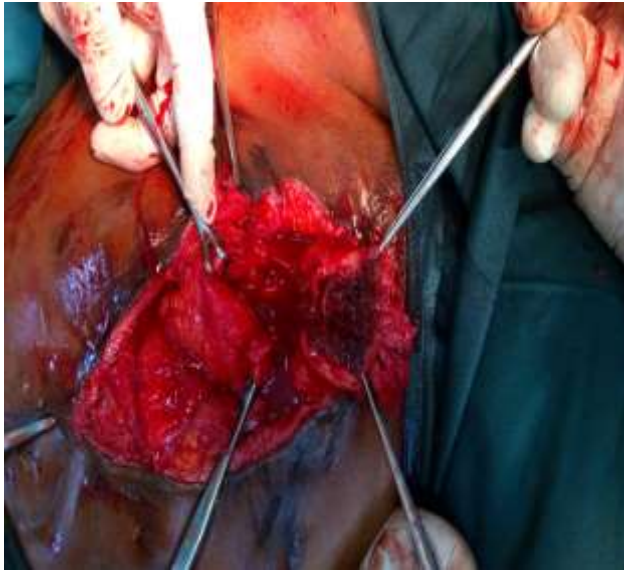


Figure 1: Excision of fistulous tract between the intestine and the skin during surgery

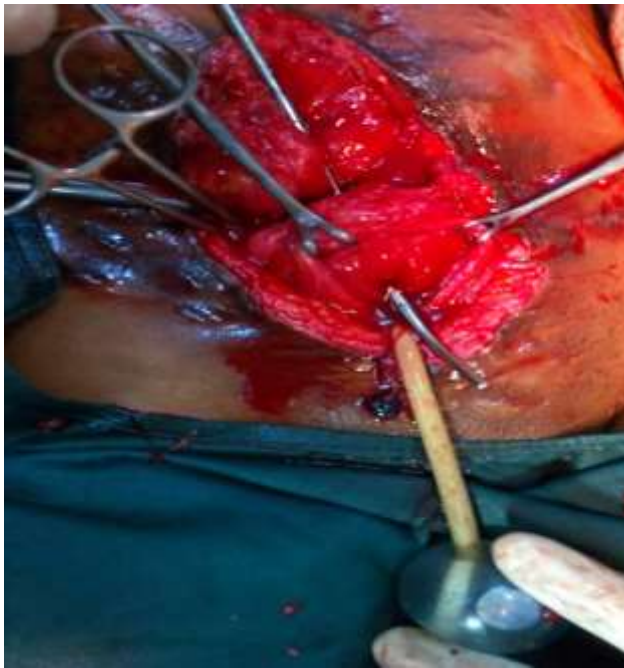

Figure 2: The bladder was opened during surgery and defect on the bladder was then identified

enterovesical fistula may be surgical or non surgical⁸. Our patient had operative management with good outcome.

This case is of considerable interest because it showed that both enterocutaneous fistula and enterovesical fistula can coexist in one patient. It also demonstrated that pelvic surgery can be a cause of this uncommon disease. The role of a single stage surgery in the correction of the two abnormalities was also described.

Conclusion

Enterovesical and enterocutaneous fistulae are uncommon but possible complications of ovarian cystectomy. Surgery is a useful management option with good prognosis. Both enterovesical and enterocutaneous fistula may be repaired in a single stage procedure.

Consent

Written consent was obtained from the patient.

Conflict of Interest

None

Contribution of Authors

All authors contributed to the management of this patient, writing this case report and they all gave their final approval for the article.

References

1. Vikram K. Enterocutaneous fistula; 2016. Available from emedicine.medscape.com/1372132.overview Accessed 14/5/17
2. Njeze GE and Achebe UJ. Enterocutaneous fistula: A review of 82 cases. *Niger J Clin Pract* 2013; 16: 174 – 7.
3. Pritts TA, Fischer DR and Fischer JE. Postoperative enterocutaneous fistula. In: Holzheimer RG, Mannick JA, editors. *Surgical Treatment: Evidence-Based and Problem-Oriented*. Munich:Zuckschwerdt; 2001. Available from: <https://www.ncbi.nlm.nih.gov/books/NBK6914/>
4. Ekwedigwe KC, Sunday-Adeoye I, Lengman S, Isikhuemen ME, Daniyan ABC, Yakubu EN, Eliboh MO and IEA Uguru. Enterovesical Fistula Complicating Myomectomy: A Case Report. *Open Journal of Urology* 2017; 7: 75 – 78.

5. Scozzari G, Arezzo A and Morino M. Enterovesical Fistulas: Diagnosis and Management. *Techniques in Coloproctology* 2010; 14: 293 – 300
6. Shakya A, Thapa M and Padhye SM. Enterocutaneous fistula: a rare complication following total abdominal hysterectomy. *Journal of Kathmandu Medical College* 2013; 2: 205 – 207
7. Lee S, Surgical Management of Enterocutaneous Fistula. *Korean J Radiol* 2012; 13(S1): S17 – S20
8. Golabek T, Szymanska A, Szopinski T, Bukowczan J, Furmanek M, Powrozniak J and Chlosta P. Enterovesical fistula: Aetiology imaging and management. *Gastroenterology Research and Practice* 2013, Article ID: 617967.