

Tuba ovarian abscesses formation from decidualized ovarian endometrioma after appendiceal endometriosis presenting as acute appendicitis in pregnancy

Erbil Dogan¹ M.D., Emre Okay¹ M.D., Bahadır Saatlı¹ M.D., Safak Olgan¹ M.D., Sulen Sarioglu² M.D., Meral Koyuncuoglu² M.D.

¹ Department of Obstetrics and Gynecology, Dokuz Eylul University, School of Medicine, Izmir, Turkey.

² Department of Pathology, Dokuz Eylul University, School of Medicine, Izmir, Turkey.

Corresponding Author:

Emre Okay, Department of Obstetrics and Gynecology, Dokuz Eylul University, School of Medicine, 35340, Balçova, Izmir, Turkey.

Email: dremreokay@hotmail.com

Tel/Fax: (+90) 2324123116

Received: 28 May 2011

Accepted: 30 July 2011

Abstract

Background: Acute appendicitis with appendiceal endometriosis is a very infrequently encountered condition during pregnancy. Decidualization is the hypertrophy of endometrial stromal cells by the effect of progesterone. Similarly, in pregnancy, ectopic stromal endometrial cells in endometriosis can also be transformed by the same mechanism and ectopic decidua (deciduosis) may occur.

Case: Here we report a 30 year old pregnant woman presenting twice with acute abdominal symptoms requiring surgery for appendiceal and ovarian endometriosis and deciduosis. We emphasize that decidualized endometriosis may first present during pregnancy with acute abdomen necessitating emergency laparotomy and complicating the course of gestation.

Conclusion: To our knowledge only 9 cases in which decidualized endometriotic tissue causing acute abdomen necessitating surgery during pregnancy were reported in the literature. What makes our case special is that the patient needed two laparotomies during the pregnancy period which was a very stressful situation for both the patient and the physicians.

Key words: Endometriosis, Deciduosis, Acute appendicitis, Tuba ovarian abscess.

Introduction

Acute appendicitis with appendiceal endometriosis is a very infrequently encountered condition during pregnancy which ranges between 3-8 deliveries per 10,000 (1). Decidualization is the hypertrophy of endometrial stromal cells by the effect of progesterone. Similarly, in pregnancy, ectopic stromal endometrial cells in endometriosis can also be transformed by the same mechanism and ectopic decidua (deciduosis) may occur (2).

Here we report a 30 year old pregnant woman presenting twice with acute abdominal symptoms requiring surgery for appendiceal and ovarian endometriosis and deciduosis.

Case Report

A 30-year old, gravida 1, para 0, woman at 24th week of pregnancy presented with right lower quadrant pain, fever and nausea. Axillary body temperature and pulse rate were 37.3°C and 104/min, respectively. Abdominal examination revealed tenderness, guarding,

and rebound tenderness at the right side of the uterus. White blood cell count was 19,500 cells/mm³ with 92.8% neutrophils.

The sonographic examination did not reveal any findings consistent with acute appendicitis exception for periceaceal fluid and it showed a normal intrauterine pregnancy. With a preoperative diagnosis of acute appendicitis, a laparotomy was done via a paramedian incision in the right side of the abdomen. Appendix was erythematous and appendectomy was performed.

The histopathological examination of the appendix revealed acute appendicitis with extensive deciduosis of the appendiceal wall of all the three layers. There were also glandular structures among the decidua which were positive with cytokeratin 7, while the adjacent appendiceal mucosa was negative. The diagnosis was endometriosis and decidiosis of appendix and acute appendicitis. The patient was discharged with antibiotherapy without further complaints.

One month later, at 28 weeks' pregnancy, the patient came again with left lower quadrant pain, high fever and vomiting. Her temperature and pulse rate were 38.5°C and 110/min, respectively. At physical examination, the patient had 7 months of pregnant uterus and acute abdominal findings consisting of mainly left lower quadrant tenderness. Laboratory results showed a white blood cell count of 23,800 cells/mm³. A pelvic sonogram revealed a normal intrauterine pregnancy at 28 weeks and free fluid between the intestinal structures and a 5 cm complicated left ovarian cystic mass compatible with tubo-ovarian abscess. At laparotomy with a median subumbilical incision, a small amount of purulent free fluid and extensive pelvic deciduositis covering all the pelvic peritoneal surfaces with left tuboovarian abscess was observed. The abscess was drained and left salpingectomy was performed.

Papillary excrescences were observed protruding into the lumen of the mass and

ovarian biopsies were obtained. The abdominal cavity was washed with warm saline solution and a drain was placed in the Douglas pouch for drainage which was removed 3 days later. Early postoperative recovery was uneventful but on the 5th postoperative day the patient had uterine contractions and tocolytic therapy was initiated with nifedipine. She gave birth to a 1400 gr healthy male baby with spontaneous vaginal delivery.

Histo-pathological examination revealed ovarian endometriosis with marked decidual changes and hemosiderin-laden macrophages as well as moderate amount of polynuclear leukocytosis in cyst wall. The final pathological report confirmed infected endometrioma with deciduositis. Postoperatively patient received tazocin antibiotherapy for 3 weeks and discharged from the hospital without further complications. At the second postpartum month she was completely recovered and her baby was doing well without any complications related to prematurity.

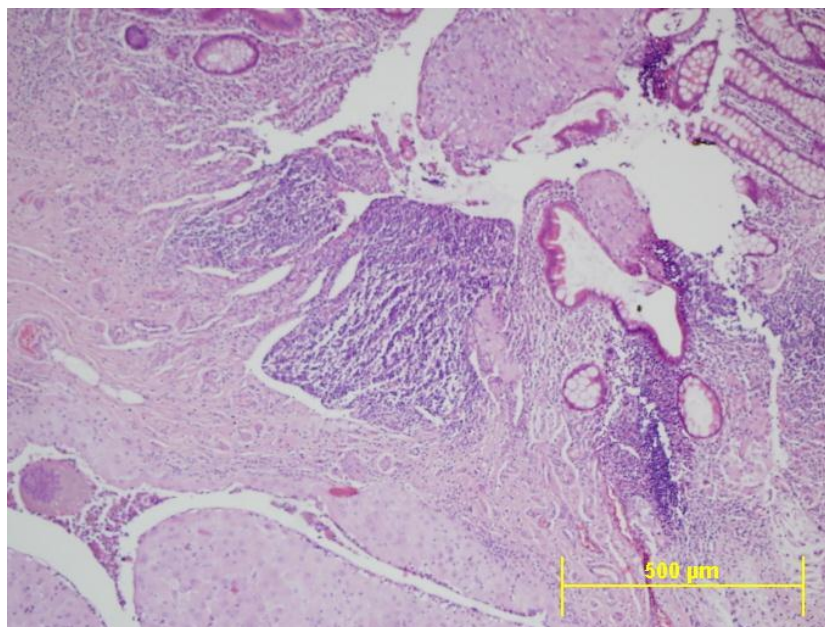


Figure 1. Extensive deciduositis of the appendiceal wall including mucosal, muscular and serosal layers. Note ulceration of the appendiceal mucosa and intraluminal decidual tissue. Also the glandular structures can be identified at the decidual submucosal area (H&E, original magnification X10).

Discussion

Endometriosis of appendix is a rarely encountered condition, occurring with the rate of 0.2-0.3% in appendectomies (3). Recently, its prevalence was reported to be 2.8% and it is noted that when pelvic endometriosis is present, odds ratio for presence of appendiceal endometriosis was 20.9 compared with general population (4). There were no studies established which explained mechanism of appendiceal involvement. Although it is usually asymptomatic, some cases may present with perforation, intussusception and mucocel (5).

Therefore, endometriosis of the appendix is often an incidental finding during abdominal operations. Deciduosis appendix is encountered during pregnancy and it is frequently identified at the serosal region of the appendix. At this localization the decidualisation was attributed to the physiological reaction of the pluripotential submesothelial stromal cells to hormonal influences of the pregnancy (6). In some cases, the desidualisation was associated with evident endometrial glands as in our case which could also be visualized by demonstration of cytokeratin 7 by immunohistochemistry (Figure 1) (1).

Adnexal masses complicating pregnancy have been reported to occur in average 1 in 600 of live births and approximately 11% of these are endometriomas (7). These decidual changes of endometriosis can be characterized by mural nodules and that macroscopically mimics a malignant tumor. Therefore, in literature, there are several reported cases and all of them have resulted in surgery during pregnancy because of the suspicious imaging findings (2). Separately, there is one reported case that had an infected endometrioma during pregnancy.

In conclusion, we emphasize that decidualized endometriosis may first present during pregnancy with acute abdomen

necessitating emergency laparotomy and complicating the course of gestation. To our knowledge only 9 cases in which decidualized endometriotic tissue causing acute abdomen necessitating surgery during pregnancy were reported in the literature (8).

What makes our case special is that the patient needed two laparotomies during the pregnancy period which was a very stressful situation for both the patient and the physicians.

References

1. Perez CM, Minimo C, Margolin G, Orris J. Appendiceal endometriosis presenting as acute appendicitis during pregnancy. *Int J Gynecol Obstet* 2007; 98: 164-167.
2. Barbieri M, Somigliana E, Oneda S, Ossola MW, Acaia B, Fedele L. Decidualized ovarian endometriosis in pregnancy: a challenging diagnostic entity. *Hum Reprod* 2009; 24: 1818-1824.
3. Blair NP, Bugis SP, Turner LJ, MacLeod MM. Review of the pathologic diagnoses of 2,216 appendectomy specimens. *Am J Surg* 1993; 165: 618-620.
4. Gustofson RL, Kim N, Liu S, Stratton P. Endometriosis and the appendix: a case series and comprehensive review of the literature. *Fertil Steril* 2006; 86: 298-303.
5. Faucheron JL, Pasquier D, Voirin D. Endometriosis of the vermiform appendix as an exceptional cause of acute perforated appendicitis during pregnancy. *Colorectal Dis* 2008; 10: 518-519.
6. Hauptmann J, Mechttersheimer G, Bläker H, Schaupp W, Otto HF. Deciduosis of the appendix. Differential diagnosis of acute appendicitis. *Chirurg* 2000; 71: 89-92.
7. Poder L, Coakley FV, Rabban JT, Goldstein RB, Aziz S, Chen LM. Decidualized endometrioma during pregnancy: recognizing an imaging mimic of ovarian malignancy. *J Comput Assist Tomogr* 2008; 32: 555-558.
8. Machida S, Matsubara S, Ohwada M, Ogoyama M, Kuwata T, Watanabe T, et al. Decidualization of ovarian endometriosis during pregnancy mimicking

malignancy: report of three cases with a literature

review. *Gynecol Obstet Invest* 2008; 66: 241-247.