

GOITER AND RIGHT CHEST CHYLOTHORAX AT KIGALI UNIVERSITY TEACHING HOSPITAL, RWANDA

E. Amendezo^{1,3,*}, K. Leway^{1,2}, S. Glassman², V. Dusabejamba^{1,3}, TD. Walker³

¹Kigali University Teaching Hospital, Department of internal medicine, Rwanda
²Human Resources for Health program – Rwanda

³Department of Internal Medicine, School of Medicine and Health Sciences, University of Rwanda

ABSTRACT

We report an unusual case of massive and rapidly re-accumulating right pleural effusion in a 27 years old woman with goiter. The fluid was milky in appearance, negative for bacteria and malignant cells, but rich in triglycerides, consistent with chylothorax. Sub-total thyroidectomy was performed with subsequent complete resolution of the pleural effusion.

Keywords: Goiter - chylothorax – Rwanda

RESUME

Nous rapportons un cas rare d'épanchement pleural droit massif, re-accumulant malgré le drainage thoracique, sur un terrain de goitre chez une femme de 27 ans. Le liquide de l'épanchement était d'apparence laiteuse, sans indice de présence de cellules bactériennes ou cancéreuses ; mais riche en triglycérides. Une thyroïdectomie subtotale faite, a été suivie par une résolution complète de l'épanchement pleural

Mots-clés : : Goitre - chylothorax – Rwanda

PRESENTATION OF THE CASE

A 27 year old woman presented to Kigali University teaching hospital for a three weeks history of shortness of breath and right sided chest pain. She described her symptoms as gradual, worsening overtime and limiting her daily activities. She had no history of fever, night sweats or recent weight loss.

Three months prior to presentation, she had been found to have an enlarged thyroid gland, symptoms of hyperthyroidism and the diagnosis of Graves' disease was made. She was receiving therapy with methimazole and propranolol.

She was a non-smoker and denied alcohol intake. Her past medical history was otherwise unremarkable.

On examination, the young lady with a Body Mass Index of 19.2 kg/m² appeared in fairly general condition. Her temperature was 37.2 celcius degrees, Blood pressure: 110/65 mmHg, Oxygen saturation of 96% while breathing ambient air. She had a respiratory rate of 24 cycles per minute and a pulse rate of 116 beats per minute.

The thyroid gland was diffusely enlarged, warm moist extremities with tremor as well as exophthalmos were noted.

Her chest examination was remarkable for absent breath sounds and vocal fremitus associated with dullness at the right side of the chest. The left side of the chest appeared normal. There was no palpable lymphadenopathy.

Full blood count, C-Reactive Protein, Erythrocyte sedimentation rate, serum urea & creatinine, blood sugar, electrolytes and transaminases were all in normal range. Serum albumin was slightly low 3.17 g/dl (NR: 3.20 –

4.50). Fasting lipid profile was also normal except for triglycerides level that was mildly decreased 90.5 mg/dl (NR: 120 - 200). Serum thyroxine (T4) was 17.5 pmol/l (NR: 12.0-22.0), triiodothyronine (T3) 14.4 pmol/l (NR: 3.10-6.80), and Thyroid Stimulating Hormone (TSH) 0.01 uIU/ml (NR: 0.27-4.20). Before starting therapy for suspected Graves' disease, TSH was 0.012 uIU/ml, T4: 32 pmol/l, T3: 10.0 pmol/l. Serological tests for thyroid antibodies were not done. Postero-anterior Chest Xray was notable for a large right sided pleural effusion

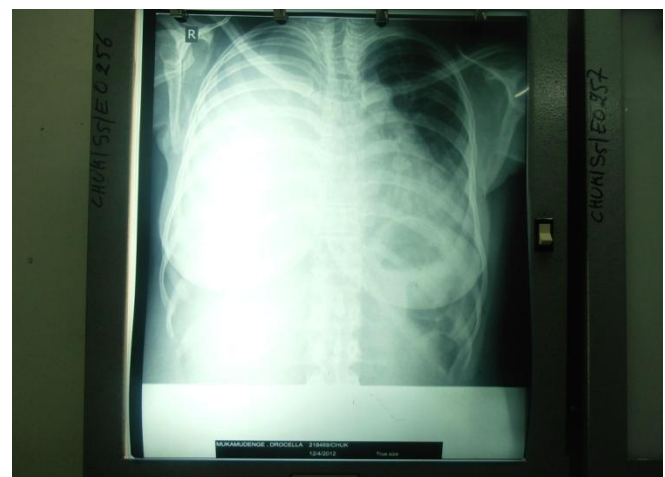


Figure 1: Chest radiograph on admission day

A chest tube was inserted in the right pleural space and drained milky-white fluid, consistent with chylothorax (Figure 2).

*Correspondence to: Etienne Amendezo
Kigali University Teaching Hospital, Department
of internal medicine, Rwanda
Tel: + (250) 788858756
E-mail: amendezoe@gmail.com

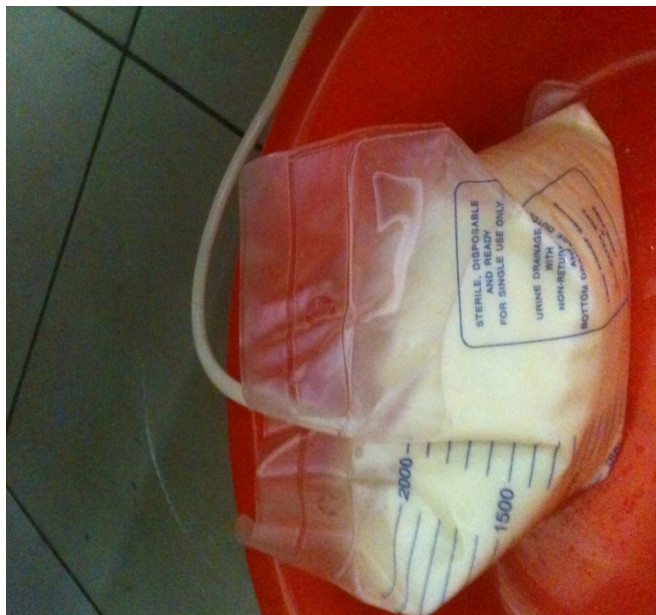

Figure 2: Chylous pleural fluid

Analysis of the fluid showed a cholesterol content of 1.3 mmol/l and triglycerides content of 7.19 mmol/l (NR<1.24). There were numerous white blood cells with 100% neutrophils and with no evidence of malignant cells. Protein count in the pleural fluid was 22.7 g/dl, and glucose 10 mmol/l. LDH and pH on pleural fluid were not done.

A chest tube was left in the right pleural space for 21 days because pleural effusion re-accumulated at a rapid rate, to an extent that the tube drained a mean of 1000 to 1500 mls of milky fluid per day.

A thyroid ultrasound confirmed presence of a homogeneous goiter. A thoracic CT scan including the neck revealed an enlarged thyroid gland particularly the left lobe which extended caudally and obstructed the thoracic inlet. The trachea appeared displaced toward the right side but without luminal narrowing. We hypothesized that the obstructing goiter was the cause of chylothorax, the patient was recommended for low fat/ low triglyceride diet as part of conservative management for chylothorax. However, after 21 days of persistent effusion despite drainage, failure of conservative measures to resolve chylothorax was concluded and the patient was then referred to surgery for assessment and eventual thyroidectomy.

Near total thyroidectomy was performed on the 30th day of admission to hospital; and resulted in complete resolution of the effusion (after five days of surgery) and significant clinical improvement.

At six weeks follow up visit, our patient was in good general condition and free of symptoms. The patient was given a diagnosis of right chylothorax secondary to retrosternal goiter on ground of Graves' disease

DISCUSSION

In this young female patient with an enlarged thyroid gland (suspected to be due to Graves' disease) and

chylothorax without clear evidence of malignancy, the cause of chylothorax was thought to be compression of the thoracic duct by a retrosternal goiter.

Chylothorax is a type of lipid containing effusion. Lipid pleural effusions are classically known when milky or

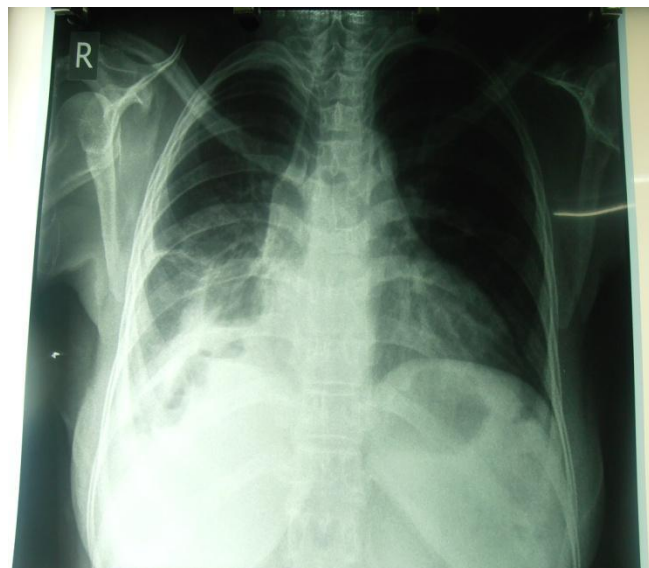


Figure 3 : chest radiograph 14 days after thyroidectomy

In our patient, the first thoracentesis brought turbid-appearing fluid, which was at first clinically thought to be a complicated parapneumonic effusion or an empyema particularly because infectious pleural effusions are some of the frequent causes of admission in Rwanda. Nevertheless, there was no laboratory confirmation of empyema or complicated parapneumonic effusion, although pleural fluid analysis showed numerous leucocytes with neutrophilic predominance, gram stain and cultures for bacteria and mycobacteria) were negative.

Also, on the following thoracentesis, the pleural fluid looked more milky than turbid, which was pointing more to a lipid pleural effusion than to empyema; the initial absence of fevers or other clinical signs of a septic syndrome being another argument.

A triglyceride concentration >110 mg/dL (1.24 mmol/l) is virtually diagnostic, but the presence of chylomicrons confirms the diagnosis of chylothorax; both of the above criteria may help in the differentiation of the two existing forms of lipid effusions, chylothorax and cholesterol effusion or pseudochylothorax; whose pathogenesis, etiology, diagnosis, management are different [1,5].

Chylothorax is defined by the presence of chyle in the pleural space resulting from obstruction or disruption of the thoracic duct or one of its major tributaries where as cholesterol effusion is typically the result of long standing effusion with elevated cholesterol levels in the pleural space [1, 8, 12].

Our patient's pleural fluid content was high in triglycerides and low in total cholesterol which argued against the presence of another sort of cholesterol containing effusion.

In a series by Fabiano M. et al., a pleural fluid triglyceride level >110 mg/dL (1.24 mmol/l) was associated with a high chance of chylothorax ([11].

Traditionally, chyle is a non-inflammatory, bacteriostatic fluid with a lymphocyte predominance of the total nucleated cells, usually greater than 80% [12].

In a series published by Agrawal and colleagues, approximately half of the study population had a lymphocyte percentage greater than 80% [12]. According to various authors, when lymphocytes are not predominant in a chylothorax pleural fluid, the clinician should consider and search for other causes of the pleural effusion [4, 8, 12].

In our case, the pleural fluid cell count showed numerous white cells with a neutrophilic predominance. We speculated that a possible superimposed infectious process was responsible for the neutrophil, but gram stain, Ziehl Nelsen stain and cultures were all negative.

Etiologies of chylothorax vary depending on the cause. In adults, traumatic causes including iatrogenic injury to the thoracic duct during cardiac surgery, Coronary Artery Bypass Graft (CABG), oesophageal resection, left subclavian catheterization, etc. represent the most frequent causes [4, 5].

Non-surgically related traumatic causes include penetrating injuries from gunshot and knife wounds among others while non-traumatic etiologies of chylothorax include malignancy, sarcoidosis, tuberculosis, cirrhosis, mediastinal lymph node enlargement, retrosternal goiter, superior vena cava thrombosis, amyloidosis and filariasis. Among non-traumatic cases, malignancy is the most common cause of a chylothorax and accounts for 32% of all cases. All other causes of non-traumatic chylothorax together represent about 18% of all chylothorax cases [4, 5].

Computed Tomography (CT) of the thorax and abdomen is typically needed to identify the presence of lymphadenopathy or masses and the site of thoracic duct rupture. If the site of leak still remains uncertain, lymphangiography or lymphoscintigraphy may be helpful. [8].

In our case, CT chest and abdomen were performed and a large and caudally extending thyroid was found. We submit that complete resolution of pleural fluid leak following thyroidectomy confirmed the hypothesis that our patient's chylothorax due to thoracic duct compression.

According to literature, half of all chylothoraces are right-sided, one-third is left-sided, while the remainder are bilateral [1,4,6]. Usually, the course of the thoracic duct explains why injury to the duct above the level of the fifth thoracic vertebra produces left sided chylothorax and injury below that level, a right-sided chylothorax [4]. In fact anatomically, the thoracic duct passes by the right side of the thoracic cage from its entry at the aortic aperture and passes from right to the left at the fourth to fifth thoracic vertebra [4,13].

A right sided chylothorax was surprising and not fully understood since compression of the duct by a retrosternal goiter would have had occurred at the very distal part of the duct. It was hypothesized however, that either our patient had a thoracic duct anatomically located at her right side, or that compression of the duct by the goiter provoked increased pressure in the duct lumen and caused injury to the duct at a point down the point of crossing from right to left of the thoracic cage.

According to the extant literature, treatment of chylothorax includes management of underlying condition, medical therapy which may include low fat diet and octreotide - which has potential to reduce the splanchnic blood flow and reduce the absorption of triglycerides - as well as surgical approaches (pleurodesis or ligation of the thoracic duct) [1, 4, 8, 14].

Conservative management should be tried first because the thoracic duct leak closes spontaneously in nearly 50% of patients according to many authors [1, 14]. However, some authors suggest that patients with chylothorax almost always require aggressive nutritional support to reverse hypovolaemia, immunosuppression, protein and electrolyte deficiencies [1, 15].

Surgical approaches need particularly to be considered when chyle leak exceeds one to one and a half litres per day for five days, or when there is a persistent leak for more than 14 days despite conservative management especially because delaying surgery may expose the patient to severe immunosuppression [1, 16].

For our patient, thyroidectomy resulted in complete control of the fluid leak, there was no need to do surgery to repair the thoracic duct. However, our patient had a delayed operation due to logistic problems in obtaining operating theatre time.

Case reports of Chylothorax due to goiter have been described in the Western literature, but not in Africa. Goiters are far more common in our settings and we hope that presentation of this case urges other clinicians in similar settings to broaden their differential diagnosis when faced with a goiter and a pleural effusion and to consider non-infectious causes in patients presenting with milky or turbid fluid pleural effusions.

REFERENCES

1. E.E.McGrath et al. Chylothorax: etiology, diagnosis and therapeutic options. *Respiratory Medicine* (2010) 104, 1-8
2. Colice GL. Et al. Medical and surgical treatment of parapneumonic effusions: An evidence based guideline. *Chest*. 2000 ; 118(4):1158-71.
3. Richard W.Light. Parapneumonic effusions and empyema, *Proceedings of the American thoracic society*. Vol. 3, No. 1 (2006), pp. 75-80
4. J. Terrill Huggins. Chylothorax and Cholesterol Pleural Effusion. *Seminars in respiratory and critical care medicine*. Vol. 31, Number 6. 2010
5. Hillerdal. G. Chylothorax and pseudochylothorax. *European Respiratory Journal*. 1997; 10: 1157-1162
6. Bassam K D., Sami S K. Giant Substernal Goiter with Chylothorax. *Asian Cardiovasc Thorac Ann* 2003;11:165-166

7. P. Bławata et al. Chylothorax secondaire à un goitre rétrosternal. *Journal de Chirurgie* (2009) 146, 324–328
8. Nayan D. et al. Idiopathic chylothorax in a young man. *BMJ Case Reports* 2012; doi:10.1136/bcr-2012-007318
9. A Medford, N Maskell. Pleural effusion: Review. *Postgrad Med J* February 2011 Vol 87 No 1024
10. Naoki H et al. Graves' Disease with Intractable Diarrhea, Chylous Ascites, and Chylothorax: A Case Report. *Thyroid*. Vol 17, Number 12, 2007
11. Fabien Maldonado et al., Pleural fluid characteristics of chylothorax. *Mayo clin proc.* 2009 Feb, 84 (2): 129-133
12. Agrawal V, Sahn SA. Lipid pleural effusions. *Am J Sci.* 2008 Jan;335(1):16-20
13. Doerr CH, Miller DL, Ryu, JH. Chylothorax. *Semin Respir Crit Care.* 2001 Dec;22(6):617-26
14. Kalomenidis I., Octreotide and chylothorax. *Curr Opin Pulm Med.* 2006 Jul;12(4):264-7
15. De Beer HG, et al., chylothorax. *Neth J Med* 2000 Jan;56(1):25-31
16. Zabeck H, et al., Management of chylothorax in adults: when is surgery indicated? *Thorac Cardiovasc Surg.* 2011 Jun;59(4):243-6