

Case Report

Leber plus disease

PW. Atipo-Tsiba^{1,*}

¹Service d'Ophtalmologie, CHU de Brazzaville, Rep. Congo

ABSTRACT

Introduction: Leber's neuropathy is a rare disease. The "Leber Plus" is exceptional, is associated with a severe neurological disorder. This presentation was intended to describe a case of Leber Plus.

Methods: A 45-year-old man consulted our department for bilateral blindness since 15 years

Results: On both sides there was no light perception, optic atrophy with serious peripapillary vessels sclerosis. There was a flaccid paraplegia. The 11 778 mitochondrial DNA mutation was identified.

Conclusion: The prevalence of the Leber's neuropathy is probably underestimated in black Africa because of lack of molecular biology laboratory.

Keywords: Leber Plus disease- Blindness- Paraplegia

RESUME

Introduction: La neuropathie de Leber, est une pathologie rare. Le "Leber Plus" est exceptionnel, est associé avec les troubles neurologiques sévères: Nous rapportons ici une observation d'un cas de Leber Plus.

Méthodes: Un patient âgé de 45 ans a consulté notre département pour les problèmes de cécité depuis 15 ans.

Résultats: De deux côtés, il n'y avait pas la perception de lumière, une atrophie optique avec sclérose des vaisseaux péri papillaires a été objectivée. Il y avait une paraplégie flaccide. La mutation mitochondriale 11778 a été identifiée.

Conclusion: La prévalence de neuropathie de Leber est probablement sous-estimée dans la population africaine à cause de manque de laboratoire de biologie moléculaire pour le diagnostic.

Mots clés: Maladie de Leber Plus- Cécité- Paraplégie

INTRODUCTION

The Leber's neuropathy is a rare hereditary optic disorder, caused by a mutation of mitochondrial DNA in the cytoplasm of the egg [1]. Three primary mutations are often found: 11778, 14484 and 3460. The most common is 11 778, it is also the one with the worst visual prognosis [2]. During the acute stage, the optic disc is mildly hyperaemic and swollen with irregular dilatation of the pre- and peripapillary capillaries (telangiectatic microangiopathy). There no leakage of fluorescein from telangiectatic. Typically, patients between 15 and 35 present a sequential and painless loss of vision in each eye. Disturbances of cardiac conduction may be associated realizing the Wolff-Parkinson-White's syndrom [3], the Leber Plus disease is its association with the serious neurological disorders [4]. We report the first case of that illness (Leber Plus) described and confirmed by molecular biology in Republic of Congo.

MEDICAL OBSERVATION

Mr. BG 45 years old described by the age of 30 years the onset of the right eye visual loss, gradually over a period of two years, followed by complete blindness in that eye. The assessment made was normal (blood culture, blood count, HIV status, analysis of cerebrospinal fluid, brain and orbit scan). Corticosteroid therapy was instituted in mind retro bulbar optic neuritis, without success. After a respite of nearly three years, a second episode was marked by a decline in vision to the left eye this time,

installation fast enough. In six months he was unable to move himself. At 35 years of age he was blind. Around the age of 41, had installed a right monoplegia of the lower limb without fever or pain. A second paraclinical identical to the first was done at the University Hospital of Brazzaville, noted that it had nothing special. Immunosuppressive treatment was instituted in the event of a demyelinating disease, no improvement was noted. At the age of 45 years, the clinical picture was enriched by a paralysis of the left lower limb in a few months, always in the same context, without fever and without pain. His status was as follows: both sides no light perception, severe optic atrophy, peripapillary sclerosis vessels (figure1 and figure1b), flaccid paraplegia. Cardiovascular status, orbit and brain scan, blood count, blood culture, sedimentation rate, HIV status, lyme serology and cerebrospinal fluid analysis were unremarkable. The fluorescein angiography had been performed on two occasions attempted injection of this product leading to vagal shock. The 11 778 mitochondrial DNA mutation was identified.

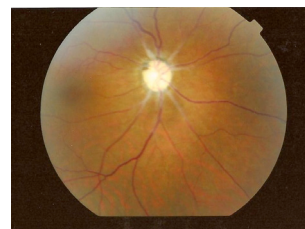

Figure 1a

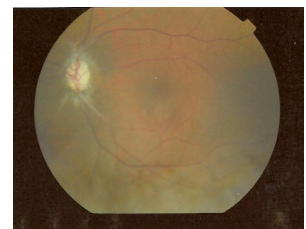


Figure 1b

Figures 1a - 1b: Optic atrophy and severe peripapillary vessels sclerosis in Leber Plus disease linked to 11 778 mitochondrial DNA mutation

* Correspondence to: Atipo-Tsiba PW, MD
Department of Ophthalmology
CHU de Brazzaville PoBox 32 Brazzaville
Assistant to the university of Marien Ngouabi - Brazzaville
Tel: 00242055513485
E-mail: atipo.kani@gmail.com

DISCUSSION

Mr. BG presented a clinical and biological status typical of Leber's optic neuropathy. The symptoms of the right eye began at the age of 30 years. This result is consistent with the results of Grenet T et al [5] in a retrospective study of 10 cases had found the first signs appeared between 14 and 47 years. However genotypically proven cases have been described to extreme ages [6, 7]. The 11 778 mitochondrial DNA mutation found in this patient is the most encountered, it is present in approximately 60% of affected families [8]. The eye symptoms of this patient were particularly severe, complete blindness without recovery. This table can be explained by the conjunction of two factors of poor prognosis, a relatively late start and the 11 778 mutation. Indeed, the visual prognosis depends on age of onset and type of mutation. When the loss of vision begins in childhood, it is more progressive

with a better final functional recovery [9, 10]. In carriers of the mutation 11778, evolution is often pejorative, with more than 90% of a final visual acuity less than 1 / 10 [11, 12]. Spruijt et al [10] estimated at 64% improvement of final visual acuity in 14484t mutation. The early childhood and the existence of a mutation other than the 11 778 are factors of good prognosis; visual recovery may be almost complete [13]. The installation of paraplegia in this context, 11 778 mutation identified, and in the absence of any proven etiology, diagnosis of Leber Plus disease was selected.

CONCLUSION

The prevalence of Leber's neuropathy is probably underestimated in black Africa because of the lack of molecular biology laboratory. This diagnosis avoids further investigations and unnecessary treatment.

REFERENCES

1. Momtchilova M, Pelosse B, Saliba M et al. Baisse d'acuité visuelle récidivante dans la neuropathie optique de Leber : a propos d'un cas. *Journal Français d'Ophtalmologie* Vol 31, N0 4 – avril 2008 pp. 409-415.
2. Mackey DA, Oostra RJ, Rosenberg T et al. Primary pathogenic mtDNA mutations in multigeneration pedigrees with Leber hereditary optic neuropathy. *Am J Hum Genet*, 1996; 59:481-5.
3. Nikoskelainen EK, Savontaus ML, Huoponen J, Antila K, Hartiala J. Pre-excitation syndrom in Leber's hereditary optic neuropathy. *Lancet*, 1994; 344:857-8.
4. Nikoskelainen EK, Martila RJ, Huoponen J et al. Leber's <plus>: neurological abnormalities in patients with Leber's hereditary optic neuropathy. *J Neurol Neurosurg Psychiatry*, 1995; 59:160-4.
5. Grenet T, Berthout A, Boumendil J, Vignal -Clermont C, Morax S. La neuropathie optique héréditaire de Leber, étude rétrospective sur dix cas. *Journal Français d'Ophtalmologie* Vol 32, N0 HS1 – avril 2009 p. 77.
6. Leveziel N, Guépratte N, Lebuissou DA. Neuropathie optique de Leber se présentant comme une neuropathie alcool-tabagique. *Journal Français d'Ophtalmologie* Vol 27, N01 – janvier 2004 pp. 53-56.
7. Nikoskelainen EK, Huoponen K, Juvonen V et al. Ophthalmologic findings in Leber's hereditary optic neuropathy, with special reference to mtDNA mutations. *Ophthalmology*, 1996; 103:504-14.
8. Man PY, Griffiths PG, Brown DT et al. The epidemiology of Leber hereditary optic neuropathy in the north-east of England. *Am J Hum Genet*, 2003; 72: 333-9.
9. Riodan-Eva P, Sanders MD, Govan GG et al. The clinical features of Leber's hereditary optic neuropathy defined by the presence of a pathogenic mitochondrial DNA mutation. *Brain*, 1995; 118: 319-37.
10. Spruijt L, Kolbach DN, de Coo RF et al. Influence of mutation type on clinical expression of Leber hereditary optic neuropathy. *Am J Ophthalmol*, 2006; 141: 676-82.
11. Newman NJ, Lott MT, Wallace DC. The clinical characteristics of pedigrees of Leber's hereditary optic neuropathy with the 11 778 mutation. *Am J Ophthalmol*, 1991; 111: 750-62.
12. Stone EM, Newman NJ, Miller NR et al. Visual recovery in patients with Leber's hereditary optic neuropathy and the 11 778 mutation. *J Clin Neuro-ophthalmol*, 1992; 12: 10-4.
13. Kawassaki A, Borruat FX. Rapid onset of visual recovery following acute visual loss due to Leber's hereditary optic neuropathy. *Rev Neurol*, 2005; 161: 599-601.