

Disseminated Cysticercosis in Rwanda—Case Report of a Patient Presenting with Difficulty with Walking and Skin Nodules

Authors: J. Tuan^{1,*}; L. Kailani^{2,3}; P. Ngabitsinze³; S. Umuganwa⁴; F. Munyaneza³; E. Musoni^{4,5}; A. L. Canales⁶; M. Nkeshimana^{3,7}

Affiliations: ¹Yale University School of Medicine, New Haven, Connecticut, Department of Internal Medicine, Section of Infectious Diseases; ²Geisel School of Medicine at Dartmouth, Hanover, New Hampshire; ³University of Rwanda College of Medicine and Health Sciences, Kigali, Rwanda, Department of Internal Medicine; ⁴University of Rwanda College of Medicine and Health Sciences, Kigali, Rwanda, Department of Pathology; ⁵University Teaching Hospital of Kigali, Kigali, Rwanda, Department of Pathology; ⁶Brigham and Women's Hospital, Boston, Massachusetts, Department of Dermato-pathology; ⁷University Teaching Hospital of Kigali, Kigali, Rwanda, Department of Accident and Emergency Medicine.

ABSTRACT

Human cysticercosis is a parasitic disease caused by larval cysts of the *Taenia solium* tapeworm. The pathogenesis of disseminated cysticercosis involves migration of *Taenia solium* embryos from the hepatoportal system to organs and tissues in the body. Symptoms may range anywhere from neurologic sequelae such as seizures, to skin manifestations such as subcutaneous nodules [1-2]. Disseminated cysticercosis is a rare complication of cysticercosis, and globally, fewer than 50 cases of disseminated cysticercosis are documented [1-3]. Human cysticercosis is endemic to Rwanda with a seroprevalence of 7% [4]. An increased prevalence of cysticercosis has been noted among epileptic persons in the southern province of Rwanda [5].

We describe a 46-year-old Rwandan woman from Kamonyi District, in the southern province of Rwanda, who presented with a two-week history of bilateral lower limb weakness, causing difficulty walking. She had associated fevers and headache. She was febrile and tachycardic, with decreased lower extremity strength and subcutaneous nodules on her trunk and extremities. Laboratory data demonstrated leukocytosis with neutrophilic predominance and mild eosinophilia. Excisional biopsy of a subcutaneous nodule revealed a cyst containing a protoscolex with suckers, ramifying cistern, and calcareous bodies; brain magnetic resonance imaging demonstrated diffuse, cystic cerebral, cerebellar, and soft tissue lesions—consistent with disseminated cysticercosis.

She was treated with 14 days of albendazole and prednisolone, and afterwards, noted restored ability to walk independently. In this case, prompt diagnosis and treatment of disseminated cysticercosis led to dramatic clinical improvement.

Keywords (MeSH): Cysticercosis; Neurocysticercosis; *Taenia Solium*; Rwanda

CASE PRESENTATION

A 46-year-old woman from Kamonyi District in the southern province of Rwanda with no significant past medical history presented to University Teaching Hospital of Kigali with a two-week history of acute-onset bilateral lower limb weakness and calf

pain. She rated the pain at a three out of ten in severity, and she stated that this pain had caused her to have difficulty standing. The pain was associated with a two-week history of intermittent fevers, headache, and generalized weakness. She also reported a three-year history of multiple, painless subcutaneous nodules in her neck, chest, and arms. The patient was a farmer who had previously lived

*Corresponding author: Corresponding Author: Jessica Tuan, MD, MS, Email: Jessica.Tuan@Yale.edu, Phone: 630-532-3325, Address: 333 Cedar Street, PO Box 208022, New Haven, Connecticut, 06510;

Potential Conflicts of Interest (Col): All authors: no potential conflicts of interest disclosed; **Funding:** All authors: no funding was disclosed; **Academic Integrity:** All authors confirm that they have made substantial academic contributions to this manuscript as defined by the ICMJE; **Ethics of human subject participation:** The study was approved by the local Institutional Review Board. Informed consent was sought and gained where applicable; **Originality:** All authors: this manuscript is original has not been published elsewhere; **Type-editor:** Matthew Cardillo (USA)

Review: This manuscript was peer-reviewed by three reviewers in a double-blind review process;

Received: 21st Sept 2019; **Initial decision given:** 26th Oct 2019; **Revised manuscript received:** 21st January 2020; **Accepted:** 25th January 2020

Copyright: © The Author(s). This is an Open Access article distributed under the terms of the Creative Commons Attribution License (CC BY-NC-ND) (click here) which permits unrestricted use, distribution, and reproduction in any medium, provided the original work is properly cited. **Publisher:** Rwanda Biomedical Centre (RBC)/Rwanda Health Communication Center, P.O.Box 4586, Kigali.

ISSN: 2079-097X (print); 2410-8626 (online)

Citation for this article: J. Tuan; L. Kailani; P. Ngabitsinze et al. Disseminated Cysticercosis in Rwanda—Case Report of a Patient Presenting with Difficulty with Walking and Skin Nodules Rwanda Medical Journal. Vol 77, no 2, pp 1-4, 2020

in Nyaruguru District, an area with many pork farmers. Two years prior, she had moved to a rural area in Kamonyi District. She reported that she had been raising pigs on the farm in order to sell them, but denied ingestion of pork meat. She generally had poor hygiene practices.

Two days prior to her presentation, she had presented to the local district hospital in Rwanda with similar symptoms. There, she had laboratory data that demonstrated a leukocytosis with a white blood cell count of 16,550 cells/ μ L. C-reactive protein was elevated at 96 mg/dL. Hepatitis B virus surface antigen and Hepatitis C virus antibody were negative.

At our hospital, on physical examination, she was a well-nourished female in no acute distress. She had a temperature of 39.2°C, heart rate of 110 bpm, blood pressure of 109/63 mmHg, respiratory rate of 22 cpm, and oxygen saturation of 93% on room air. She had several firm, non-tender, mobile nodules, approximately 1.5 cm in diameter. One nodule was located in the sternal area, another in the right anterolateral chest, two in the right neck, and a cluster of three nodules were located in her right forearm (Figure 1). She had tenderness to palpation of the right antecubital region and her bilateral calves. The range of motion of her bilateral lower extremities was slightly limited due to this pain. Aside from strength of 4/5 in the bilateral lower extremities, she was neurologically intact with preserved motor function and sensation. She did not demonstrate clinical signs of muscular pseudohypertrophy. Ophthalmoscopic exam was not performed.

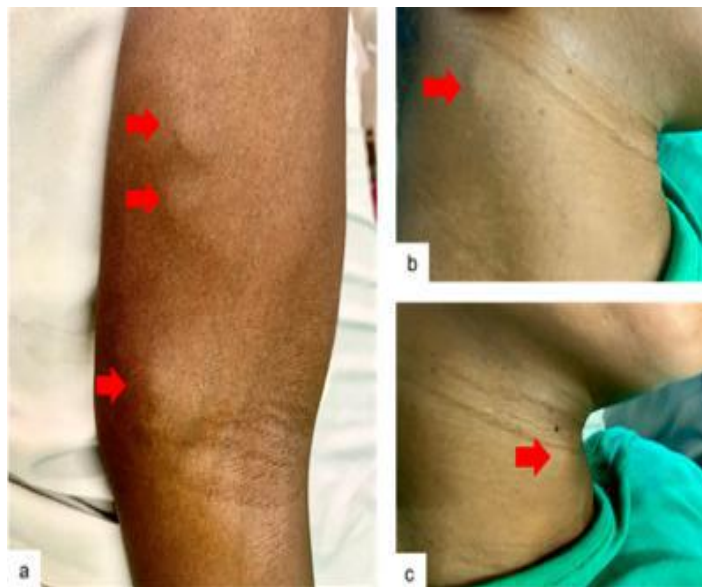


Figure 1. a) Right forearm with a cluster of subcutaneous nodules, approximately 1.5 cm in diameter. **b)** Right neck subcutaneous nodule. **c)** Right neck subcutaneous nodule

Laboratory data revealed a leukocytosis with a white blood cell count of 15,520 cells/ μ L with 81% neutrophils, 9% lymphocytes, 6% monocytes, and 4% eosinophils. Hemoglobin was 9.3 g/dL with a mean corpuscular volume of 88.4 fL, and a platelet count of 389,000 cells/ μ L. Blood urea nitrogen was 2.3 mmol/L and creatinine was 40 μ mol/L. She had an aspartate transaminase of 22.2

U/L, alanine transaminase of 12.1 U/L. C-reactive protein was elevated to 101 mg/dL. Rapid Human Immunodeficiency Virus test and malaria thick smear were negative. Blood cultures revealed no growth. Stool ova and parasites and immunological tests for *Taenia solium* were not performed. Chest x-ray demonstrated no acute process.

The patient was admitted to our hospital and given intravenous fluids and started empirically on ceftriaxone. She was also started on empiric prednisolone to reduce inflammation. On day five, a fine needle aspirate of the right anterolateral chest wall nodule demonstrated significant fragments of acellular lamellate membrane, keratinous debris, and lymphocytes, which were suggestive of cysticercosis via Romanowski stain (Figure 2a).

The hematoxylin and eosin stain section from the excisional biopsy of the nodule showed a fibrous cyst containing a protoscolex with identifiable suckers and ramifying cistern. There was a loose channel-rich stroma, and calcareous bodies were readily noted (Figure 2b). Given the histopathologic findings, she was diagnosed with disseminated cysticercosis.

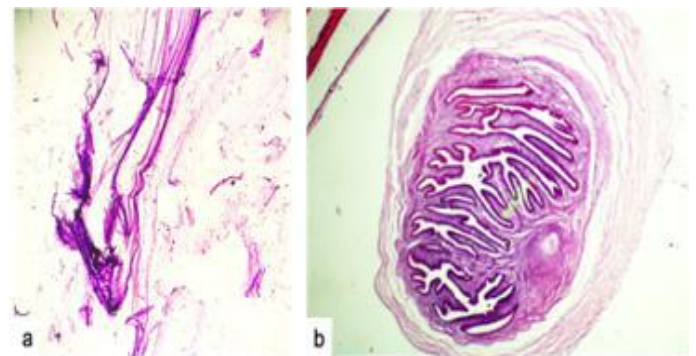


Figure 2. a) Fine needle aspirate of the right anterolateral chest wall subcutaneous nodule demonstrating significant fragments of acellular lamellate membrane (Romanowski stain, 100x magnification). **b)** The Hematoxylin and Eosin stain section from the excisional biopsy of the nodule showed a fibrous cyst containing a protoscolex with identifiable suckers and ramifying cistern. There was a loose channel-rich stroma and calcareous bodies were readily noted (Hematoxylin and Eosin stain, 100x magnification).

The patient was discharged with a planned thirty -day course of albendazole, but due to insurance issues and medication availability, only received a fourteen-day course. She received prednisolone starting at 40 mg PO daily for two weeks, followed by a steroid taper. The patient did not have imaging of peripheral extremities or musculature, but she was requested to follow-up outpatient for further brain imaging, which she eventually completed, three weeks post-discharge. Magnetic Resonance Imaging (MRI) of the brain revealed diffuse, cystic lesions with thin, non-enhancing walls with central hyperintense foci in the cerebrum, cerebellum, lateral ventricles, and craniofacial and neck soft tissues (Figure 3). These features were consistent with disseminated cysticercosis with vesicular stage neurocysticercosis with a racemose neurocysticercosis component. There were no features of muscular pseudohypertrophy noted on imaging.

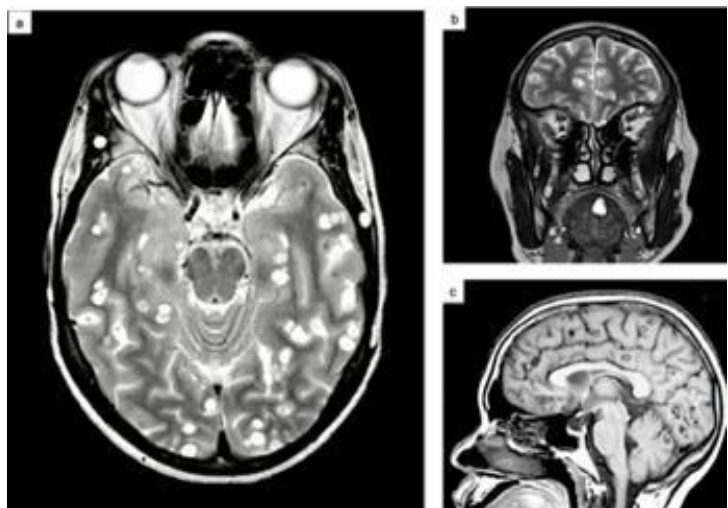


Figure 3. **a)** Brain Magnetic Resonance Imaging (MRI) transverse view demonstrated diffuse cystic lesions with thin, enhancing walls with central hyperintense foci in the cerebrum, cerebellum, lateral ventricles, and craniofacial and neck soft tissues, consistent with disseminated cysticercosis with vesicular stage neurocysticercosis with a racemose neurocysticercosis component. **b)** Brain MRI coronal view demonstrated diffuse cystic lesions with central hyperintense foci in the craniofacial and neck soft tissues. **c)** Brain MRI sagittal view demonstrated features of disseminated cysticercosis with vesicular stage neurocysticercosis with racemose neurocysticercosis component.

At follow-up three weeks after discharge, she denied headaches or fevers, but did report some episodes of intermittent dizziness. Although her physical exam was significant for the persistent subcutaneous nodules, which were similar in character to her initial presentation, she reported clinical improvement in ambulation, and she was able to stand independently.

DISCUSSION

Cysticercosis is a parasitic disease, caused by larval cysts of the *Taenia solium* tapeworm, commonly noted in areas such as Africa, Asia, and Latin America [1]. Cysticercosis can be transmitted via the fecal-oral route by ingestion of the eggs from the *Taenia solium* tapeworm carrier, rather than undercooked pork meat alone, and poor hygiene practices [2]. There has been a noted increased prevalence of cysticercosis in people with epilepsy in the southern province of Rwanda [5]. Prior literature reports that in Rwanda, approximately 21% of patients with epilepsy in southern Rwanda were positive for cysticercosis immunoblot testing, which detect glycoproteins of *Taenia solium* [5,6]. Both porcine and human cysticercosis are endemic in Rwanda, and cysticercosis is noted to be prevalent in areas where pigs are farmed and raised in Africa [7,8].

Disseminated cysticercosis is noted to be a rare complication of cysticercosis, and occurs when *Taenia solium* embryos disseminate from the hepatportal system to other organ systems and tissues in the body, including the central nervous system most commonly, as well as skeletal muscle, lungs, liver, eyes, and brain [3,9]. Cardiac muscle is less frequently involved [10]. Based on site of involvement, cyst burden and host immunity, symptoms of disseminated cysticercosis may include seizures, muscular hypertrophy, and dermatologic nodules [2]. Limited case reports describe such complications in

Rwanda. Less than 50 cases of disseminated cysticercosis have been reported worldwide [1-3]. Those cases were predominantly located in India [2,3]. Seroprevalence of human cysticercosis in Rwanda has been reported at 7% [4].

The diagnostic criteria for Neurocysticercosis were revised in 2016 [11]. Absolute criteria include histologic parasitic confirmation, subretinal cysts, scolex within a cyst in the brain. Neuroimaging criteria include Major [cystic lesions with no scolex, enhancing lesions, cysts which are multilobulated, calcifications], Confirmative [cyst resolution after cysticidal antiparasitic medications, resolution of single enhancing lesion spontaneously, migrating ventricular cysts on follow-up neuroimaging], and Minor [presence of hydrocephalus, leptomeningeal enhancement]. Clinical criteria include presence of anticysticercal antibodies or cysticercal antigen by standardized tests, systemic cysticercosis, household *Taenia* carrier, compatible clinical presentation, and habitation in an endemic area [11]. For a definitive diagnosis, the following is needed: one absolute criteria; or two major neuroimaging criteria plus any clinical criteria; or, one major and one confirmative neuroimaging criteria plus any clinical criteria; or, one major neuroimaging criteria plus two clinical criteria (including one major clinical criteria) along with other pathologies which yield similar neuroimaging findings excluded. Probable diagnosis involves those with one neuroimaging criteria along with evidence of exposure [11].

Serologic studies such as enzyme-linked immunoelectrotransfer blot should be performed to confirm the diagnosis of neurocysticercosis [12]. Excisional biopsy of skin or muscle lesion can help support a diagnosis of extraneural cysticercosis, although positive testing could reflect prior infection and negative tests do not exclude cysticercosis [13]. Patients with suspected neurocysticercosis should have neurological imaging performed [12]. MRI of the brain should be repeated at least every six months to assess for resolution of cystic components [12].

Antihelminthic drugs are indicated for patients with viable or degenerated cysts on neuroimaging, with the exception of high cyst burden, presence of calcified lesions only, or untreated hydrocephalus [12]. Use of these antiparasitic drugs have been reported to yield an improved prognosis [12]. However, anti-helminthic drugs can increase degeneration of viable cysts, thus leading to inflammation, cerebral edema, hydrocephalus, precipitating seizure activity, and ultimately lead to brain herniation [12]. Steroids are recommended to be administered before and concomitantly with anti-helminthic drug therapy, which has been associated with decreased seizures [12].

Albendazole is the typical treatment and has been shown to have superior central nervous system penetration, compared to praziquantel [1]. In cases from literature review, albendazole (15 mg/kg/day for 30 days) and praziquantel (50 mg/kg/day for a duration of 15-20 days), which are both cysticidal, had also been co-administered for treatment of cysticercosis

[1,2]. Implementation of these antiparasitic drugs decreases parasite load, leading to antigen release, which may cause local swelling and severe inflammation [1]. Thus, there is a role for corticosteroids in reducing inflammation, prior to and during initiation of antiparasitic drugs [1].

The *Taenia solium* tapeworm itself can be ingested from undercooked pork, and it is advised to cook meat thoroughly. Additional measures to reduce *Taenia solium* disease and thus cysticercosis include preventing pigs from scavenging food that may be infected with *Taenia solium* eggs, optimizing slaughterhouse meat inspection and sanitation, and administering anthelmintic medications to entire groups of pigs on farms and even human communities [14].

Enhanced access to clean water as well as improved sanitation and hygiene practices, such as handwashing, should be advised, especially given tapeworm carriers can re-infect themselves. Tapeworm carriers, especially if food handlers, can enhance the risk of cysticercosis acquisition [12, 14].

REFERENCES

- [1] S.Y. Park, M.H. Kong, J.H. Kim, and K.Y. Song, "Disseminated Cysticercosis," *J Korean Neurosurg Soc.*, Vol. 49, No. 3, pp. 190–193, Mar. 2011.
- [2] K.A. Bothale, S.D. Mahore, and S.A. Maimoon, "A rare case of disseminated cysticercosis," *Trop Parasitology*, Vol. 2, No. 2, pp. 138–141, 2012.
- [3] A. Banu, N. Veena, "A rare case of disseminated cysticercosis: Case report and review of literature," *Indian J Med Microbiology*, Vol. 29, pp. 180–3, 2011.
- [4] P. Odeniran and I.O. Ademola, "Zoonotic Parasites of Wildlife in Africa: A Review, *African Journal of Wildlife Research*," Vol. 46, No. 1, pp. 1–13, 2016.
- [5] R. Rottbeck, J.F. Nshimiyimana, P. Tugirimana, et. al., "High Prevalence of Cysticercosis in People with Epilepsy in Southern Rwanda," *PLoS Negl Trop Dis*, Vol. 7, No. 11, pp. 2558, Nov. 2013.
- [6] V.C.W. Tsang and M. Wilson, "*Taenia solium* cysticercosis: an under-recognized but serious public health problem," *Parasitology Today*, Vol. 11, pp. 124–6, 1995.
- [7] A. Zoli, O. Shey-Njila, E. Assana, J.P. Nguekam, P. Dorny, J. Brandt, and S. Geerts, "Regional status, epidemiology and impact of *Taenia solium* cysticercosis in Western and Central Africa," *Acta Trop*, Vol. 87, No. 1, pp. 35–42, Jun. 2003.
- [8] A.C. White, "Neurocysticercosis: A Major Cause of Neurological Disease Worldwide," *Clinical Infectious Diseases*, Vol. 24, pp. 101–15, 1997.
- [9] N. Saeed, A. Ehsan, and S.M. Vasanwala, "Disseminated cysticercosis incidentally diagnosed in a patient of fracture shaft of femur," *BMJ Case Reports*, Volume 2017, pp. 1–3, Feb. 2017.
- [10] B.K. Jain, S.S. Sankhe, M.D. Agrawal, and P.S. Naphade, "Dis-seminated cysticercosis with pulmonary and cardiac involve-ment," *Indian Journal of Radiology and Imaging*, Vol. 20, No. 4, pp. 310–313, Nov. 2010.
- [11] O.H. Del Brutto, T.E. Nash, A.C. White Jr, et. al., "Revised diagnostic criteria for neurocysticercosis," *J Neurol Sci* Vol. 372, pp. 202–210, 2017.
- [12] White AC Jr, Coyle CM, Rajshekhar V, et. al. Diagnosis and Treatment of Neurocysticercosis: 2017 Clinical Practice Guidelines by the Infectious Diseases Society of America and the American Society of Tropical Medicine and Hygiene. *Clin Infect Dis*, Vol. 66, No. 8, 2018.
- [13] Gutierrez Y. Cysticercosis, Coenurosis, and Sparganosis. *Diagnostic Pathology of Parasitic Infection with Clinical Correlation*, Gutierrez Y (Ed), Oxford University Press, Oxford, 2000, pp.635.
- [14] Kungu JM, Dione MM, Ejobi F, et. al. Risk factors, perceptions and practices associated with *Taenia solium* cysticercosis and its control in the smallholder pig production systems in Uganda: a cross-sectional survey. *BMC Infect Dis*, Vol. 17, No. 1, 2017.

CONCLUSION

In summary, disseminated cysticercosis is a rare complication of cysticercosis, which has been rarely described in literature from Rwanda. This patient presented with an atypical presentation of cysticercosis, with manifestations involving the skin, skeletal muscles, soft tissues, and brain.

Thus, clinicians in cysticercosis-endemic regions, such as Rwanda, should keep disseminated cysticercosis on the differential diagnosis when patients present with such atypical clinical manifestations, including diffuse organ involvement, in order to recognize and promptly treat affected patients. Implementation of a comprehensive, systematic method to document cases of cysticercosis and its sequelae—particularly in endemic regions, such as Rwanda—would be invaluable in elucidating the epidemiologic patterns and helping to prevent transmission of this important disease.