

Acute Lumbar Hernia: A Case Report

Said Albroumi¹, Yasser A. Razek²

¹Senior Consultant, General Surgery Department, Nizwa Hospital

²Consultant and Lecturer Radiodiagnosis Department, Aswan University Hospital.

Correspondence to: Yasser Abdel Razek Mohamed, SELIM, Email: a.razekyasser@gmail.com

Background: *Lumbar hernia is a rare condition with less than 300 cases reported in the literature before 1980 and about another 86 patient's conditions were discussed during last thirty years.*

Case presentation: *We report a 79-year old female patient who presented with attacks of repeated vomiting associated with mild epigastric pain and followed by appearance of right flank swelling. Right lumbar hernia was diagnosed by CT abdomen. She underwent repair after inversion of the sac and had a smooth postoperative course.*

Conclusion: *Lumbar hernias are rare cases, but should be pursued in diagnosis and treated rapidly because of the high rate of incarceration*

Keywords: Hernia; lumbar area; hernia repair.

Introduction

Although spontaneous lumbar hernia was described more than 200 years ago, it is a rare entity with fewer than 386 cases reported in the literature till present. The diagnostic approach and the surgical treatment of this type of hernia were dramatically changed in the last decade of the twentieth century with the introduction of the CT scan, mesh repair and laparoscopic surgery. In our case, we report a right lumbar hernia in old female patient with multiple co-morbidities. She underwent open surgical repair under local anesthesia.

Case Report

This is a case of a 79-year-old female patient, known to have hypertension and dyslipidemia. She had been bed ridden and underwent surgery 4 months earlier for open reduction and internal fixation of comminuted inter-trochanteric fracture of the right femur. The patient was admitted to Nizwa hospital due to repeated vomiting associated with mild epigastric pain and followed by appearance of a right side flank swelling since. (Figure1). On examination the swelling was around firm, non-tender and non-reducible with no overlying skin changes. It was around 10cm in diameter in the right lumbar area just below the 12th rib posteriorly. Soft tissue US showed that the swelling was cystic with clear fluid and small intra-cystic irregular echogenic fat adherent to its medial wall (Figure 2).

A CT scan which was done on the second day revealed defect in-between the muscles of the right postero-lateral abdominal wall, through which retroperitoneal peri-renal edematous fat had herniated to be located subcutaneously. The herniated fat showed dirty appearance with fat strands and marginal thin rim of fluid in hernia sac (Figure3). Review US confirmed that the cystic swelling became sub totally filled with refractory bright fat and thin rim of fluid (Figure 4).

A diagnosis of lumbar hernia with possible impending incarceration was made on the basis of the clinical and radiological findings.

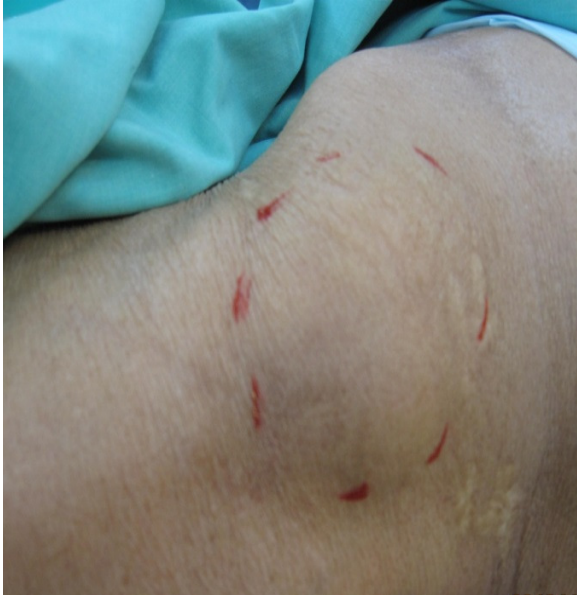

Figure 1. Photograph of 79-Year Old Female Patient with Right Lumbar Swelling

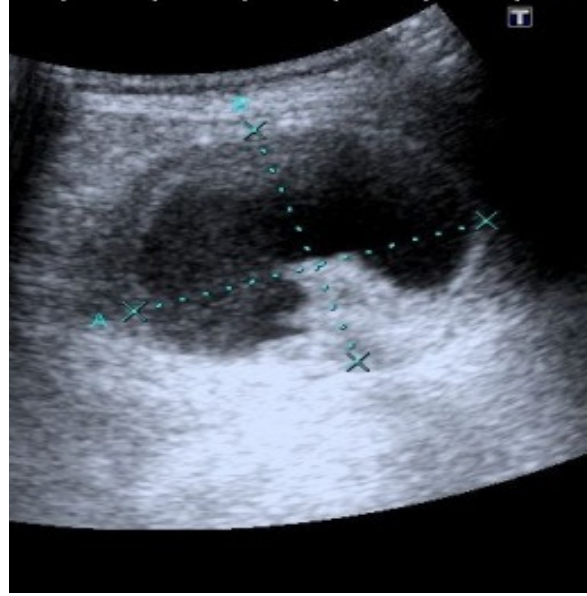


Figure 2: Initial Ultrasound of the right lumbar swelling, showed anechoic cystic mass with small intracystic echogenic fat component.

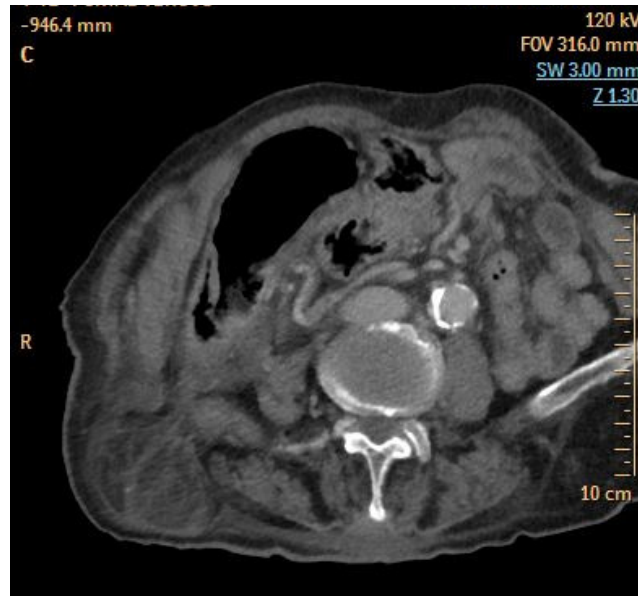


Figure 3a: CECT of the abdomen (a- axial and b- sagittal reformats) showed defect in-between the muscles of the right postero-lateral abdominal wall. Retroperitoneal peri-renal dirty fat, with multiple strands, is seen protruding through defect and forming subcutaneous fatty mass with thin marginal rim of fluid. No bowel loop inside. Right kidney is seen in its normal location.

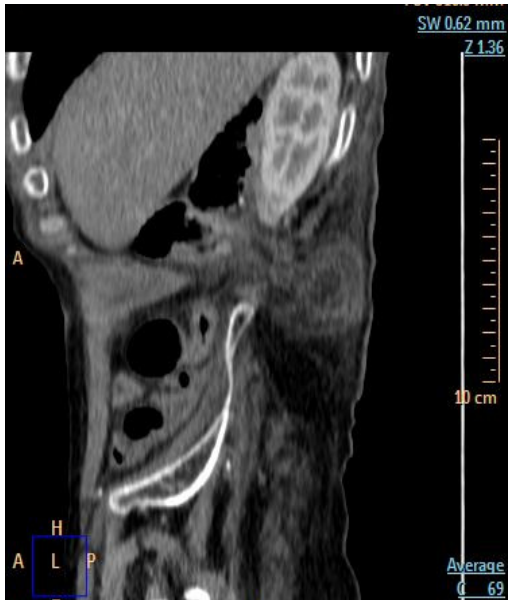

Figure 3b: CECT of the abdomen (a- axial and b- sagittal reformats) showed defect in-between the muscles of the right posterolateral abdominal wall. Retroperitoneal peri-renal dirty fat, with multiple strands, is seen protruding through defect forming

subcutaneous fatty mass with thin marginal rim of fluid. No bowel loop inside. Right kidney is seen in its normal location.

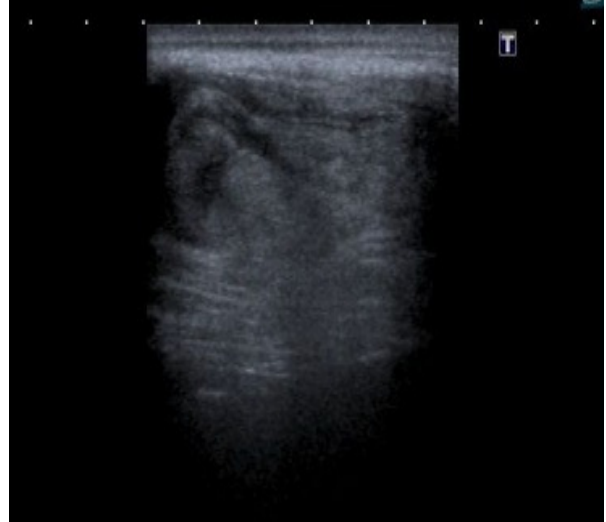

Figure 4: Review ultrasound which was done immediately after CECT and 24r hours from initial US, showed that the cystic lesion was sub totally filled with echogenic fat.

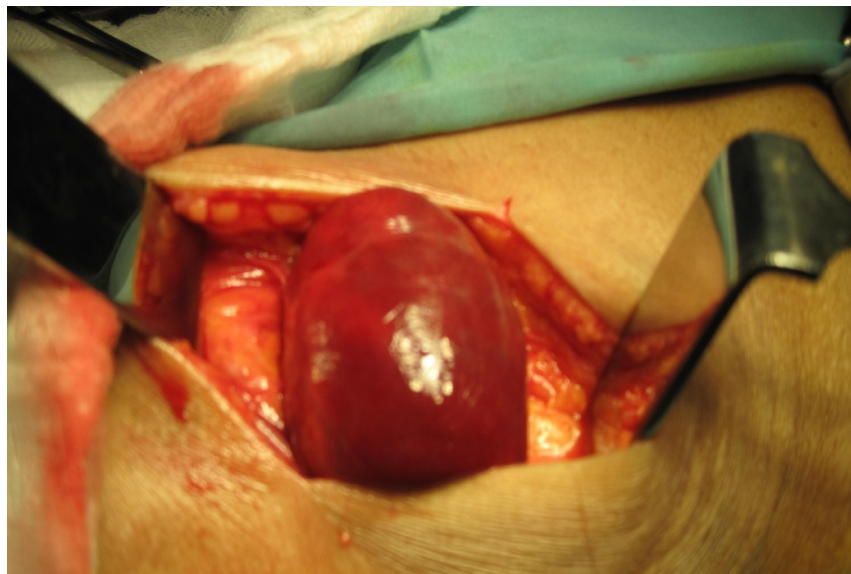

Figure 5: Intraoperative photograph showing defect and protruding hernia sac.

This patient was considered by the anesthetist to be of high risk due to her advanced age and associated co morbidities. The surgical repair was done under sedation and local anesthesia. The operative findings were of herniated sac through the defect in-between muscles of the right superior lumbar triangle. The sac was filled with thick oedematous, but viable, perinephric fat. She underwent repair (Dowd-Ponka repair) as follow, after the sac had been closed with purse string sutures, a prolene mesh patch was laid over the defect and sutured to the external oblique, latissimus dorsi muscles and lumbar periosteum using 3/0 nylon. Finally these muscles were approximated over the mesh. She recovered well with no detected post-operative complications.

Discussion

The lumbar region is an area defined superiorly by the 12th rib, inferiorly by the iliac crest, medially by the erector spinae muscle group, and laterally by the posterior border of the external oblique muscle as it extends from the 12th rib to the iliac crest. This area encompasses two anatomical triangles, which form the commoner sites for lumbar hernias. The inferior lumbar (Petit's) triangle is bounded by the posterior free margin of the external oblique muscle in front, the Latissimus dorsi behind and the iliac crest below. The floor is formed by the internal oblique muscle and the lumbar fascia. The superior lumbar (Grynfeyt-Lesshaft's) triangle is bounded above by the 12th rib and the sacrospinalis muscle, behind by the erector spinae group and in front by the internal oblique. The Latissimus dorsi forms the roof of the triangle ¹.

Lumbar hernia is the protrusion of intraperitoneal or extraperitoneal contents through a defect of the posterolateral abdominal wall. The inferior and superior lumbar triangles account for about 95 per cent of lumbar hernias. Approximately 20 per cent of lumbar hernias are congenital. The rest are either primarily or secondarily acquired. The most common cause of primarily acquired lumbar hernias is increased intra-abdominal pressure. Secondarily acquired lumbar hernias are associated with prior surgical incisions, trauma, and abscess formation².

Lumbar hernia is rare, with fewer than 300 cases reported in the literature³. The most common symptom of lumbar hernia is a protruding lump in the flank, its size increases with activity, and it disappears when lying down. The patient may complain of a vague sense of discomfort, abdominal pain, and local tenderness. Bowel obstruction occurs in 25% and there is about a 10% chance of strangulation. In these cases, the patient manifests with nausea, vomiting, abdominal pain and distension⁴.

Lumbar hernias can be diagnosed by clinical symptomatology and physical examination. In many cases, the differential diagnosis of lumbar hernias includes a lipoma, sarcoma, abscess, hematoma or renal tumor⁵. As the diagnosis is usually difficult to confirm by purely clinical means, imaging modalities become necessary. A small and large bowel barium study has been recommended to determine which portion of the bowel, if any occupies the hernia. In addition an IVU may be performed to visualize any displacement of the kidney or ureter into the hernia. However, recent reports suggest that an abdominal CT scan is probably the most valuable imaging modality. A CT scan can accurately distinguish the muscular and fascial layers, detect the presence of a defect in these layers, visualize herniated fat or viscera and differentiate a hernia from a hematoma, abscess or soft-tissue tumor^{6,7}. USG has also been reported to be useful in imaging a lumbar hernia⁸.

Incarceration is reported at a high rate for lumbar hernias in the range of 25% ⁹. Multiple organs have been reported to herniate through lumbar hernias in addition to small intestine, including colon¹⁰ and segments of the liver¹¹. Consequently, Repair of lumbar hernias should

be performed as early as possible to avoid incarceration and strangulation. The classic repair technique uses the open approach, where closure of the defect is performed primarily by using prosthetic mesh. The laparoscopic approach, either transabdominal or extraperitoneal, is an alternative ¹². Both open and laparoscopic techniques can be used with good results ¹³. The open approach was used in this patient due to our limited experience in such cases and the patient condition which did not permit general anesthesia

Conclusions

Lumbar hernias are rare cases. Knowledge of lumbar hernia is important to avoid misdiagnosis and any lumbar or flank mass should always raise suspicion of a lumbar hernia. CT is the gold standard for diagnosis. Because of its high rate of incarceration, appropriate planned surgical treatment should be done rapidly.

References

1. Swartz WT. Lumbar hernia. In: Nyhus LM, Condon RE, editors. *Hernia*. 2nd ed. Philadelphia: Lippincott; 1978:409-426.
2. Stamatioui D, Skandalakis JE, Skandalakis LJ, Mirilas P. Lumbar hernia: Surgical anatomy, embryology, and technique of repair. *Am Surg*. 2009; 75:202-7.
3. Ponka JL (1980) Lumbar Hernias, in: Ponka JL (ed) *Hernias of the abdominal wall*. WB Saunders, Philadelphia, pp 465-478
4. Hide IG, Pike EE, and Uberoi R. Lumbar hernia: a rare cause of large bowel obstruction. *Postgrad Med J*.1999; 75:231-232.
5. Moreno-Egea A, Baena EG, Calle MC, Martínez JA, Albasini JL. Controversies in the current management of lumbar hernias. *Arch Surg*. 2007; 142:82-88.
6. Faro SH, Racette CD, Lally JF. Traumatic Lumbar Hernia CT Diagnosis *AJR* 1990; 154:757-759
7. Baker ME, Weinerth JL, Andriani RT. Lumbar Hernia Diagnosis by CT. *AJR* 1987; 148:565-567
8. Siffring PA, Forrest TS, Frick MP. Hernias of the Inferior Lumbar Space. *Diagnosis with US*. *Radiology* 1989; 170:190.
9. Hide IG, Pike EE, Uberoi R. Lumbar Hernia: a rare cause of large bowl obstruction. *Postgrad Med J*.1999; 75:231-32.
10. Astarcioglu H, Sokmen S, Atila K, Karademir S. Incarcerated inferior lumbar (Petit's) hernia. *Hernia*.2003; 7:158-60.
11. Salemis NS, Nisotakis k, Gourgiotis S, Tsohataridis E. Segmental liver incarceration through a recurrent incisional lumbar hernia. *Hepatobiliary Pancreat Dis Int*. 2007; 6:442-44.
12. Sakarya A, Aydede H, and Erhan MY, et al. Laparoscopic repair of acquired lumbar hernia. *Surg Endosc*.2003; 17:1494.
13. Cavallaro G, Sadighi A, Miceli M, Burza A, Carbone G, Cavallaro A: Primary lumbar hernia repair: the open approach. *Eur Surg Res* 2007, 39(2):88-92