

## Case Report

# Lymphocytic Mastitis Mimicking Breast Carcinoma, Radiology and Pathology Correlation: Review of Two Cases

Sharifah Majedah Idrus ALHABSHI<sup>1,2</sup>, Kartini RAHMAT<sup>2</sup>, Caroline Judy WESTERHOUT<sup>2</sup>, Nani Harlina Md LATAR<sup>3</sup>, Patricia Ann CHANDRAN<sup>4</sup>, Suraya AZIZ<sup>1</sup>

Submitted: 30 Jul 2012

Accepted: 20 Oct 2012

<sup>1</sup> Department of Radiology, Faculty of Medicine, Universiti Kebangsaan Malaysia Medical Centre, Jalan Yaacob Latif, Bandar Tun Razak, 56000 Cheras, Kuala Lumpur, Malaysia

<sup>2</sup> Department of Biomedical Imaging, University Malaya Research Imaging Centre (UMRIC), Universiti Malaya, Lembah Pantai, 59100 Kuala Lumpur, Malaysia

<sup>3</sup> Department of Surgery, Faculty of Medicine, Universiti Kebangsaan Malaysia Medical Centre, Jalan Yaacob Latif, Bandar Tun Razak, 56000 Cheras, Kuala Lumpur, Malaysia

<sup>4</sup> Department Pathology, University Malaya Research Imaging Centre (UMRIC), Universiti Malaya, Lembah Pantai 59100, Kuala Lumpur, Malaysia

## Abstract

Lymphocytic mastitis, or diabetic mastopathy, is an unusual finding in early-onset and long-standing diabetes. It can presents as a non-tender or tender palpable breast mass. Mammogram and ultrasound frequently demonstrate findings suspicious of malignancy, thus biopsy and histological confirmation is usually required. We reviewed two cases of lymphocytic mastitis with characteristics findings on mammogram, ultrasound, and histopathology. Diagnoses were confirmed with excision biopsy.

**Keywords:** breast, breast carcinoma, inflammatory breast neoplasm, mastitis

## Introduction

Lymphocytic mastitis, or diabetic mastopathy, is an unusual finding in patients with early-onset or long-standing diabetes mellitus (1). Lymphocytic mastitis usually presents as a palpable mass with radiological findings highly suggestive of breast carcinoma (2). We present two cases of lymphocytic mastitis, emphasizing mammogram and ultrasound findings, and correlation with histopathology.

## Case 1

A 37-year-old obese, nulliparous woman with no family history of breast carcinoma presented with a painful left breast lump for one month. She had been recently diagnosed with diabetes mellitus. There was no history of fever. On examination, there was a vague firm and tender

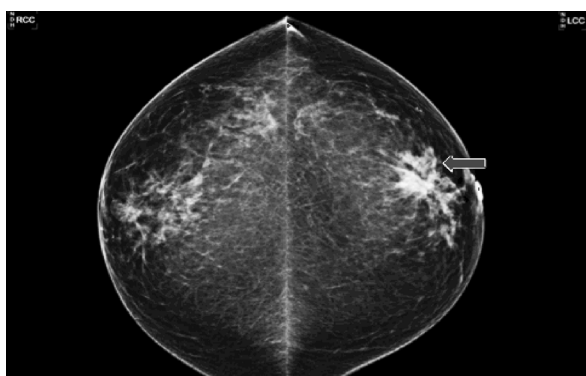
mass at the three o'clock position in the left breast. Mammogram showed a spiculated mass at the left retro-areolar region. There was no suspicious microcalcification (Figure 1). Ultrasound revealed an irregular hypoechoic lesion measuring 3.5 × 4 cm, with marked posterior acoustic shadowing, at the retro-areolar 12 o'clock position (Figure 2). There was no axillary lymphadenopathy bilaterally. The lesion was categorized as BIRADS 5 which was highly suspicious of malignancy according to The American College of Radiology (ACR) Breast Imaging Reporting and Data System. Ultrasound guided core biopsy was performed, and histopathology examination showed breast tissue with dense keloid-like fibrosis and periductal, perilobular, and perivascular lymphocytic infiltration. There was epithelioid fibroblast seen in the stroma. There was no hyperplasia and no malignant cells seen (Figure 3). Histopathology findings were consistent

with sclerosing lymphocytic mastitis. In view of conflicting clinical, imaging, and pathology findings, hookwire localization and wide local excision were performed, and histopathology confirmed the diagnosis of lymphocytic mastitis. One year post-surgery, ultrasound, and mammogram showed no evidence of recurrence.

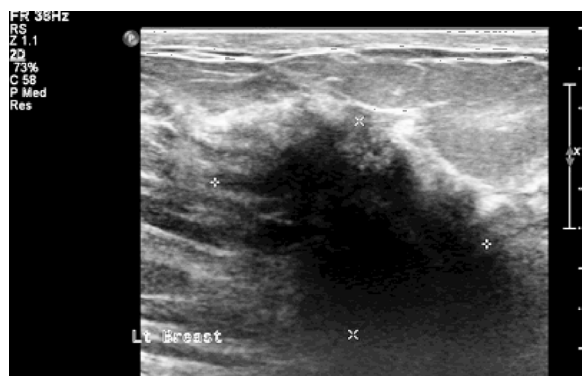## Case 2

A 65-year-old woman who was asymptomatic came for a screening mammogram. She was a known case of poorly controlled diabetes for 20 years. Mammogram showed two ill-defined, high-

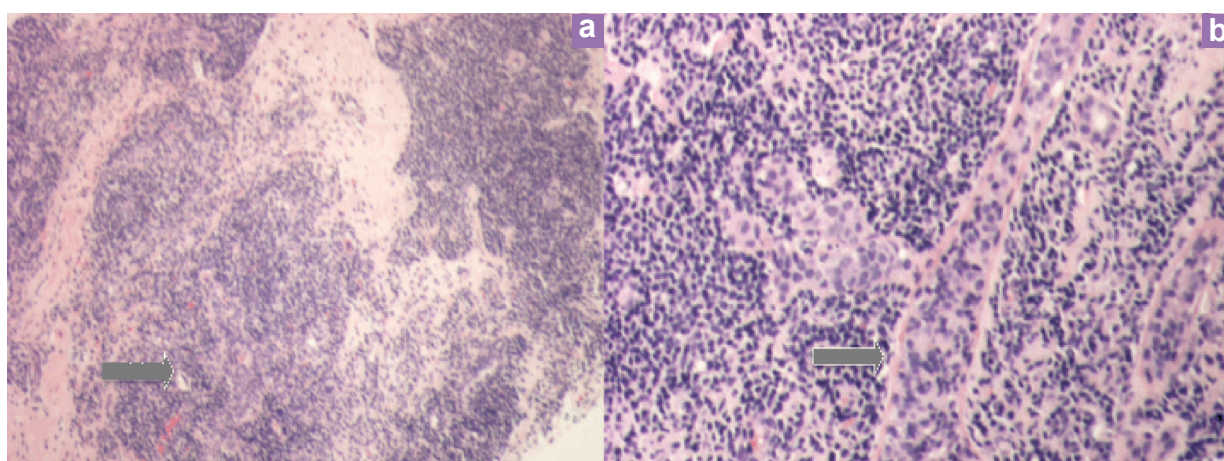
density masses at the right mid-quadrant, with underlying moderately dense breast (Figure 4). Ultrasound revealed two irregular, hypoechoic lesions with strong posterior acoustic shadowing in the same quadrant (Figure 5). There was no enlarged axillary node bilaterally. The lesions were classified as BIRADS 5, which was suspicious of malignancy. Ultrasound-guided core biopsy was repeated twice, in view of discordant results. Histopathology confirmed lymphocytic mastitis. The patient underwent hookwire localization and excision biopsy. Six-month follow up post-excision biopsy was normal, with no evidence of recurrence of disease.



**Figure 1:** Case 1, a 37-year-old woman presented with painful palpable left breast lump. Left mammogram craniocaudal (CC) view showed left retro-areolar high density spiculated lesion (arrow).



**Figure 2:** Case 1, a 37-year-old woman with painful left breast lump. Ultrasound showed irregular hypoechoic lesion with strong posterior acoustic shadow at 12 o'clock retro-areolar position.



**Figure 3:** Case 1, a 35-year-old woman with painful left breast lump. Histopathology section (a) (4× magnification). (b) (10× magnification) showing dense lymphocytic infiltration around breast ducts (arrows).

## Discussion

The majority of lymphocytic mastitis and diabetic mastopathy patients are diabetic (2); both of our patients were diabetics. The first case was newly diagnosed diabetes, and the second case was a known case of poorly controlled diabetes for 20 years.

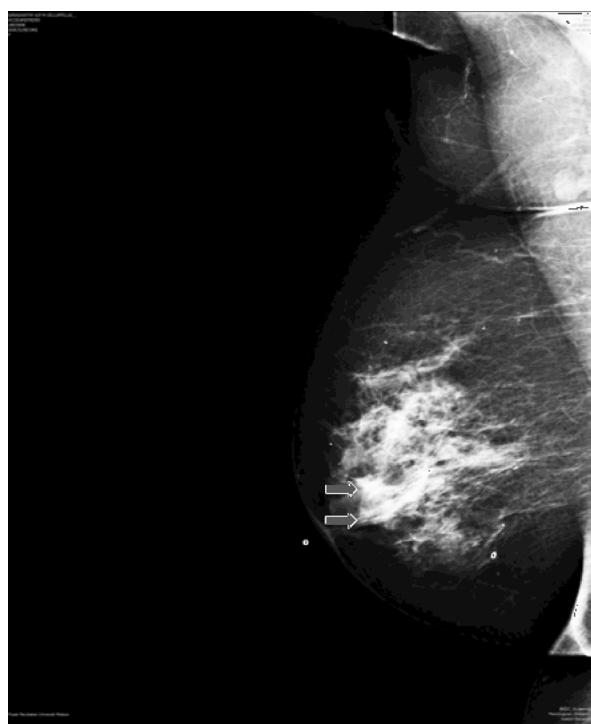Lymphocytic mastitis can present as a palpable mass and mimic breast cancer on physical examination (2). Our first patient had a painful, palpable lump; however, the second patient's lump was painless. Both masses were suspicious for carcinoma by physical examination, ultrasound evaluation, and mammogram.

Multicentric or bilateral involvement has been reported, and it occurs often in the late stages of the disease (3). Both of our patients showed unilateral mass; however, the second case showed multifocality in the same quadrant of the breast. Masses also may appear in a wide range

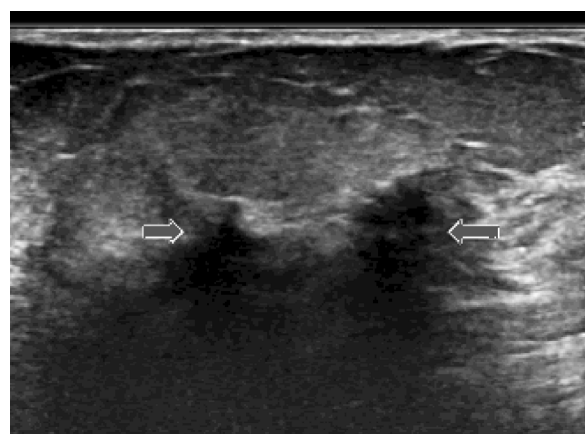
of sizes. They can be palpable or only detected radiologically. They can occur in any breast quadrant, although they do have a propensity to develop in the retro-areolar region (4).

Mammography has not generally been very sensitive in detecting these lesions, because dense breast tissue can obscure an underlying lesion. Mammograms in our two patients showed high-density, vague, irregular masses with underlying dense glandular tissue, consistent with the previous reported case (4).

Ultrasound is the most useful adjunctive tool in evaluating a palpable mass in a patient suspected of having diabetic mastopathy (2). Ultrasound evaluations of these lesions usually have demonstrated irregular, hypoechoic masses with moderate to marked acoustic shadowing (4). Both of our patients showed irregular, hypoechoic lesions with moderate to marked posterior acoustic shadowing. The amount of posterior acoustic shadowing is usually very marked, and



**Figure 4:** Case 2, a 65-year-old woman who was asymptomatic with 20 years history of diabetes. Mammogram medio lateral oblique view (MLO) showed two ill defined high density masses at the right mid quadrant (arrows) in the background of moderately dense breast.



**Figure 5:** Case 2, a 65-year-old woman who was asymptomatic with 20 years history of diabetes. Ultrasound showed two irregular hypoechoic lesions with strong posterior acoustic shadow in the same quadrant and histopathology confirmed lymphocytic mastitis (arrows).



greater than in breast carcinomas. The ultrasound findings in our series did not correlate with the duration of diabetes mellitus, the use of insulin, or any specific histology feature.

Shaffrey et al. (5) compared the breast biopsy results of breast masses in patients with long-term, insulin-dependent diabetes with those of non-diabetic patients with fibrosis and chronic mastitis. The biopsy results of patients with long-term, insulin-dependent diabetes showed lymphocytic lobulitis and ductitis, lymphocytic vasculitis, dense keloid-like fibrosis, and epithelioid fibroblasts (6). All of the pathology findings were apparent in the non-diabetic or short-term diabetes patients, except for epithelioid fibroblasts. In their study, epithelioid cells were felt to be the key distinguishing factor; epithelioid fibroblasts have rarely been reported in non-diabetic patients with lymphocytic mastitis (2).

Differential diagnosis of lymphocytic mastitis or diabetic mastopathy included granulomatous mastitis, fibrotic tissue, and breast carcinoma (7,8). In view of suspicious clinical and radiological findings, tissue diagnosis was mandatory. Fine-needle aspiration cytology (FNAC) is usually inadequate, and core biopsy or excisional biopsy is required for confirmatory diagnosis.

Free-hand FNA cytology analysis alone usually does not help, as it is difficult to perform, due to the firmness of the masses (3). Although surgical excision has been usually performed in the past to exclude malignancy, core biopsy is currently accepted as adequate for diagnosis. In fact, core biopsy is a reliable method for establishing the diagnosis in the proper clinical setting, and it can eliminate the need for more aggressive procedures, such as surgical biopsy. However, due to conflicting results between histological findings and radiological and clinical findings, both of our patients were subjected to excision biopsy for confirmatory diagnosis.

The recurrence rate is relatively high, 32%, and there is no evidence to support development of breast cancer from diabetic fibrous mastopathy (3).

## Conclusion

Lymphocytic mastitis, or diabetic mastopathy, is an uncommon entity that can mimic breast carcinoma clinically and radiologically. We should be aware that these lesions are usually firm to hard on palpation and can be single, multiple, and bilateral. There is usually history of diabetes;

however, it can also occur in non-diabetic patients. Mammography is necessary, but is usually not of diagnostic value. Ultrasound is very useful as an adjunctive imaging tool, as well as for image-guided biopsy. Given the presence of extensive fibrosis, core biopsy often provides conflicting results, and excision biopsy may be necessary for a definitive diagnosis.

## Acknowledgement

None.

## Conflict of interest

None.

## Funds

The preparation of this article was made possible by the financial support of Universiti Malaya Research Grant (RG390/11HTM).

## Authors' Contributions

Critical revision of the article for the important intellectual content, final approval of the article, provision of study materials or patient, obtaining of funding, and administrative, technical or logistic support: KR

Conception and design, analysis and interpretation of the data and drafting of the article: SMIA

Provision of study materials or patient and collection and assembly of data: CJ, NHML, PAC  
Conception and design, critical revision of the article for the important intellectual content: SA

## Correspondence

Dr Sharifah Majedah Idrus Alhabshi  
MD (UKM), MMed Radiology (UKM), Fellowship of Breast Imaging (UM)  
Department of Radiology  
Universiti Kebangsaan Malaysia Medical Centre  
Jalan Yaacob Latif, Bandar Tun Razak  
56000 Cheras  
Kuala Lumpur, Malaysia  
Tel: +603-9145 5555  
Fax : +603-9145 6682  
Email: shmajedah@yahoo.com

## References

1. Kudva YC, Reynolds C, O'Brien T, Powell C, Oberg AL, Crotty TB. "Diabetic mastopathy," or sclerosing lymphocytic lobulitis, is strongly associated with type 1 diabetes. *Diabetes Care*. 2002;**25**(1):121-126.

2. Andrews-Tang DA, Diamond AB, Rogers L, Butler D. Diabetic mastopathy: adjunctive use of ultrasound and utility of core biopsy in diagnosis. *Breast J.* 2000;**6**(3):183–188.
3. Bayer U, Horn LC, Schulz HG. Bilateral, tumorlike diabetic mastopathy-progression and regression of the disease during 5-year follow up. *Eur J Radiol.* 1998;**26**(3):248–253.
4. Williams PH, Rubin CM, Theaker JM. Sclerosing lymphocytic lobulitis of the breast. *Clin Radiol.* 1995;**50**(3):165–167.
5. Shaffrey JK, Askin FB, Gatewood OMB, Brem R. Diabetic fibrous mastopathy: case reports and radiologic–pathologic correlation. *Breast J.* 2000;**6**(6):414–417.
6. Sabate JM, Clotet M, Gomez A, De Las Heras PD, Torrubia S, Salinas T. Radiologic evaluation of uncommon inflammatory and reactive breast disorders. *Radiographics.* 2005;**25**(2):411–424.
7. Boufettal H, Essodegui F, Noun M, Hermas S, Samouh N. Idiopathic granulomatous mastitis: a report of twenty cases. *Diagn Interv Imaging.* 2012;**93**(7–8):586–596.
8. Boufettal H, Mahdaoui S, Noun M, Hermas S, Samouh N, Benayad S, et al. Idiopathic granulomatous mastitis with favorable outcome with medical treatment. *Rev Med Interne.* 2011;**32**(2):26–28.