

A Rare Case of Large Nasal Teratoma Associated with Congenital Heart Anomalies in a Neonate

Kamrani, Kamyar, MD; Tabatabaiepoor,
Seedebrahim*, MD; Hajarolasvadi, Nazanin , MD

Department of Pediatrics, Tehran University of Medical
Sciences, Bahrami Children's Hospital, Tehran, Iran

Received: Jun 20, 2012; Accepted: Nov 19, 2012; First Online Available:

Dec 02, 2012

Sacrocoxygeal teratomas are the most common teratomas, while head and neck cases are extremely rare^[1,2]. The approximately reported incidence of teratoma is 1 in 35000 to 40000 live-births^[3,4]. Although they are generally more common in females, no gender preference is reported in head and neck ones^[2].

It is thought that teratoma originates from those multi-potential germinal cells which are lost during a migration from yolk sac endodermal layer adjacent to allantois to gonadal edge in fourth and fifth gestational week^[5]. The mentioned cells then can be arisen as teratoma somewhere from brain to coccyx, often in the midline^[1,5,6].

A full-term female infant, gestational age of 40 weeks, was born via cesarian section to a 24 year old primigravida. The mother had history of hypertension and limb edema at 36th week of pregnancy in which abdomino-pelvic ultrasound examination revealed a fetus facial mass and congenital heart anomaly in addition to polyhydramnios. The infant's birth weight was 3530g and the Apgar scores were nine and ten at 1 and 5 minutes respectively. Evaluation of the infant in nursery room revealed a mid-facial mass in shape of beak protruding about 10 cm with a base extending to forehead at the top and to palate at the bottom where it made nasal trills to deviate aside (Fig. 1). She was then referred to our hospital regarding her congenital heart anomaly and mild respiratory distress. On admission, she was in a subtle respiratory distress for which the diagnosis of an upper

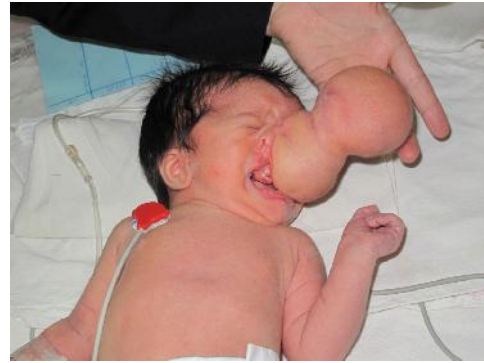

Fig. 1: Infant with nasal teratoma

respiratory tract obstruction due to mass was made. Subsequently fixation of the mass not only relieved the respiratory distress, it also surprisingly made her free of supplemental oxygen.

Further examination of the mass with Ultrasound and MRI showed a mass with homogenous hyper-echogenicity (density resembling fat tissue) all over except in central part in which cystic areas with different echogenicity and hypo-echogenicity (most presumably bony structure) were detected. MRI scan by a 1.5T device showed a large soft tissue mass in anterior part of the face in midline originating in ethmoid sinuses and posterior aspect of the nasal fossa with a midline defect in palate, mostly showing T1 T2 high signal in favor of fat with tubular T1 T2 low signal region which could be due to bone and also a small central cystic component (Fig. 2). No definite connection with the meninges or brain was noted.

Severe tricuspid atresia, atrial septal defect,

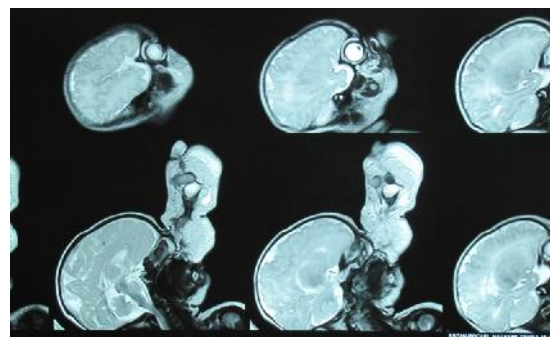


Fig. 2: Infant MRI (highsignal fat component with central cystic part)

* Corresponding Author; Address: Bahrami Hospital, Damavand St., Tehran, Iran
E-mail: tabamohamad42@yahoo.com

ventricular septal defect and pulmonary stenosis were detected during Echocardiographic assessment.

After essential evaluation and preparation, the patient underwent surgery and a large mid-facial protrusion was resected. Pathology reported neoplastic tissue consisting of heterologous elements such as skin and its appendages, glandular structure, cartilage, marrow elements and bone with no evidence of neuroepithelial elements compatible with mature teratoma.

Nasal masses could be due to glioma, meningoencephalocele, encephalocele, congenital rhabdomyosarcoma, and lymphatic malformations^[5,6]. Tumor arising from hard and soft palate and Rathke's pouch are called epignathus teratomas.

Sometimes a fetus bearing teratoma is unable to swallow amniotic fluid due to its mass effect, thus polyhydramnios may be detected at about 15% of pregnant women^[1].

The main treatment of teratoma is Surgery. The overall long term prognosis is excellent and relapses take place rarely. Despite benign nature of teratomas, routine follow-up is necessary in all cases^[5]. In our patient in 1 year follow-up, no recurrence occurred and alfa fetoprotein (AFP) levels reduced after tumor resection.

Key words: Teratoma; Congenital Heart Anomaly; Neonate

References

1. Holcomb GW, Murphy PJ. Ashcraft's Pediatric Surgery, 5th Ed. Philadelphia: Saunders Elsevier 2010; Pp: 915-35.
2. Ibekwe TS, Kokong DD, Ngwu BA, et al. Nasal septal teratoma in a child. *World J Surg Oncol* 2007;5:58.
3. Mcintosh N, Helms PJ, Smyth RL. Forfar and Arneil's Textbook of Pediatrics, 7th ed. Edinburgh: Churchill Livingstone 2008; Pp: 1010-28.
4. Benson RE, Fabbroni G, Russell JL. A large teratoma of the hard palate: a case report. *Br J Oral Maxillofac Surg* 2009;47(1):46-9.
5. Sreetharan SS, Prepageran N. Benign teratoma of the nasal cavity. *Med J Malaysia* 2004;59(5):678-9.
6. Makki FM, Al-Mazrou KA. Nasopharyngeal teratoma associated with cleft palate in a

newborn. *Eur Arch Otorhinolaryngol* 2008; 265(11):1413-5.

Midgut Volvulus Caused by Mesenteric Lipoma

Rezvanizadeh, Alireza¹, MD; Sadaghiani, Mohammad S.^{1,*}, MD; Mehdizadeh, Mehrzad², MD; Alizadeh, Houman², MD

1. Department of Radiology, Imam Khomeini Hospital, Tehran University of Medical sciences, Tehran, Iran
2. Radiology Division, Children's Medical Center, Tehran University of Medical sciences, Tehran, Iran

Received: May 30, 2011; Accepted: Dec 16, 2011;
First Online Available: Jan 09, 2013

Lipoma is a benign neoplasm of adipose tissue. In children it rarely rises in mesentery or gastrointestinal tract and the secondary midgut volvulus caused by lipoma is very rare^[1,2]. Herein, we report a 6-year-old girl with small bowel lipoma causing midgut volvulus.

The patient presented to emergency ward with a 2-day history of moderate central abdominal pain, colicky in nature accompanied with nausea and vomiting. No mass was touched on palpation. Routine blood tests showed normal white cell count, urea, creatinine, amylase and electrolytes. Plain abdominal X-ray showed a gasless pelvis and lower abdomen, but laterally deviated and dilated intestinal loops. Abdominal ultrasonography revealed a loose ill-defined lobulated mass quite isoechoic with mesenteric fat in right lower abdomen displacing the echogenic small bowel loops gas. Computed tomography revealed a well-capsulated, homogeneous mass with negative HU about lipid density, 13×3×5 cm in size, filling the right portion of the inferior abdomen and pelvis, deviating the intestinal loops (Fig. 1). Volvulus of midgut by twisted (about 360° clockwise) appearance of the main mesenteric vessels in their root was depicted (Fig. 2). The diagnosis of volvulus was confirmed in color Doppler ultrasonography, where superior mesenteric vein was observed to lie in the left side of superior mesenteric artery. At laparotomy, after detorsion, a mesenteric lipoma was identified in

* Corresponding Author; Address: Department of Radiology, Imam Khomeini Hospital, KeshavRZ Blvd, Tehran, Iran
E-mail: tabamohamad42@yahoo.com