

Alexander Disease: Report of Two Unrelated Infantile Form Cases, Identified by GFAP Mutation Analysis and Review of Literature; The First Report from Iran

Mahmoud-Reza Ashrafi^{1,2,3}, MD; Alireza Tavasoli^{2,3*}, MD; Omid Aryani⁴, MD; Hooman Alizadeh^{3,5}, MD; Massoud Houshmand^{4,6}, PhD

1. Department of Pediatrics, Tehran University of Medical Sciences, Tehran, Iran
2. Growth and Development Research Center, Tehran University of Medical Sciences, Tehran, Iran
3. Children's Medical Center, Pediatric Center of Excellence, Tehran, Iran
4. Department of Medical Genetics, Special Medical Center, Tehran, Iran
5. Department of Radiology, Tehran University of Medical Sciences, Tehran, Iran
6. Genetic Department, National Institute for Genetic Engineering and Biotechnology, Tehran, Iran

Received: May 13, 2012; Accepted: Jan 19, 2013; First Online Available: Jul 18, 2013

Abstract

Background: Alexander disease (AD) is a sporadic leukodystrophy that predominantly affects infants and children and usually results in death within ten years after onset. The infantile form comprises the most of affected individuals. It presents in the first two years of life, typically with progressive psychomotor retardation with loss of developmental milestones, megalencephaly and frontal bossing, seizures, pyramidal signs and ataxia. The diagnosis is based on magnetic resonance imaging (MRI) findings and confirmed by *GFAP* gene molecular testing. *GFAP* gene encodes glial fibrillary acidic protein, is the only gene in which mutation is currently known to cause AD which is inherited in autosomal dominant manner.

Case Presentation: In this article we report the first two Iranian cases of infantile AD and their clinical, brain MRI and molecular findings. We report two novel mutations too in the *GFAP* gene that are associated with infantile form of AD.

Conclusion: *GFAP* gene mutations are a reliable marker for infantile AD diagnosed according to clinical and MRI defined criteria. A genotype-phenotype correlation had been discerned for the two most frequently reported *GFAP* gene mutations in infantile type of AD (R79 and R239), with the phenotype of the R79 mutations appearing much less severe than that of the R239 mutations. Our findings confirm this theory.

Iranian Journal of Pediatrics, Volume 23 (Number 4), August 2013, Pages: 481-484

Key Words: Alexander Disease; Leukoencephalopathy; Alexander's leukodystrophy; Megalencephaly; Macrocephaly

Introduction

Alexander disease (AD) is a sporadic leukodystrophy that predominantly affects infants and children and usually results in death within ten years after onset. It was first described by Stewart Alexander in 1949 as a "progressive degeneration of fibrillary astrocytes"^[1-3]. AD is

characterized by progressive failure of central myelination and the accumulation of Rosenthal fibers in astrocytes and on magnetic resonance imaging (MRI) by leukodystrophy. According to the age of clinical presentations, it can be divided into three subtypes: infantile (between birth and 2 years of age), juvenile (between 2 and 12 years of age) and adult (from the second to seventh

* Corresponding Author;

Address: Division of Pediatric Neurology, Children's Medical Center, No 62, Dr Gharib St., Tehran, Iran
E-mail: dralit73@yahoo.com

© 2012 by Pediatrics Center of Excellence, Children's Medical Center, Tehran University of Medical Sciences, All rights reserved.

decade)^[4,5]. The infantile form comprises most affected individuals (about 63% of reported cases). It presents in the first two years of life, typically with progressive psychomotor retardation with loss of developmental milestones, megalencephaly and frontal bossing, seizures, pyramidal signs and ataxia. The diagnosis is based on MRI findings and confirmed by *GFAP* gene molecular testing. *GFAP* gene encodes glial fibrillary acidic protein, is the only gene in which mutation is currently known to cause AD which is inherited in autosomal dominant manner. In this article we report the first two Iranian cases of infantile AD and their clinical, brain MRI and molecular findings. We report two novel mutations too in the *GFAP* gene that are associated with infantile form of AD. The first genetically proved cases of AD were reported by Brenner's group in 2001^[6]. Nearly all cases of AD are associated with heterozygous point mutation of the Glial Fibrillary Acidic Protein (*GFAP*) gene located on chromosome 17q21, but missense and de novo mutations also have been found^[3,6,7].

Case Presentation

Case 1: A 15 month-old boy was referred to our hospital for evaluation of seizure disorder and

developmental regression. He was the second child of non-consanguineous parents, born at term by elective cesarean section after an uneventful pregnancy. His birth weight and head circumference (HC) were 3.1Kg and 34cm, respectively. Family history was unremarkable. He attained head holding at 7 months of age. Visual fixation and following were not good. First episode of seizure occurred with fever at the age of 5 months. The second episode of seizure occurred without fever at the age of 7 months, and then developmental regression started. Macrocephaly (HC 51 cm), generalized spasticity and searching nystagmus were the main neurological findings. Metabolic tests including High performance liquid chromatography (HPLC) of serum aminoacids, urine organic acid profile, serum ammonia and lactate level and thyroid function tests were within normal limit. Brain MRI showed four of the five diagnostic criteria of Alexander disease described by van der Knapp et al in 2001^[1,8] (Fig 1).

The diagnosis of AD was confirmed by genetic analysis, which revealed a heterozygous mutation of p.Arg239His in the exon 4 of *GFAP* gene.

Case 2: A 5.5 year-old boy was referred to our hospital for evaluation of developmental regression and seizures. He was the third child of healthy and consanguineous parents, born at term by elective cesarean section after an uneventful

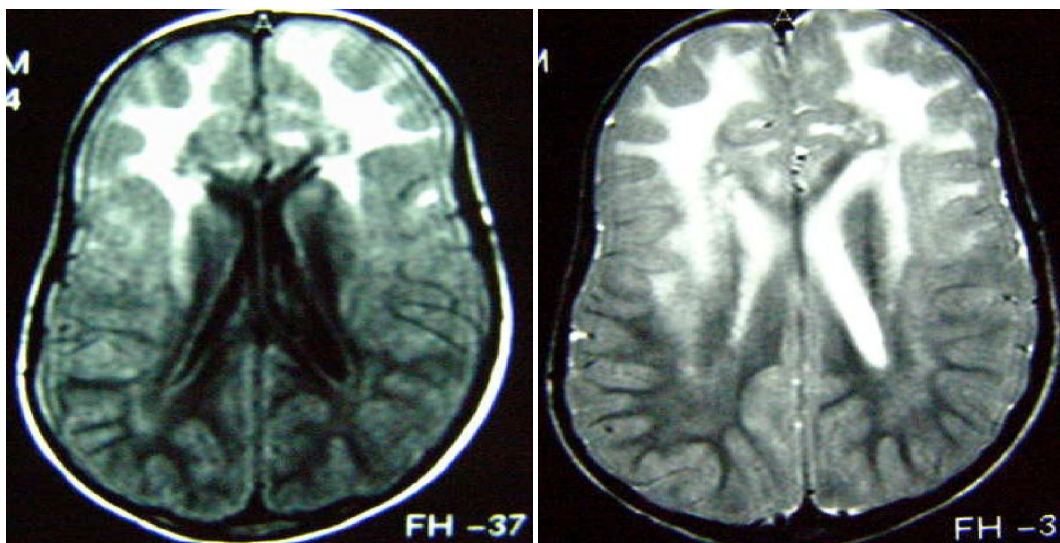


Fig. 1: Axial T1 and T2-weighted MRI images of case-one, showing a periventricular rim (hyper intense in T1 and hypo intense in T2) and predominant frontal white matter involvement with subependymal cysts

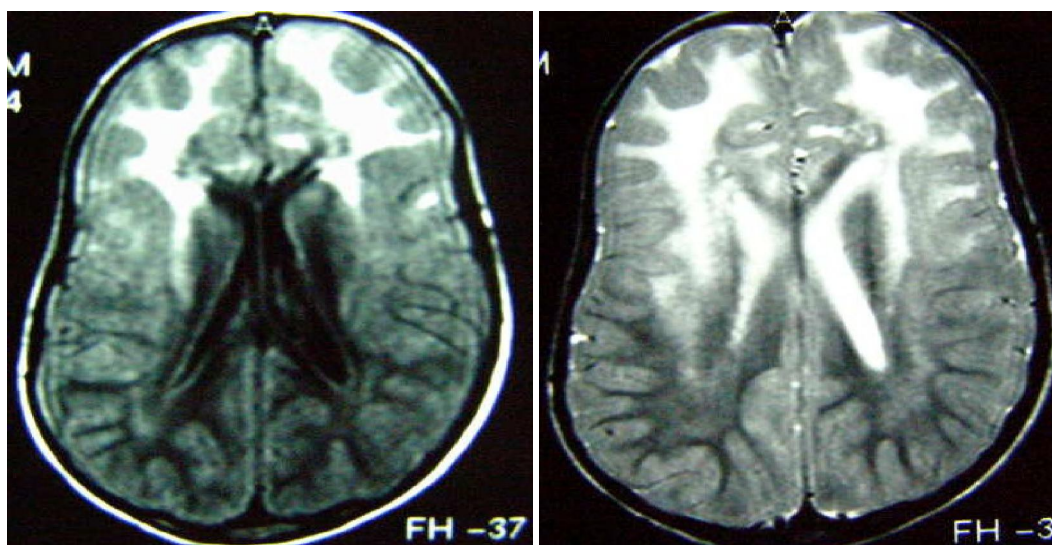


Fig. 2: Axial T1 and T2-weighted MRI images of case-two, showing a periventricular rim (hyper intense in T1 and hypo intense in T2) and predominant frontal white matter involvement

pregnancy. His birth weight was 3 Kg, HC at birth was not determined. Family history was unremarkable. At the age of 6 months he had developmental delay and was not able to partial weight bearing. Following the DPT vaccination seizures started and thereafter developmental regression occurred. Significant findings in physical examination were macrocephaly (HC 51cm) and spasticity. Laboratory tests similar to the first patient, were all within normal limit. As in case 1, brain MRI showed four of the five diagnostic criteria of AD described by van der Knapp et al in year 2001 (Fi. 2). Genetic study revealed a heterozygous mutation of p.Arg79His in the exon 1 of *GFAP* gene.

According to the age of onset our two cases were the infantile type. MRI findings were compatible with four of the five criteria of van der Knapp et al (2001)^[4,8] for the diagnosis of AD. Based on following criteria, AD diagnosis in our patients was wstablished.

1. Periventricular rim (high signal on T1 and low signal on T2-weighted images).
2. Extensive white matter abnormalities predominantly of frontal lobe and cystic degeneration of anterior deep periventricular white matter (Figs 1 and 2).
3. Abnormalities of the basal ganglia and thalami.
4. Brain stem abnormalities especially involving the mid brain area.

Discussion

Prior to availability of the molecular genetic analysis of AD, only genetic demonstration of Rosenthal fibers in astrocytes of brain specimen was able to confirm the studies^[3,8]. We used *GFAP* gene mutation analysis for confirmation of our clinical diagnosis. Genetic tests revealed heterozygous mutation in exons 4 and 1 of *GFAP* gene. In two large studies on the infantile type of AD by Brenner et al, 2007 and Rodriguez et al, 2001^[7] (collectively 28 patients), *GFAP* mutations were detected in 93% of patients by amplification of only exons 1, 4, and 8.

In our patients the detected mutations were also in exons 1 and 4 and carried arginine mutations (p.Arg239His and p.Arg79His)(Table 1). Both the p.Arg239His and p.Arg79His coding changes have been previously associated with AD patients. The p.Arg79His mutation is considered causative for AxD due to its *de novo* appearance, whereas the role of p.Glu223Gln is unclear^[6]. To date, of the 72 different mutations that have been identified, 68 are missense mutations and mutations at three amino acid residues (Arg79, Arg88, and Arg239) account for 42% (80/189) of all molecularly confirmed cases. In two before mentioned studies a genotype-phenotype correlation had been discerned for the two most frequently mutated arginine residues (R79 and

Table 1: Clinical features and *GFAP* mutations of patients

Patient	Degradation	HC	Exon	Nucleotide change	Amino acid change	Status
1	7mo	51	4	716G>A	p.Arg239His	Alive
2	6mo	51	1	236G>A	p.Arg79His	Alive

R239), with the phenotype of the R79 mutations appearing much less severe than that of the R239 mutations^[6,7]. The number of patients in our study for this analysis is not enough. It seems that further studies are needed to confirm the theory proposed by two previous large studies^[6,7].

Conclusion

It seems that further studies are needed to confirm the theory proposed by two previous large studies. In conclusion, *GFAP* gene mutations are a reliable marker for infantile AD diagnosed according to clinical and MRI defined criteria. Also it is a strong rationale for the analysis of the *GFAP* gene, even in the absence of macrocephaly or neurological deterioration, when MRI abnormalities are characteristic for AD and other causes of leukodystrophy have been ruled out.

References

1. Claudia B. Poloni. Alexander disease: Early presence of cerebral MRI criteria. *Eur J Pediatr Neurol* 2009;13(6):556-8.
2. Balbi P. The clinical spectrum of late-onset Alexander disease: a systematic literature review. *J Neurol* 2010; 257(12):1955-62.
3. Murakami N. Novel Deletion Mutation in *GFAP* Gene in an infantile form of Alexander Disease. *Pediatric Neurol* 2008; 38(1):50-2.
4. Sawaishi Y. Review of Alexander disease: Beyond the classical concept of leukodystrophy. *Brain Dev* 2009; 31(7):493-8.
5. Gordon N. Alexander disease. *Eur j pediatr neurolo* 2003; 7(6):395-9.
6. Brenner M. Mutation in *GFAP*, encoding glial fibrillary acidic protein, are associated with Alexander disease. *Nature Genetic* 2001; 27(1): 117-20.
7. Rodríguez D. Infantile Alexander Disease: Spectrum of *GFAP* Mutations and Genotype-phenotype correlation. *Am J. Hum Genet* 2001; 69(5):1134-40.
8. Christine A. Magnetic Resonance Imaging Findings in Alexander Disease. *Pediatric Neurol* 2008; 38(5): 373-4.
9. Jacob J. The clinicopathological spectrum of Rosenthal fibre encephalopathy and Alexander's disease: a case report and review of the literature. *J Neurol Neurosurg Psychiatry* 2003; 74(6):807-10.