

## An Unusual Case of Peters Plus Syndrome with Sexual Ambiguity and Absence of Mutations in the *B3GALTL* Gene

Olfa Siala<sup>1</sup>, PhD; Neila Belguith<sup>2</sup>, MD; Faiza Fakhfakh<sup>1</sup>

1. Laboratoire de Génétique Moléculaire Humaine, Faculté de Médecine de Sfax, Tunisia
2. Laboratoire de Génétique Médicale, EPS Hédi Chaker, Sfax, Tunisia

Received: Nov 09, 2011; Accepted: May 19, 2012; Online Available: Jul 23, 2013

### Abstract

**Background:** Peters Plus syndrome (MIM 261540) is a rare autosomal recessive condition characterized by ocular defects (typically Peters anomaly) and other systemic major/minor abnormalities. Mutations in the *B3GALTL* gene encoding the  $\beta$ -1,3-glucosyltransferase have been found in virtually all patients with typical Peters Plus syndrome.

**Case Presentation:** We report here a female patient with severe manifestations of Peters Plus syndrome including facial dysmorphism and bilateral corneal opacity associated with left renal pyelo-calicial dilatation and sexual ambiguity. Total sequencing of the *B3GALTL* gene revealed no mutation in the patient.

**Conclusion:** To our knowledge, sexual ambiguity has not previously been reported in Peters Plus syndrome so far, and renal malformation is also apparently rare in the syndrome.

*Iranian Journal of Pediatrics, Volume 23 (Number 4), August 2013, Pages: 485-489*

**Key Words:** Peters-Plus Syndrome; B3GALTL Protein, Human; Facial Dysmorphism with Multiple Malformations; Ambiguous Genitalia

### Introduction

The Peters Plus syndrome (PPS) is characterized by anterior chamber eye anomalies, disproportionate short stature, variable developmental delay/intellectual disability, characteristic facial features, and cleft lip/palate. The most common anterior chamber defect is Peters' anomaly consisting of a central corneal opacification, thinning of the posterior cornea, and iridocorneal adhesions. Cataracts and glaucoma are common. Growth deficiency with rhizomelic limb shortening is invariably present<sup>[1]</sup>. PPS is a rare autosomal recessive disorder; so, up to now, only fewer than 70 PPS cases have been reported. It is

related to mutations in the *B3GALTL* gene in the 13q12.3 region with only seven mutations reported in the literature<sup>[2]</sup>. *B3GALTL* mutations lead to the inactivation of the  $\beta$ -1,3-glucosyltransferase involving in the synthesis of a rare disaccharide that occurs on thrombospondin type 1 repeats of many biologically important proteins<sup>[3]</sup>, suggesting that the syndrome is a glycosylation disorder.

We report here a 4 year-old female patient with severe manifestations of PPS including facial dysmorphism and bilateral corneal opacity associated with left renal pyelo-calicial dilatation and sexual ambiguity. Analysis of the *B3GALTL* gene revealed no mutation in the patient.

#### \* Corresponding Author:

Address: Laboratoire de Génétique Moléculaire Humaine. Faculté de Médecine de Sfax. Sfax. Tunisia

E-mail: olfa\_siala@yahoo.fr

© 2013 by Pediatrics Center of Excellence, Children's Medical Center, Tehran University of Medical Sciences, All rights reserved.

To our knowledge, sexual ambiguity has not previously been reported in Peters Plus syndrome so far, and renal malformation is also apparently rare in the syndrome. Our patient represents the first association of PPS with sexual ambiguity and renal malformation.

## Case Presentation

### Atypical Peters Plus syndrome with new associations

The patient presented here is a 4 year-old girl of healthy consanguineous parents. Her younger sister was also healthy. Prenatal echography revealed short limbs. The PPS was evoked at birth and the patient was addressed for facial dimorphisms. Clinical investigations including karyotype, pediatric and ophthalmologic exams were performed after informed consent. At birth, she was underweight 2660 g (-1.6 SD), her length was 46 cm (-1.4 SD), and occipitofrontal circumference (OFC) 34 cm ( $\pm 0$  SD). Apgar score was 8/10. Neonatal exams revealed complete bilateral cleft lip and palate, large anterior fontanel, hypertelorism and a coccygeal dimple suggesting vertebral schisis. She also had disproportionate short stature and facial dysmorphism including dolichocephaly, round face, small nose with reverted nostrils and erased and long philtrum. Short limbs in the proximal segment and brachydactyly with bilateral clinodactyly of the fifth finger were also seen. Transfontanel ultrasound imaging showed quadri ventricular hydrocephaly and microcephaly caused by agenesis and atrophy of corpus callosum. Ophthalmologic exam revealed bilateral central corneal opacity without buphthalmos or congenital glaucoma.

In addition to these typical features for PPS, the patient showed sexual ambiguity without urogenital anomalies. In fact, she had hyperpigmented labia majora with pseudo scrotal aspect without clitoris hypertrophy, but she had two distinct (urethral and vaginal) orifices. Abdomen ultrasound showed a morphologically normal uterus with normal size, but renal pyelocalicial dilation on left side was appreciated. Chromosome analysis on lymphocytes revealed a

normal 46, XX karyotype. At the age of 4 years, the patient's weight was 11 kg (-2SD), length 78 cm (-3SD) and OFC 47 cm; without delayed psychomotor development.

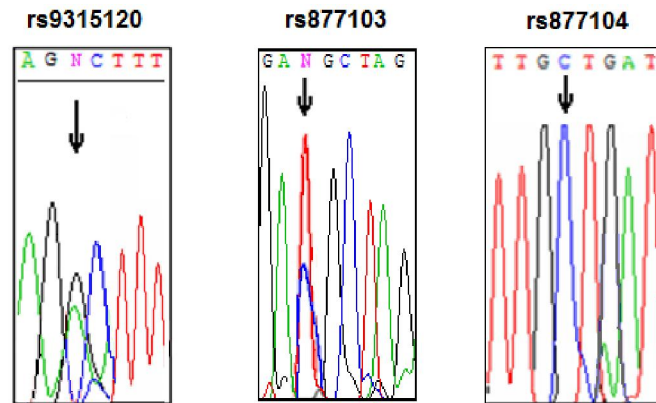
### Absence of mutations in the *B3GALTL* gene

*B3GALTL* is the only gene known to be associated with Peters Plus syndrome, and most affected individuals tested to date are homozygous for a hot spot splice mutation in the acceptor splice site of intron 8 (c.660+1G>A). Sequencing of the 15 coding exons and flanking introns boundaries of the *B3GALTL* gene showed that the patient is *B3GALTL* mutation-negative. But we cannot exclude the presence of splice site mutation distant from the coding sequence, or mutation in the regulatory sequences of the gene. In addition, screening of the three intragenic SNP(s) which are described to be associated with *B3GALTL* gene mutations showed that the patient is heterozygous for two SNP (rs9315120, rs877103) and homozygous for the rs877104 one (Fig. 1). These results suggest but not confirm the exclusion of the *B3GALTL* gene in this case (Table 1).

## Discussion

We present here an unusual case of PPS who associates sexual ambiguity and renal malformation with typical phenotype of the syndrome. It is noteworthy that mutations in the *B3GALTL* gene in the 13q12.3 region were found in all PPS patients with the predominant constant c.660+1G>A mutation in intron 8<sup>[3]</sup>. Our previous studies also demonstrated the occurrence of a novel c.597-2A>G mutation in two unrelated Tunisian patients with typical PPS<sup>[2]</sup>. These patients are homozygous for three intragenic SNPs described to be associated with *B3GALTL* mutations. In the present case, no mutation in the *B3GALTL* gene was found. Furthermore, results showed that the patient is heterozygous for two of the mentioned SNPs, suggesting an exclusion of the *B3GALTL* gene, and its implication in 100% of typical PPS cases.

PPS is a rare disorder that overlaps phenotypic heterogeneity. The main clinical features include unilateral or bilateral corneal opacity, facial



**Fig. 1:** Electrophoregrams showing that the patient is heterozygous for the rs9315120 and the rs877103 SNPs and homozygous for the rs877104 SNP

dysmorphism, short stature and limbs, and mental delay. PPS was found to be associated with congenital hypoplastic left heart<sup>[4]</sup>, absence of right pulmonary artery and vein<sup>[5]</sup>, and absence of kidney<sup>[6]</sup>. However, no molecular studies were performed to search the responsible molecular defect in the *B3GALTL* gene or in other candidate genes in these potential PPS cases. Therefore, the etiology of other conditions associated with Peters Plus anomaly remains unknown. Taking these findings together, the search of the causal gene with further researches including the exome sequencing seems to be interesting in this unusual PPS case.

Genitourinary abnormalities including hydronephrosis, renal and ureteral duplication,

renal hypoplasia and oligomeganephroma, multicystic dysplastic kidney are the most frequently observed phenotype in PPS, reported in about 10–19% of patients suffering from PPS. Genitourinary anomalies include hydronephrosis, renal and ureteral duplication, renal hypoplasia and oligomeganephroma, multicystic dysplastic kidney and glomerulocystic kidneys<sup>[3]</sup>. This can be related to the fact that embryogenetical stages of eye and kidney development occur simultaneously. From 7th to 10th week of the fetal life, the development of ocular architecture progresses parallel with the differentiation of kidney tubules. Moreover, a variety of human congenital syndromes affecting both organs have been described such as the Nail Patella

**Table 1:** Sequence of the primers required for the amplification of the *B3GALTL* gene

Exon	Forward primer	Reverse primer	PCR size product
1	5'GCAGAGGAGAAAAGGAAGAGGAG3'	5'GGACCCAAGACCGAAAAGG3'	674 bp
2	5'GCAAACTGTTGGATGTGAGAA3'	5'CAAATGAATCTTAGAAGGGAGGAA3'	176 bp
3	5'TCAGTGTACTGCTGGCTTTGTTA3'	5'GGCCAAAGACAGAATATTTGAA3'	237 bp
4	5'TTTTGTAAAAAGAAATACCTGAAAAC3'	5'TGGAAAACATCAAGGTAATCAAGA3'	217 bp
5	5'TTTCGGAGTAGTCAATTCATACTTATC3	5'GGGCGTAAAAGTGTTCAGGTAG3'	187 bp
6	5'CCCTTCATTCACTTCCTACTGA3'	5'GAAACTGTCCCCAAAATAA3'	249 bp
7	5'TGAAATGATTGTTTTTAAAGTGACA3'	5'CAATGAAATTAAAGTTGATGCACAC3'	246 bp
8	5'TCTTGCTTGACACTTCTTTGG3'	5'AAAATGCAAGATTAGGGAATGC3'	212 bp
9	5'AAAATGCAAGATTAGGGAATGC3'	5'GGATGACATTATGCACAGCATC3'	225 bp
10	5'GAGCGTGTGAGATCTAGTGTGG3'	5'GGTAGTCTGGATTTTAGCGTTCA3'	196 bp
11	5'TGTGTAACGTGCCAGTGATTG3'	5'CAGAATGGCAATGTTTAATAAGGA3'	204 bp
12	5'CACTTCAAAAATAAAAAGAAATGAACA3'	5'AAAGCCATTTAGGATGAGAATGA3'	216 bp
13	5'CTGTTCCATAACCACGTTTAAA3'	5'TCGTGTGAAAAGGGAAGTTTAT3'	239 bp
14	5'GTGGAGCTTCTAACCCTTT3'	5'AGAAGAATCTGTCCCTCACCTG3'	242 bp
15	5'TGAAATGATTGTTTTTAAAGTGACA3'	5'CAATGAAATTAAAGTTGATGCACAC3'	246 bp

syndrome<sup>[7]</sup> and the East syndrome<sup>[8]</sup>.

Sexual ambiguity does not belong to genitourinary abnormalities. However, in anatomy, the genitourinary system is the organ system of the reproductive organs and the urinary system (Dorland's Medical Dictionary). These are grouped together because of their proximity to each other, and essentially because of their common embryological origin. In fact, the permanent organs of the adult are preceded by a set of structures that are purely embryonic, and these embryonic structures are on either side: the pronephros, the mesonephros and the metanephros of the kidney, and the Wolffian and Müllerian ducts of the sex organ.

The simultaneous embryologic development of sex organs, eye and kidney can explain in this case the association of sexual ambiguity and renal malformation with the bilateral eye involvement in our patient.

## Conclusion

Our data suggests that other causal effects may be the cause of Peters Plus pathogenicity. The absence of mutations within the coding regions of the B3GALTL gene in this unusual case of PPS lead us to search the causal gene using further researches including the exome sequencing.

## Acknowledgements

We thank the patient's family for the cooperation to perform the present study. This work was supported by the Ministry of Higher Education, Scientific Research and Technology in Tunisia.

## References

1. Van Schooneveld MJ, Delleman JW, Beemer FA, et al. Peters'-plus: a new syndrome. *Ophthalmic Paediatr Genet* 1984;4(3):141-5.
2. Siala O, Belguith N, Kammoun H, et al. Two Tunisian patients with Peters plus syndrome harbouring a novel splice site mutation in the B3GALTL gene that modulates the mRNA secondary structure. *Gene* 2012;507(1):68-73.
3. Oberstein SA, Kriek M, White SJ, et al. Peters Plus syndrome is caused by mutations in B3GALTL, a putative glycosyltransferase. *Am J Hum Genet* 2006; 79(3):562-6.
4. Shimizu R, Saito R, Hoshino K, et al. Severe Peters Plus syndrome-like phenotype with anterior eye staphyloma and hypoplastic left heart syndrome: proposal of a new syndrome. *Congenit Anom* 2010; 50(3):197-9.
5. Hanna NN, Eickholt K, Agamanolis D, et al. Atypical Peters plus syndrome with new associations. *J AAPOS* 2010;14(2):181-3.
6. Tuli N, Kumar S, Sood S. Peters plus syndrome and absence of kidney: a case report. *Cases J* 2009;2(1): 2.
7. Warkany J. Congenital Malformations. Notes and Comments. Chicago, Year Book Medical Publishers; 1975; P: 490.
8. Hou X, Hagemann N, Schoebel S, et al. A structural basis for Lowe syndrome caused by mutations in the Rab-binding domain of OCRL1. *EMBO J* 2011;30(8): 1659-70.